

V·S·T

Case Studies



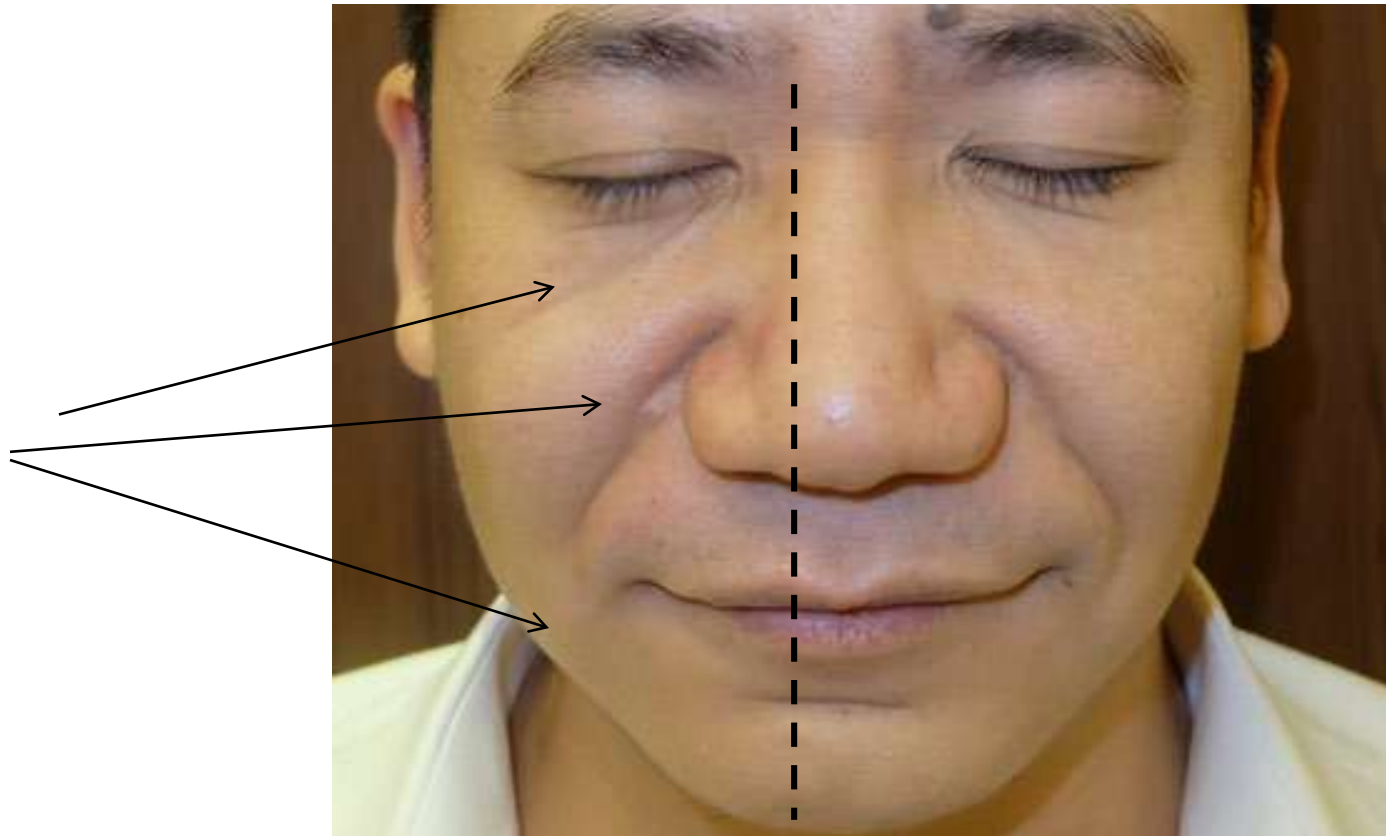
Full face


VIORA



Eye bags & nasolabial folds

Case Study – VST#019	Viora Ltd., China
Patient	Male, 39 years old
Number of Treatments	1 V-ST (60-70 J/cm³, Mode III)



Untreated

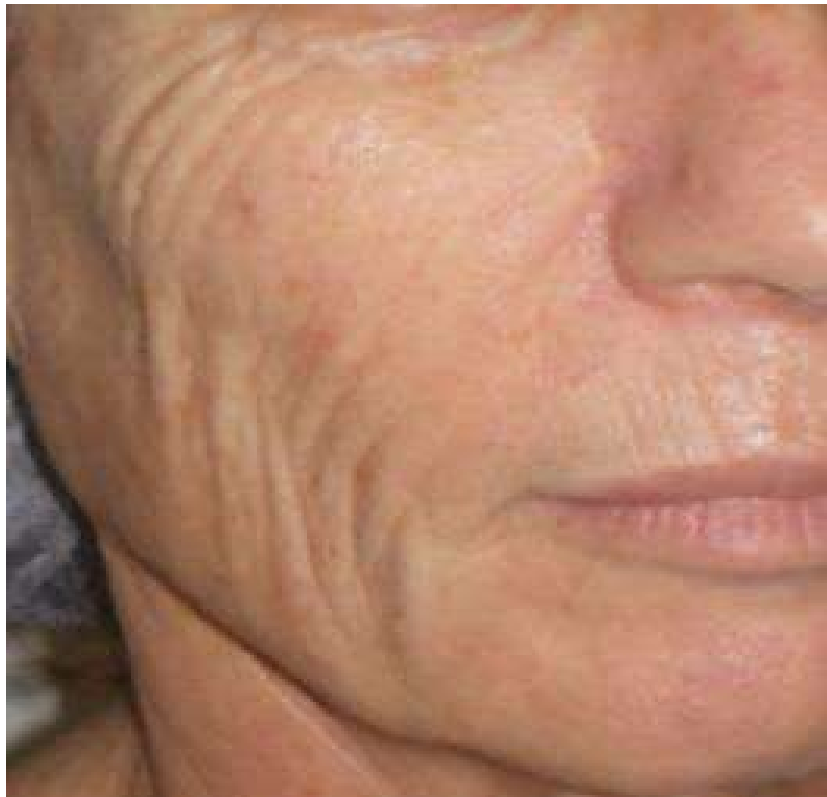Treated



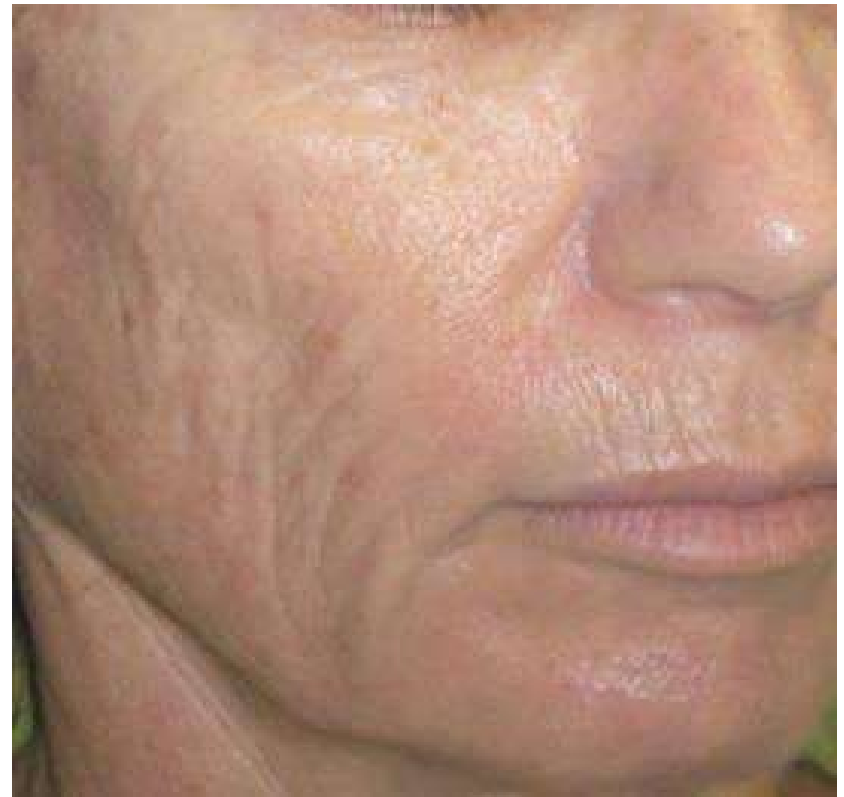

Lower Face

Case Study – RE#120	Ronit Sade, Israel
Patient	Female, 55 years old
Number of Treatments	2 V-ST



Before

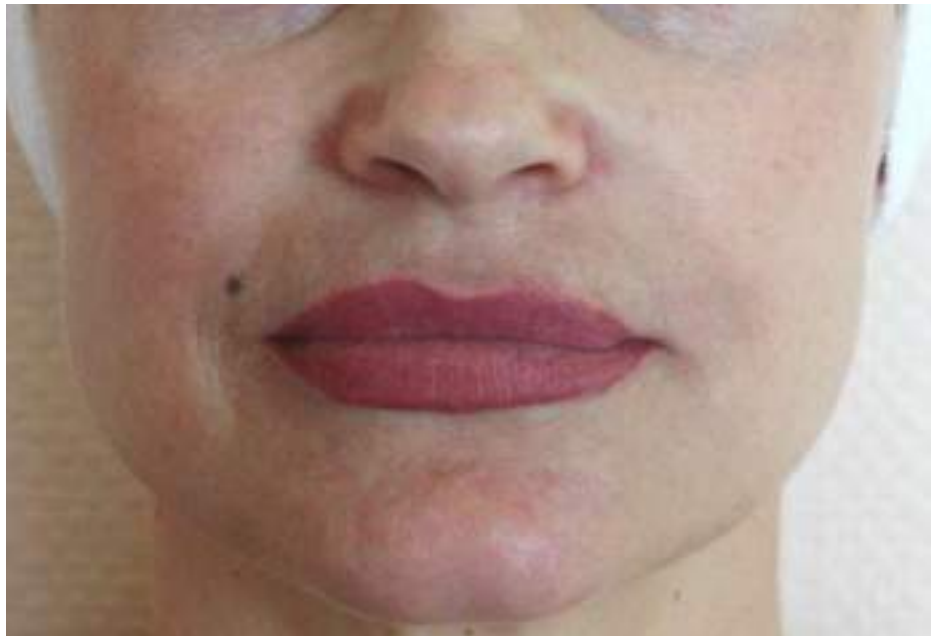

After

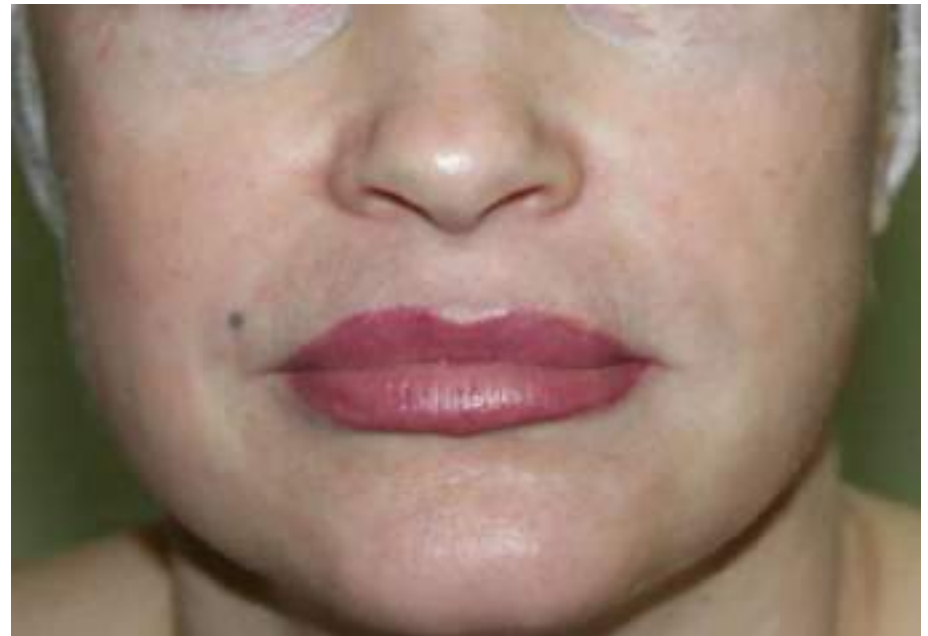

Lower Face

Case Study – RE #180-B	Dr. Marina Vashkevich, Grodno, Belarus
Patient	Female, 42 years old
Number of Treatments	5 V-ST



Before

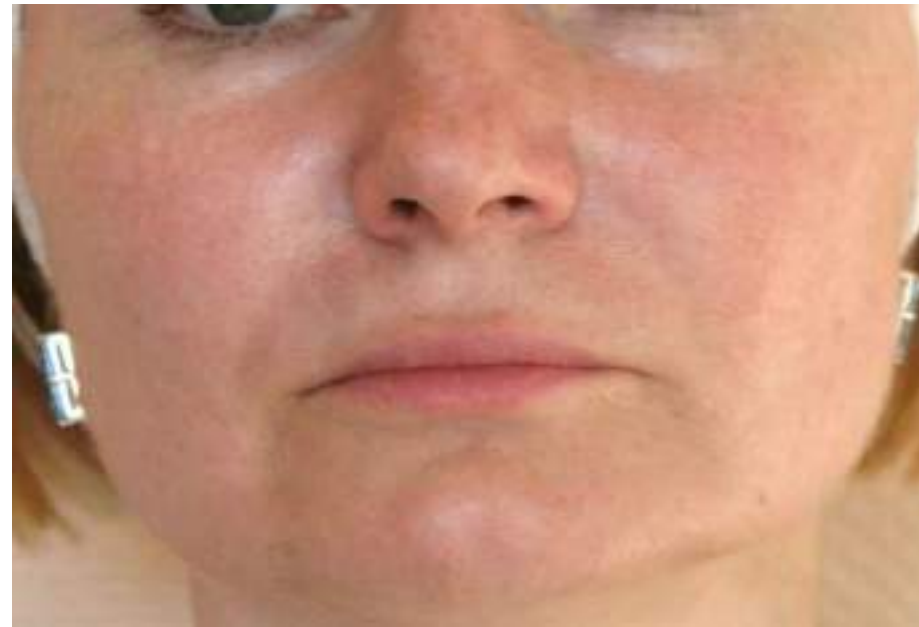
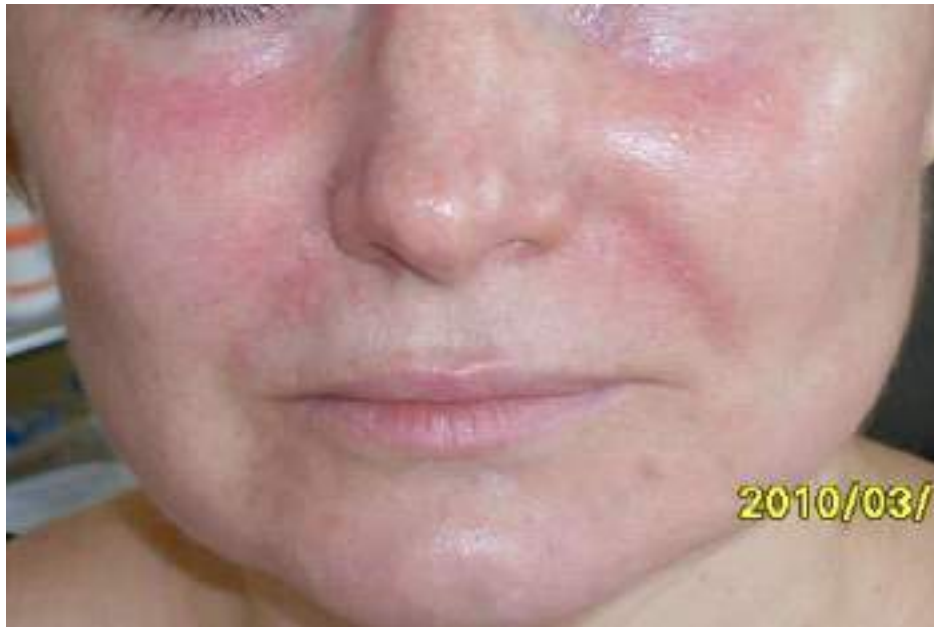
After



Lower Face

Case Study – RE #182	Dr. Marina Vashkevich, Grodno, Belarus
Patient	Female, 42 years old
Number of Treatments	4 V-ST



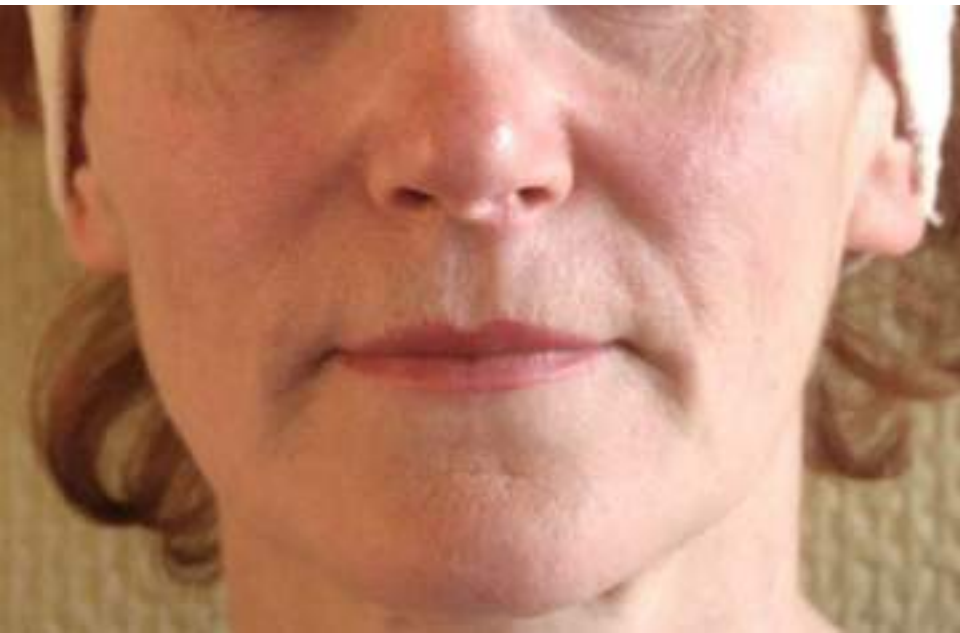Before

After

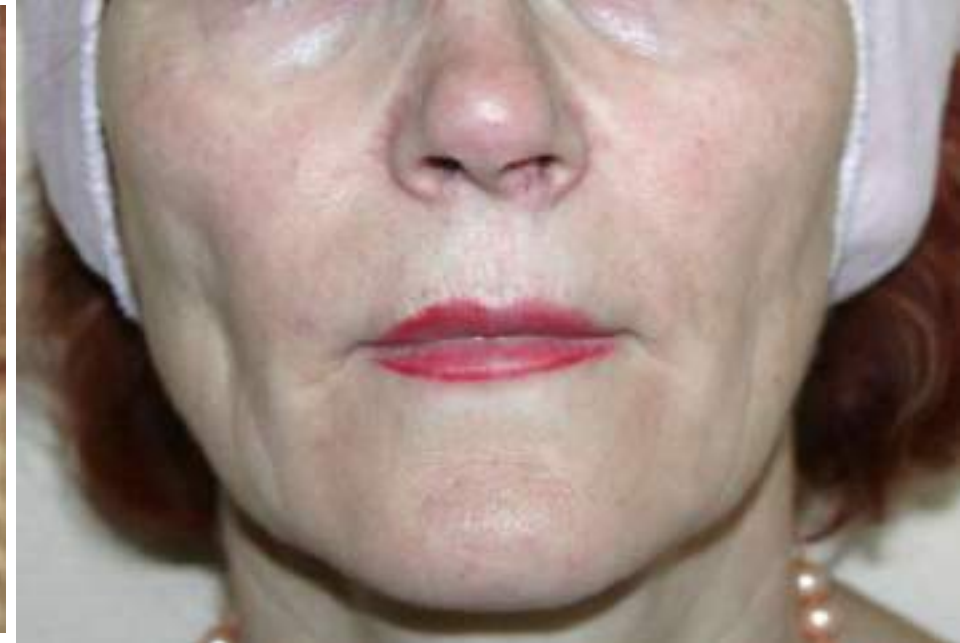

Face

Case Study – RE #186-A	Dr. Marina Vashkevich, Grodno, Belarus
Patient	Female, 42 years old
Number of Treatments	4 V-ST



Before

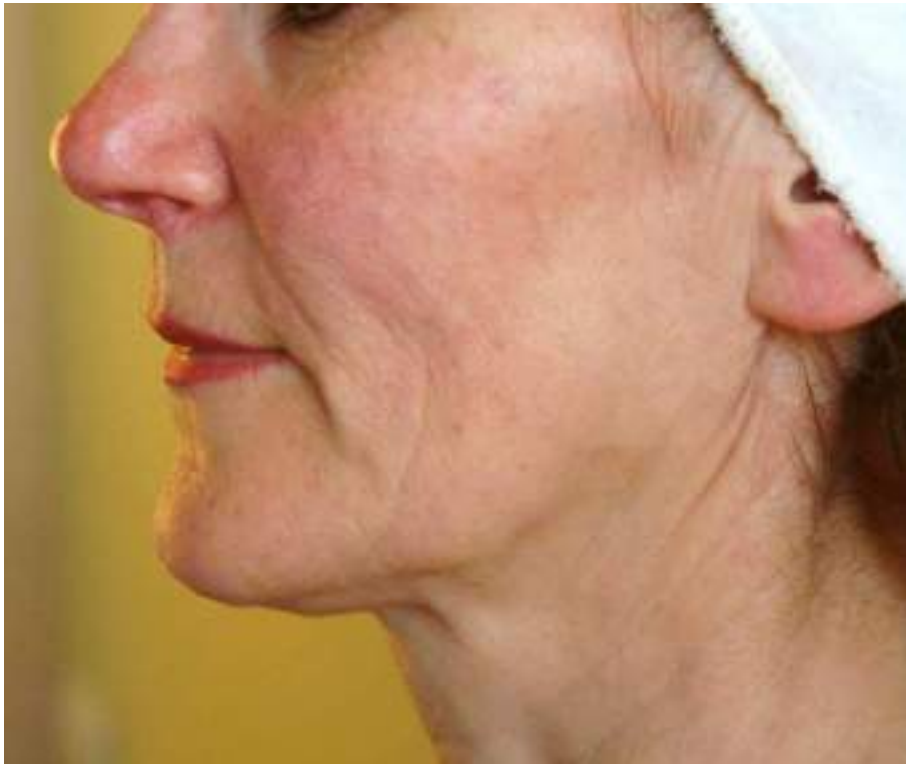

3 Months Follow-up

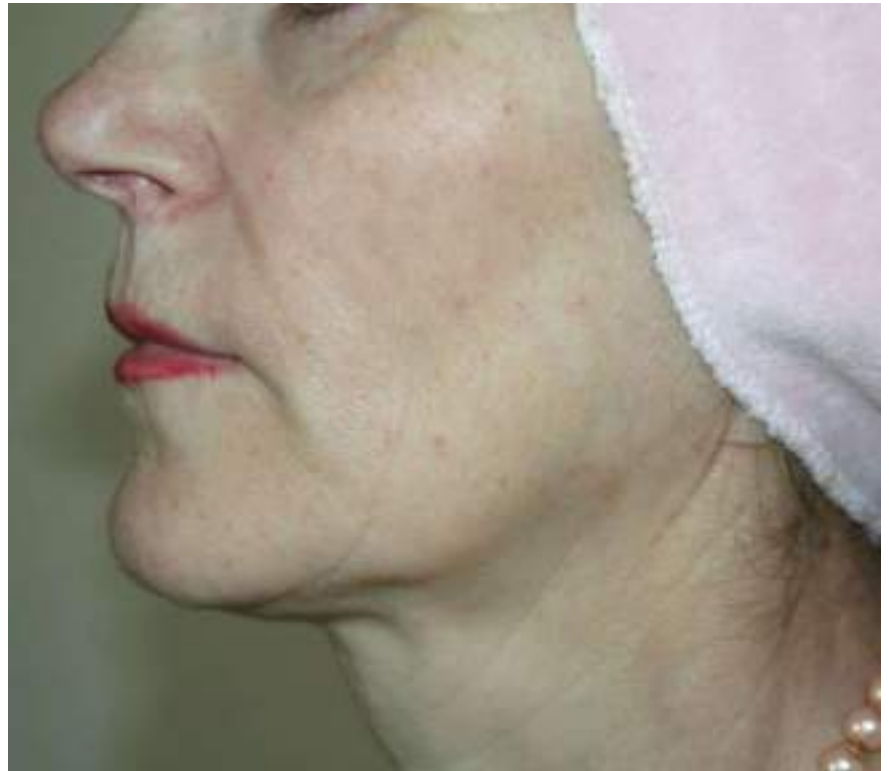

Face

Case Study – RE #186-B	Dr. Marina Vashkevich, Grodno, Belarus
Patient	Female, 42 years old
Number of Treatments	4 V-ST



Before

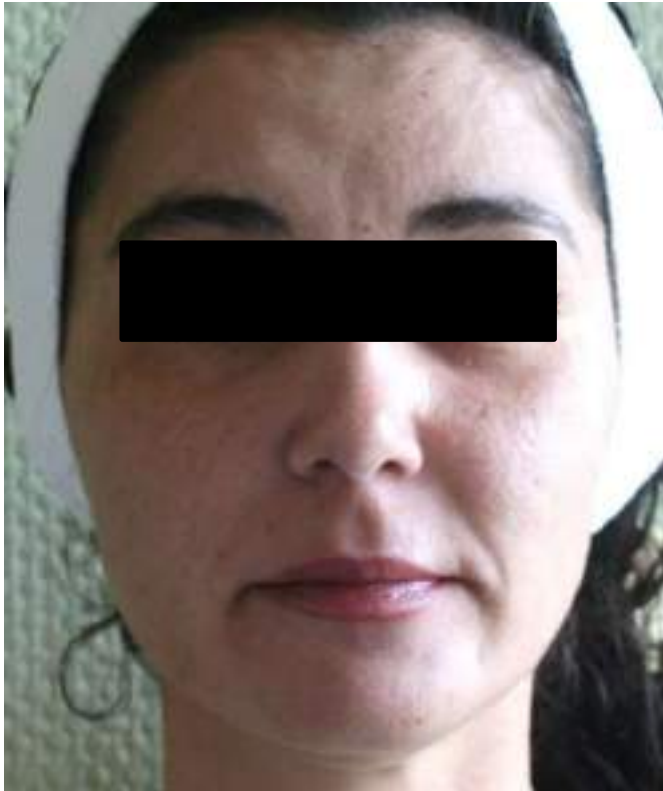

3 Months Follow-up

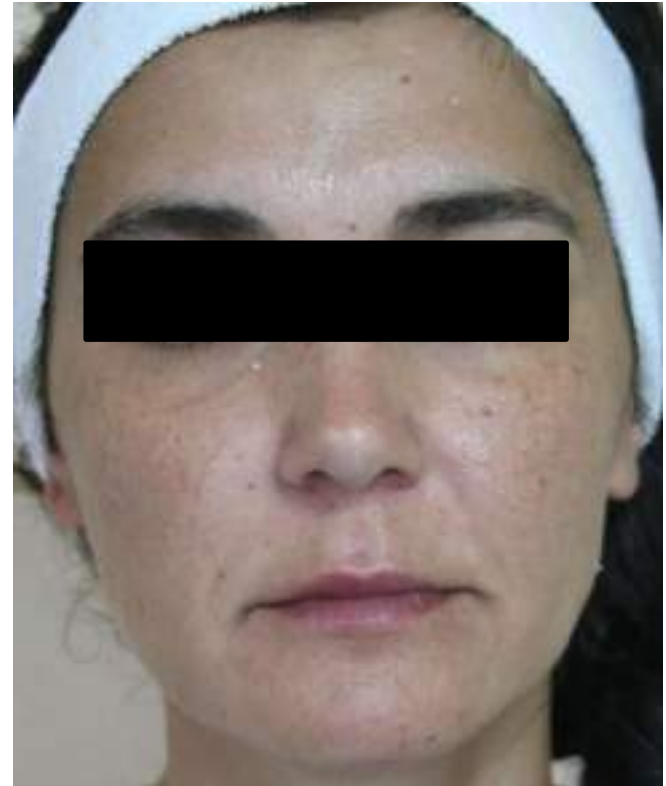

Face

Case Study – RE #189	Dr. Marina Vashkevich, Grodno, Belarus
Patient	Female
Number of Treatments	3 V-ST



Before

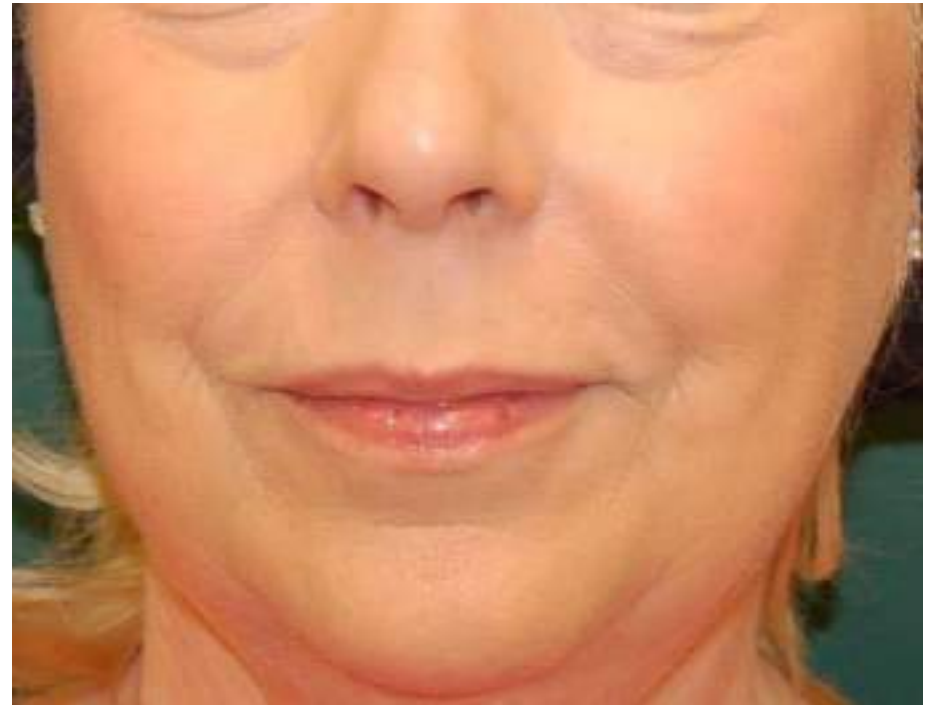
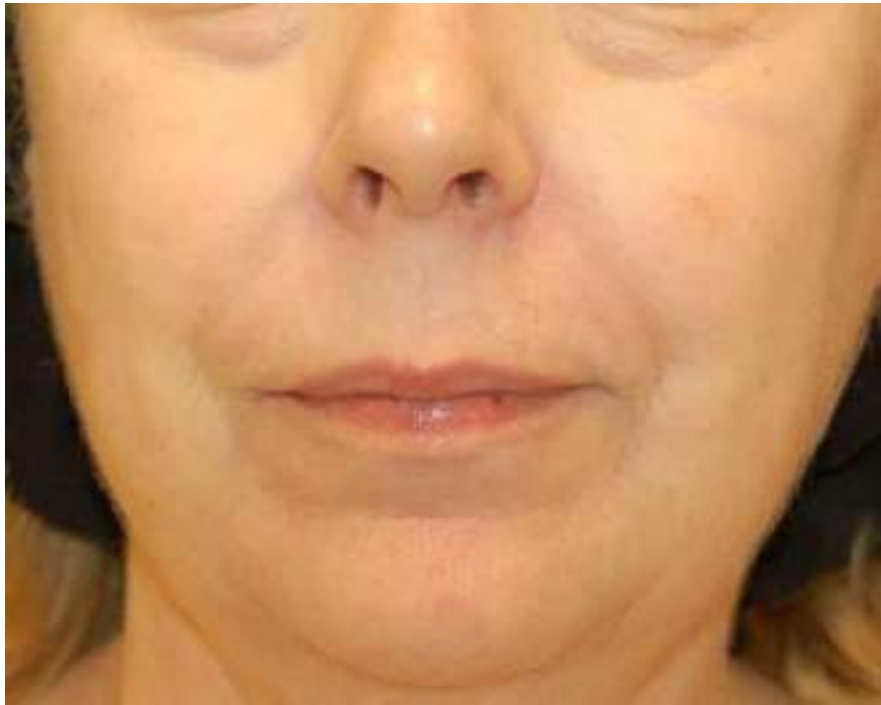
After



Face

Case Study – RE#272	Dr. Roger Emory, Abingdon, VA, U.S.A
Patient	Female
Number of Treatments	4 V-ST



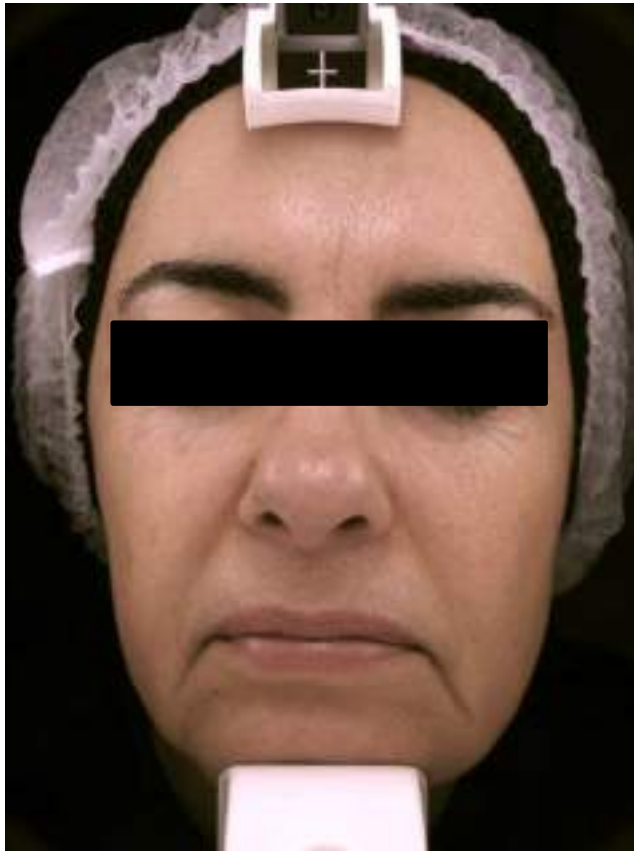Before

After

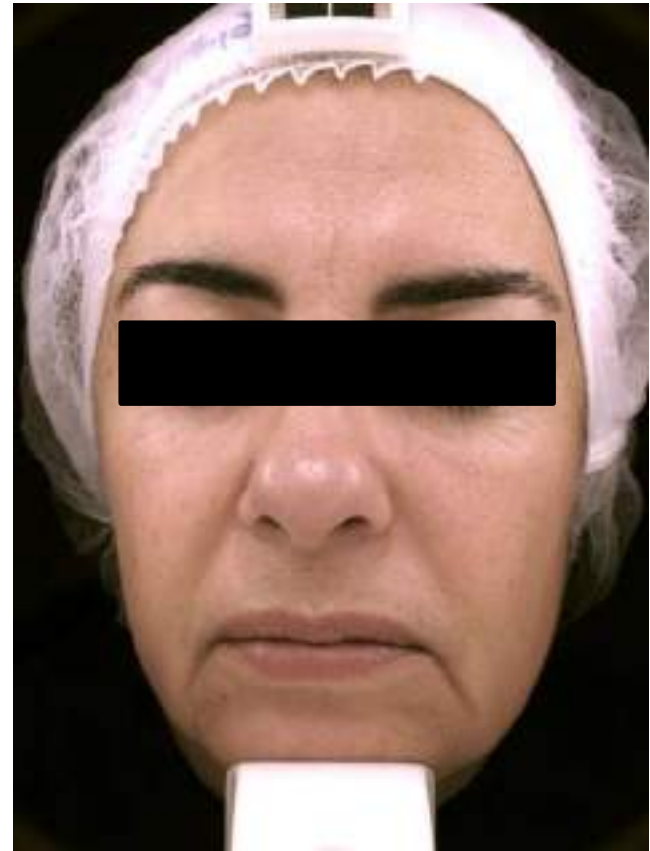

Face

Case Study – RE#227	Dr. Valeria Campos, Brazil
Patient	Female
Number of Treatments	1 V-ST



Before

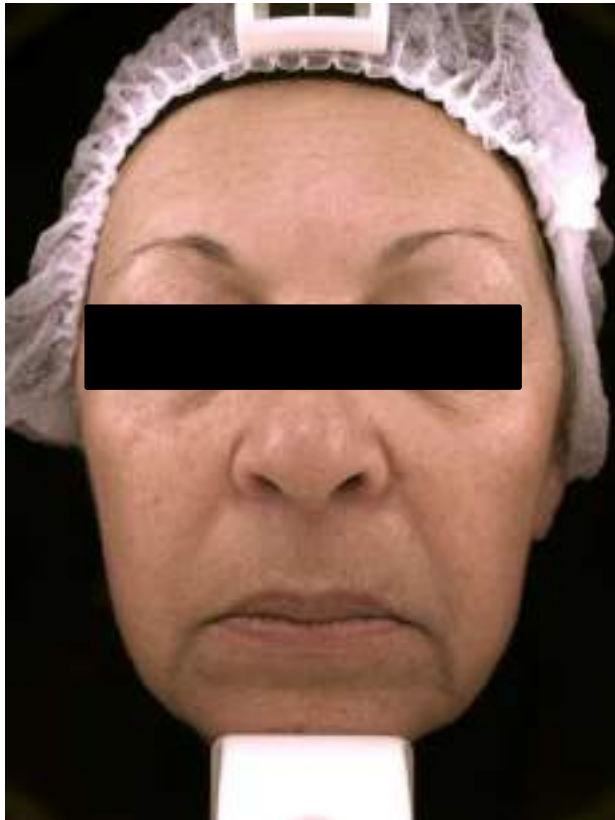

After

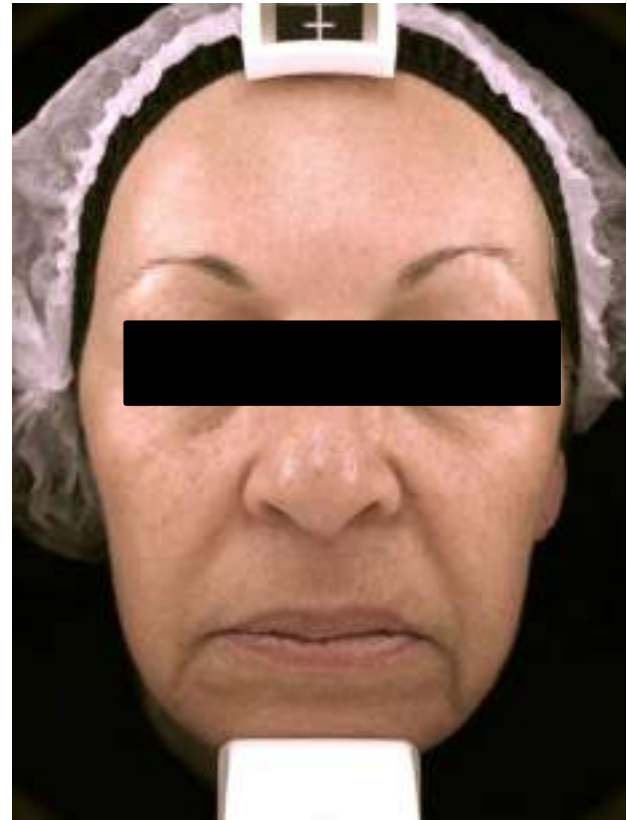

Face

Case Study – RE#228	Dr. Valeria Campos, Brazil
Patient	Female
Number of Treatments	1 V-ST



Before

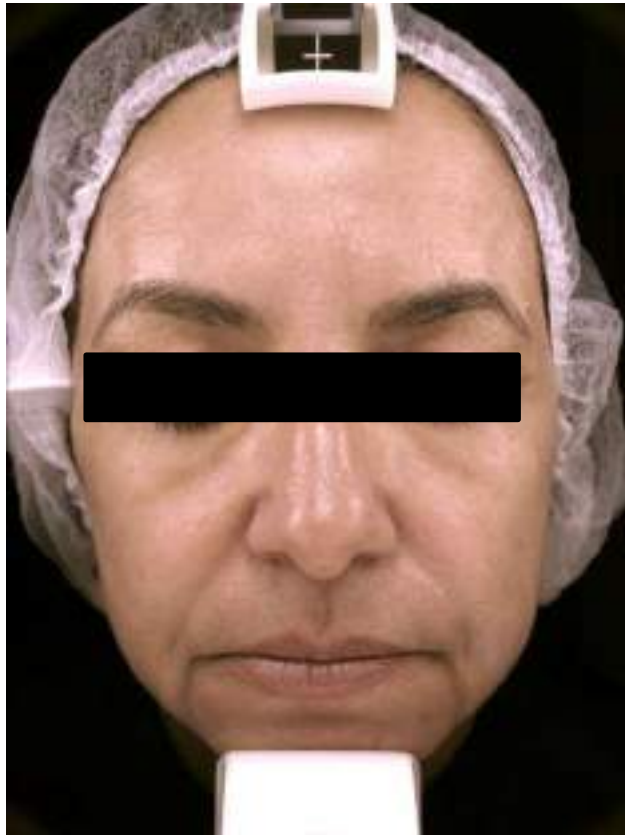

After

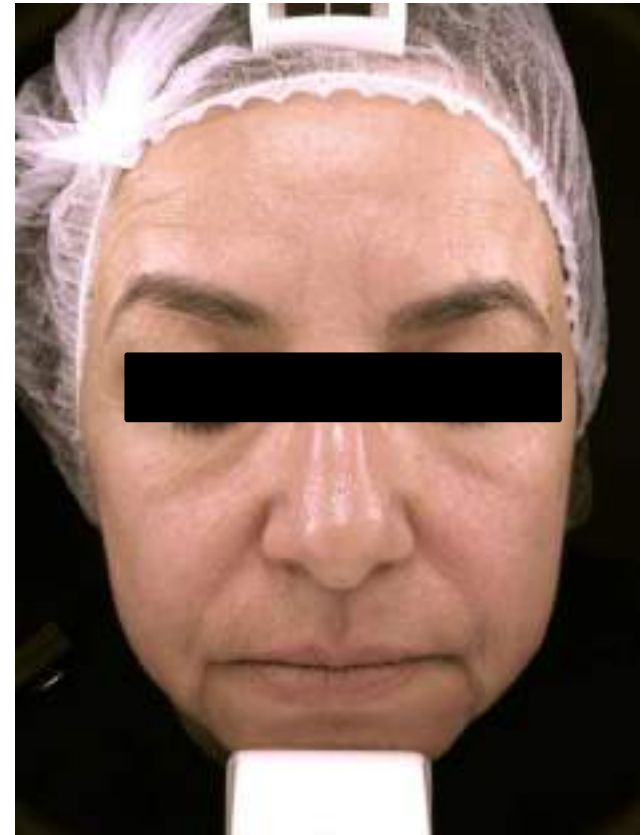

Face

Case Study – RE#229	Dr. Valeria Campos, Brazil
Patient	Female
Number of Treatments	1 V-ST



Before



After



Face

Case Study – RE #176-B

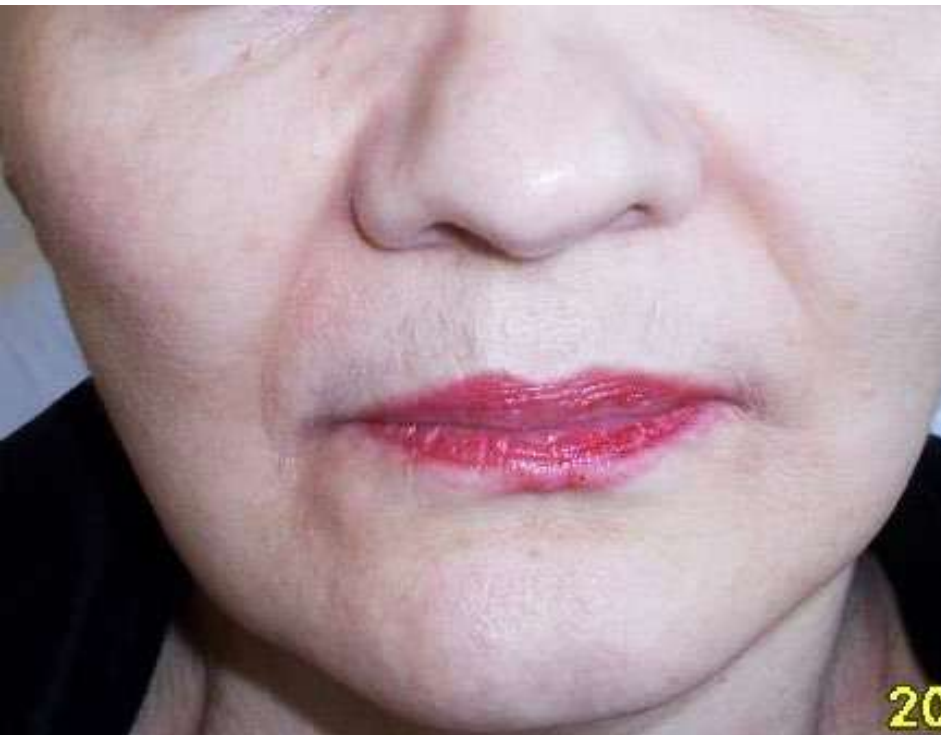Dr. Marina Vashkevich, Grodno, Belarus

Patient

Female, 58 years old

Number of Treatments

3 V-ST



Before



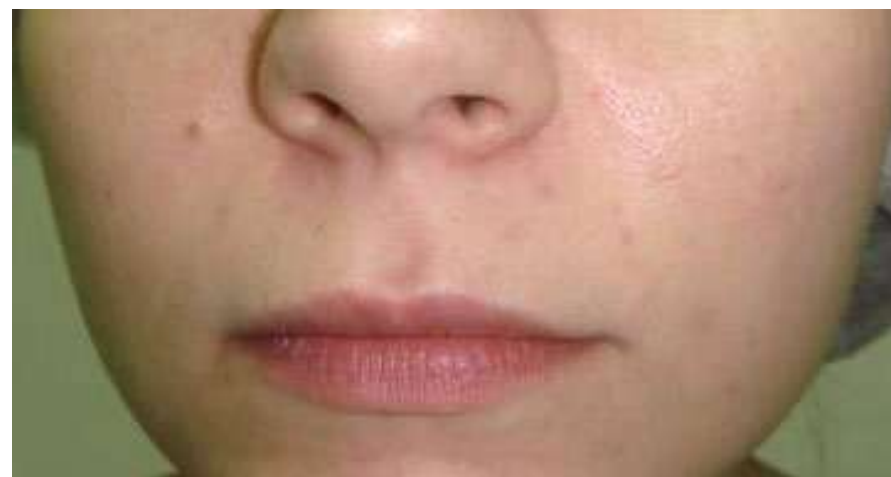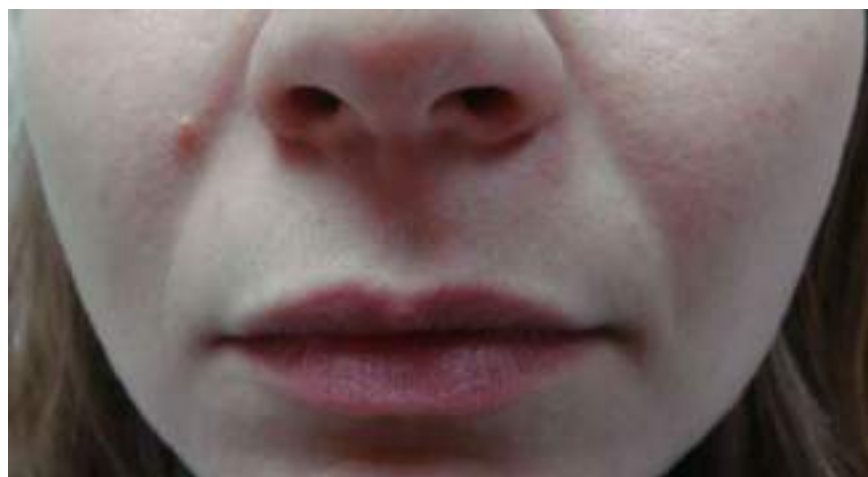6 Months Follow-up





Face - Nasolabials

Case Study – RE #121	Viora Ltd.
Patient	Female, 26 years old
Number of Treatments	2 V-ST



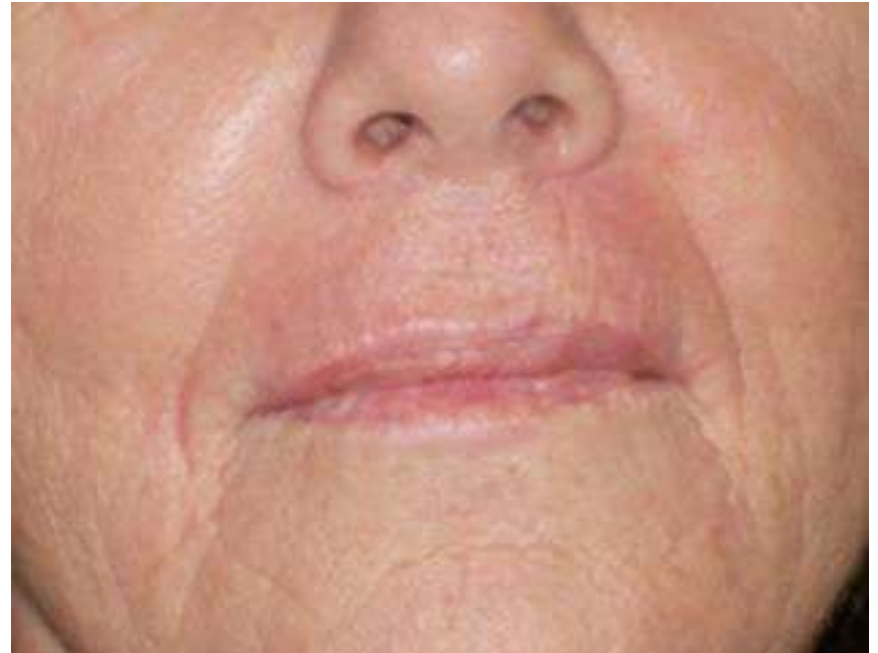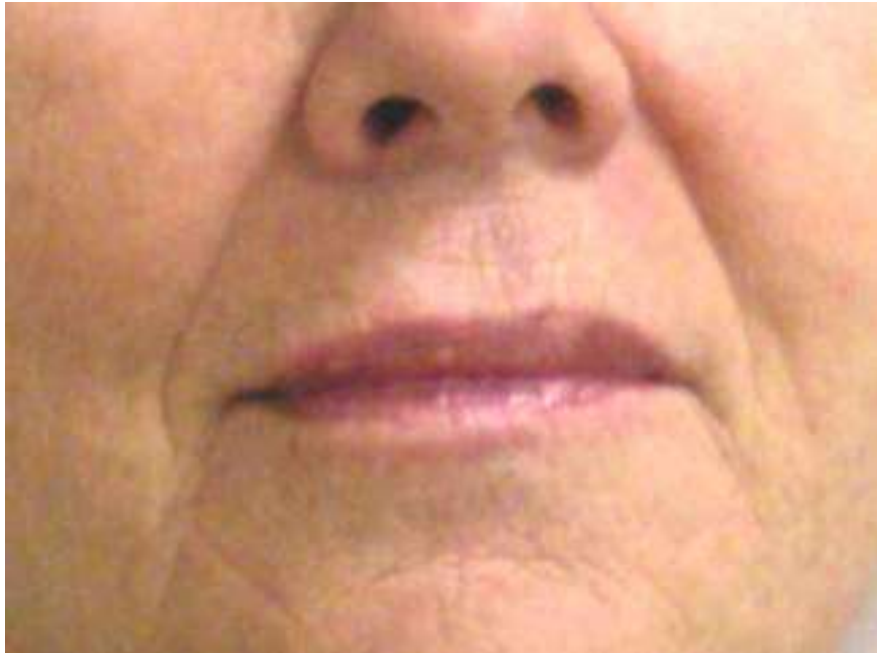Before

After



Peri Oral

Case Study – RE #123	Ronit Sade, Israel
Patient	Female, 50 years old
Number of Treatments	3 V-ST



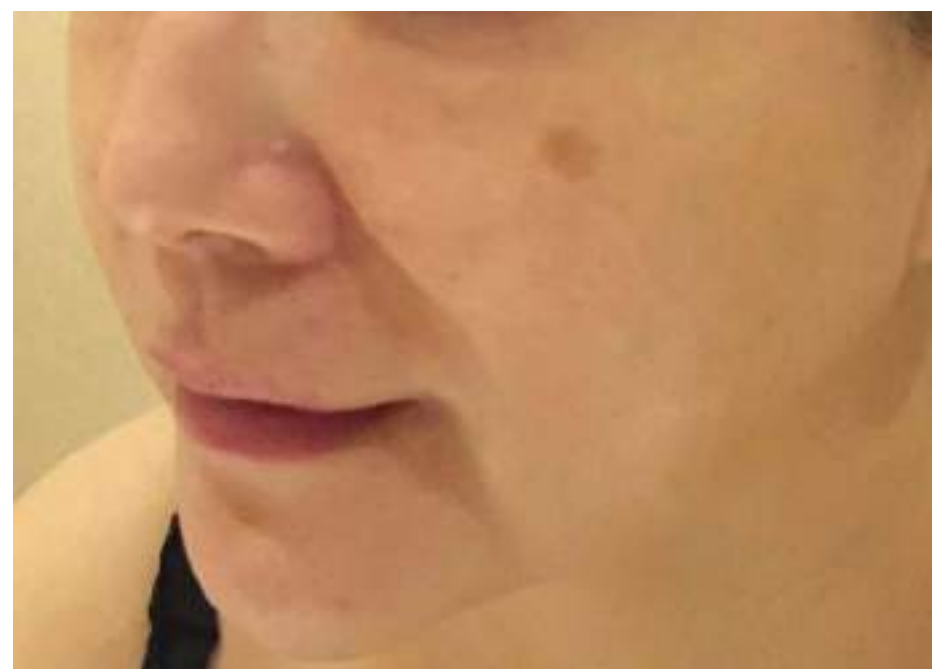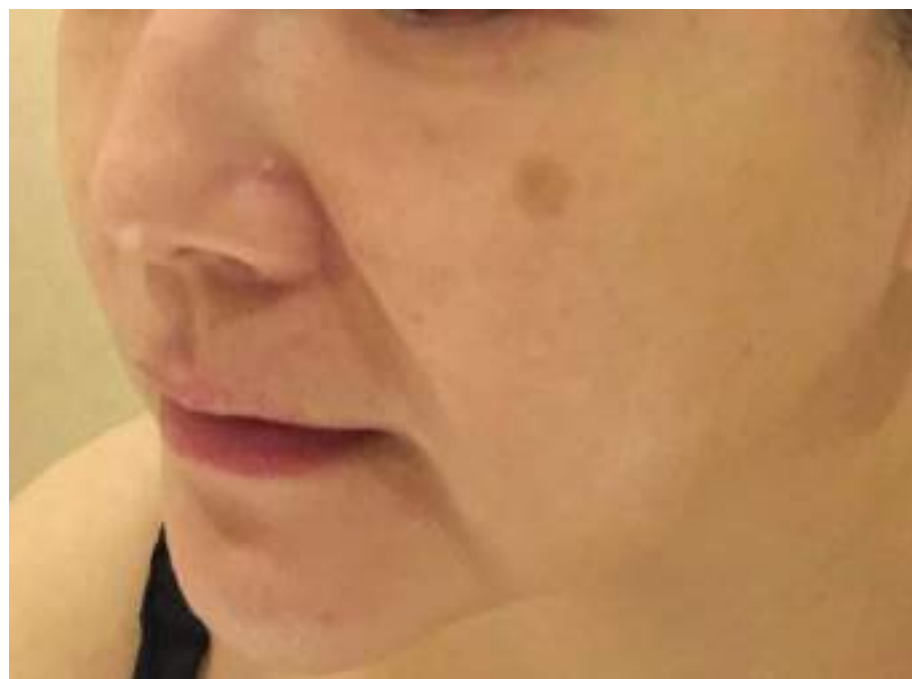Before

After



Nasolabial folds

Case Study – VST#016	Viora Ltd., China
Patient	Female, 50 years old
Number of Treatments	1 - V-ST (62-84 J/cm³, Mode I, II & III)



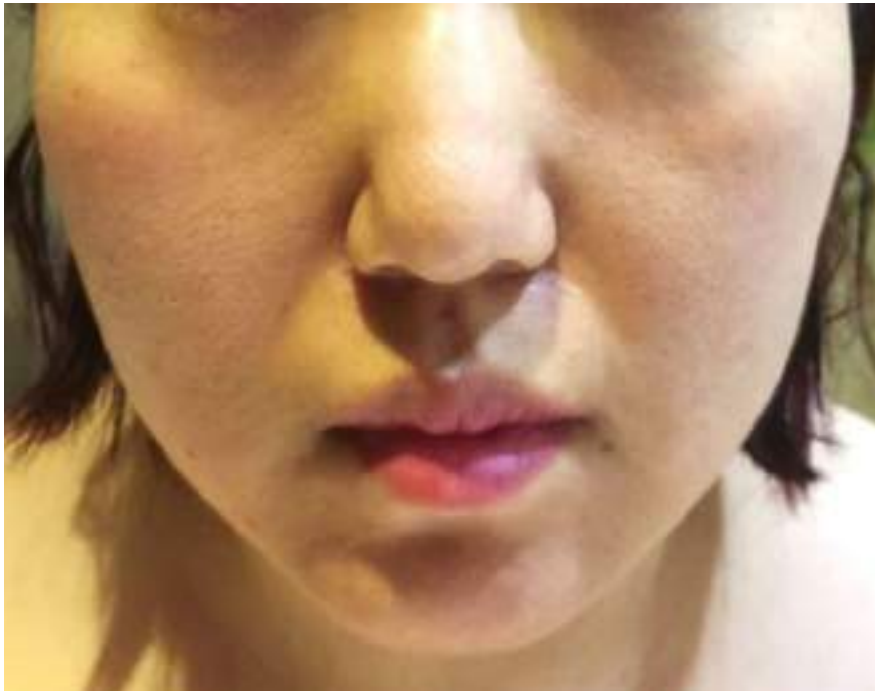Before

After

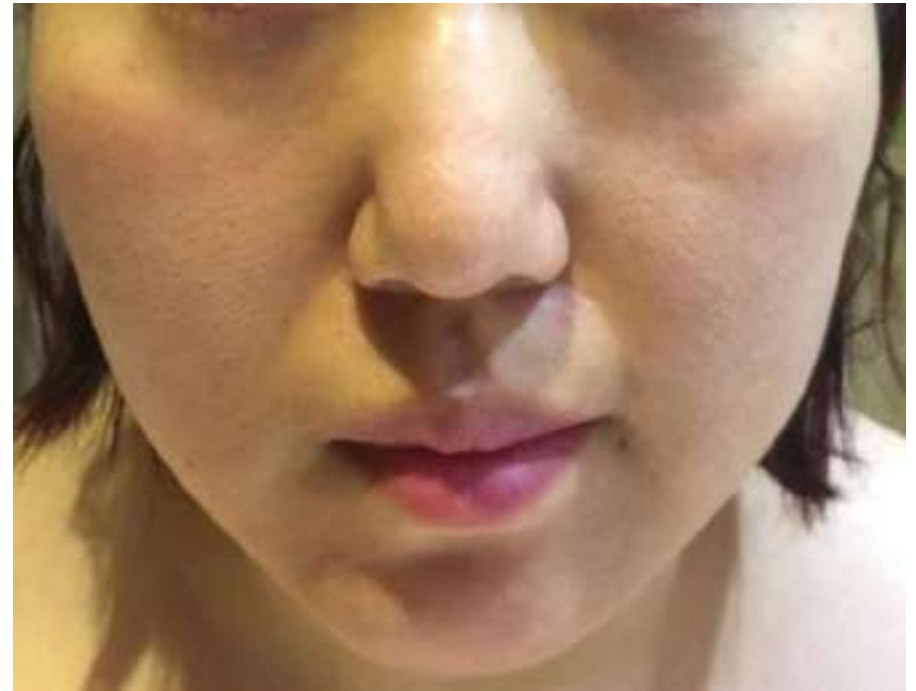

Nasolabial folds

Case Study – VST#017	Viora Ltd., China
Patient	Female, 34 years old
Number of Treatments	1 - V-ST (58-70 J/cm³, Mode I, II & III)



Before

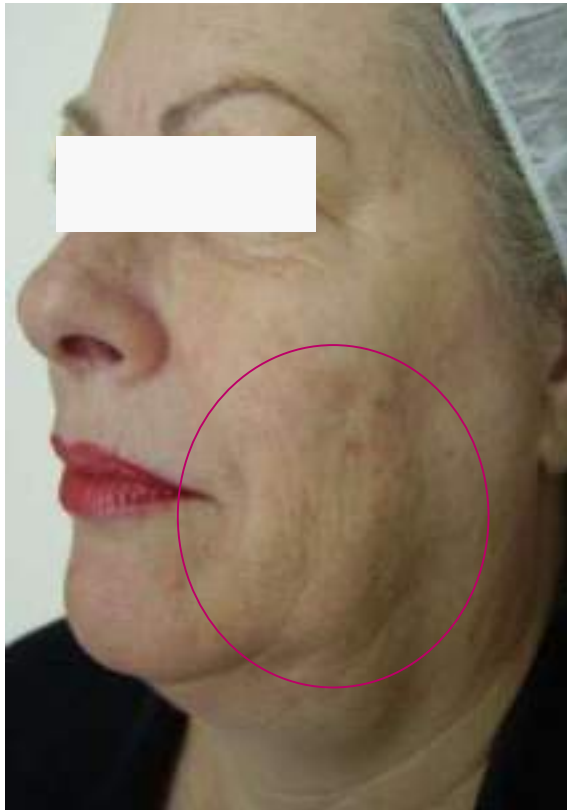

After

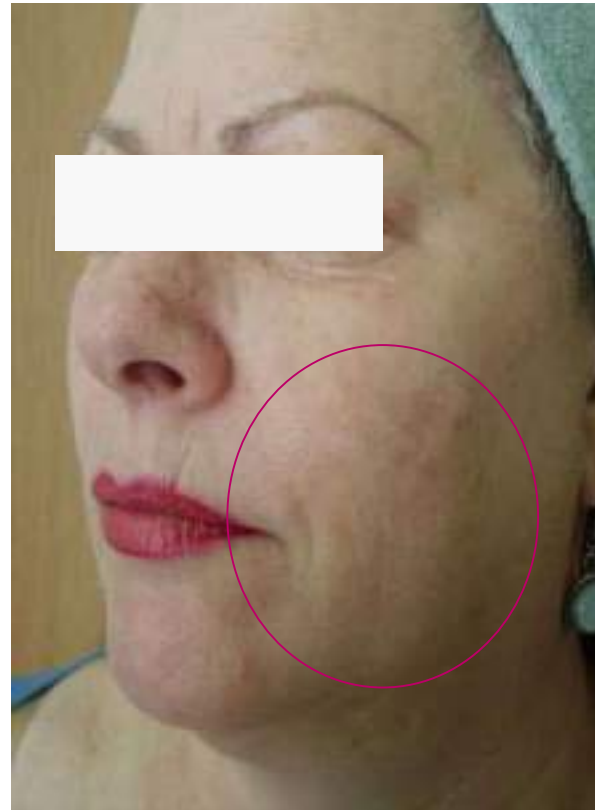

Face

Case Study – RE #207	Keren Or Medical Aesthetic Center
Patient	Female
Number of Treatments	7 V-ST



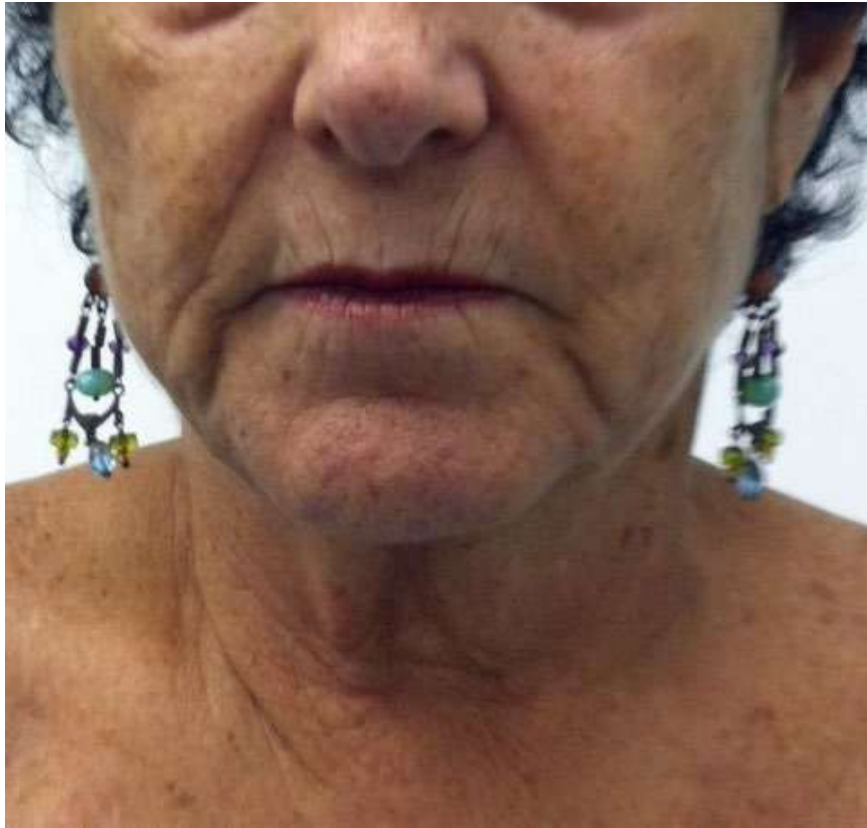Before



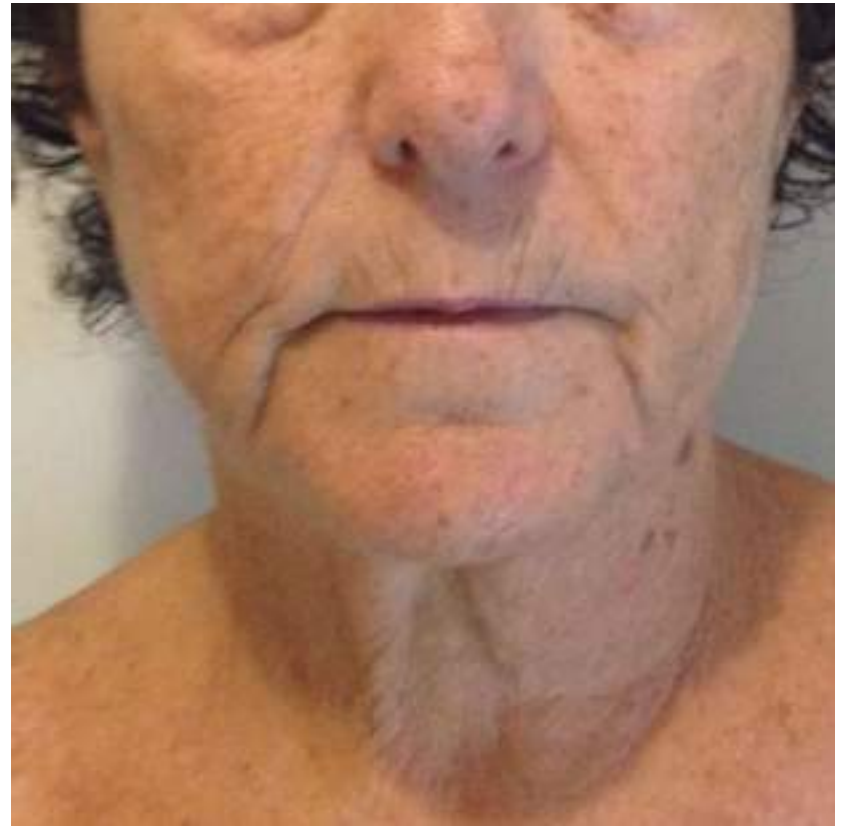After

Face

Case Study – RE#303-A	Viora Inc., USA
Patient	Female, 60 years old
Number of Treatments	3 V-ST



Before

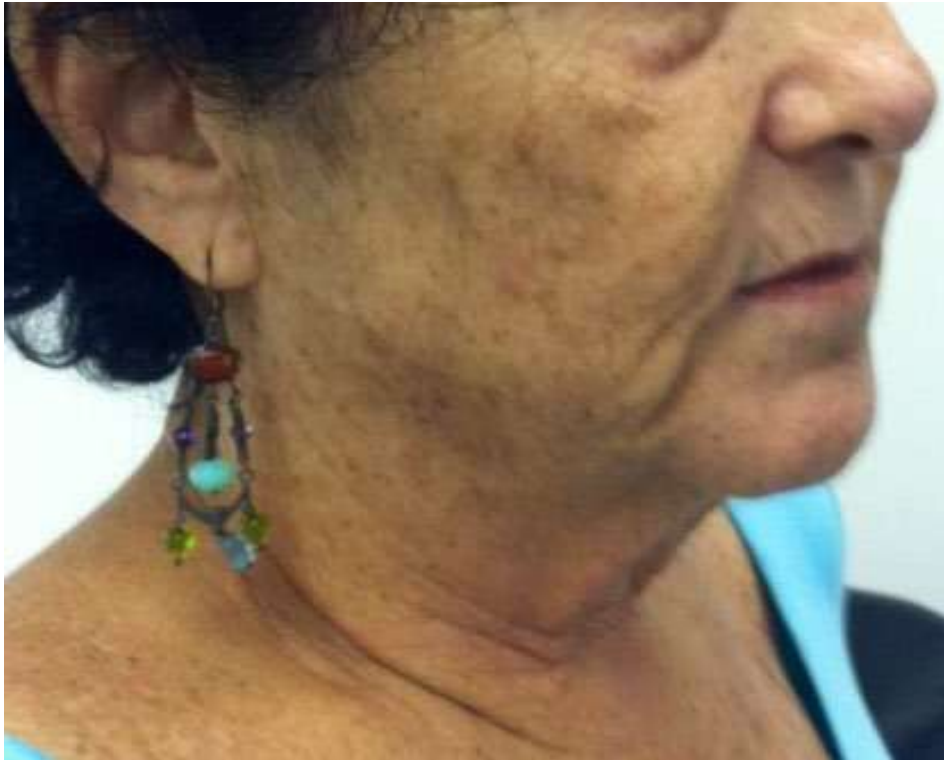

After

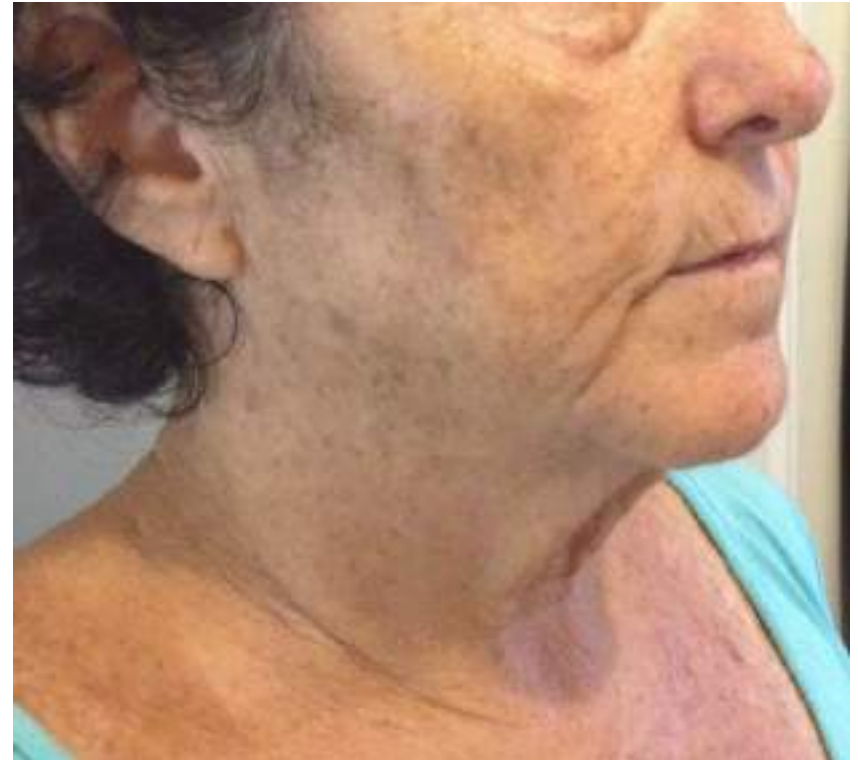

Face

Case Study – RE#303-B	Viora Inc., USA
Patient	Female, 60 years old
Number of Treatments	3 V-ST



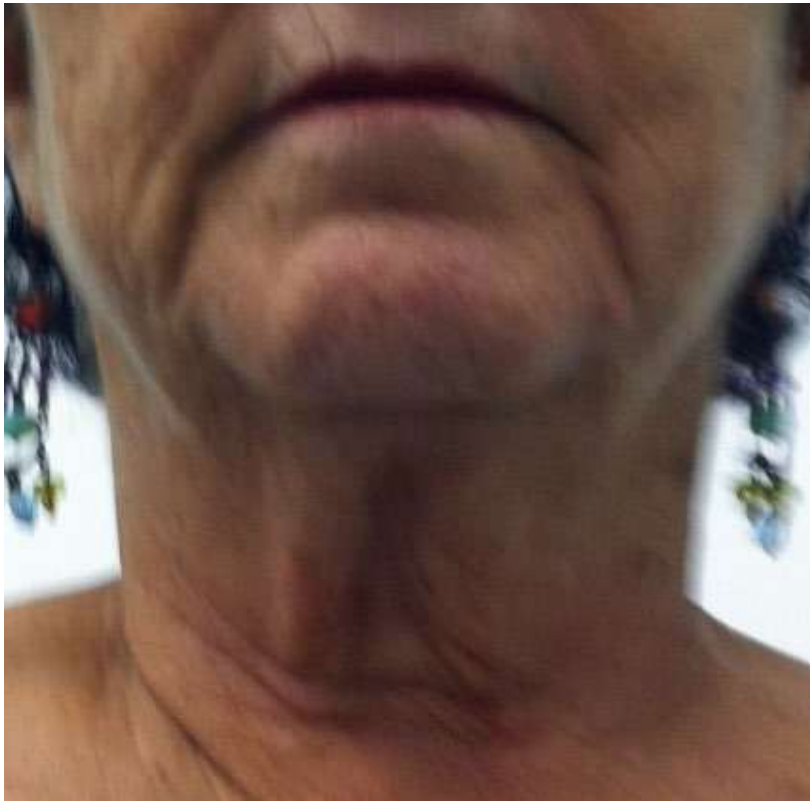
Before



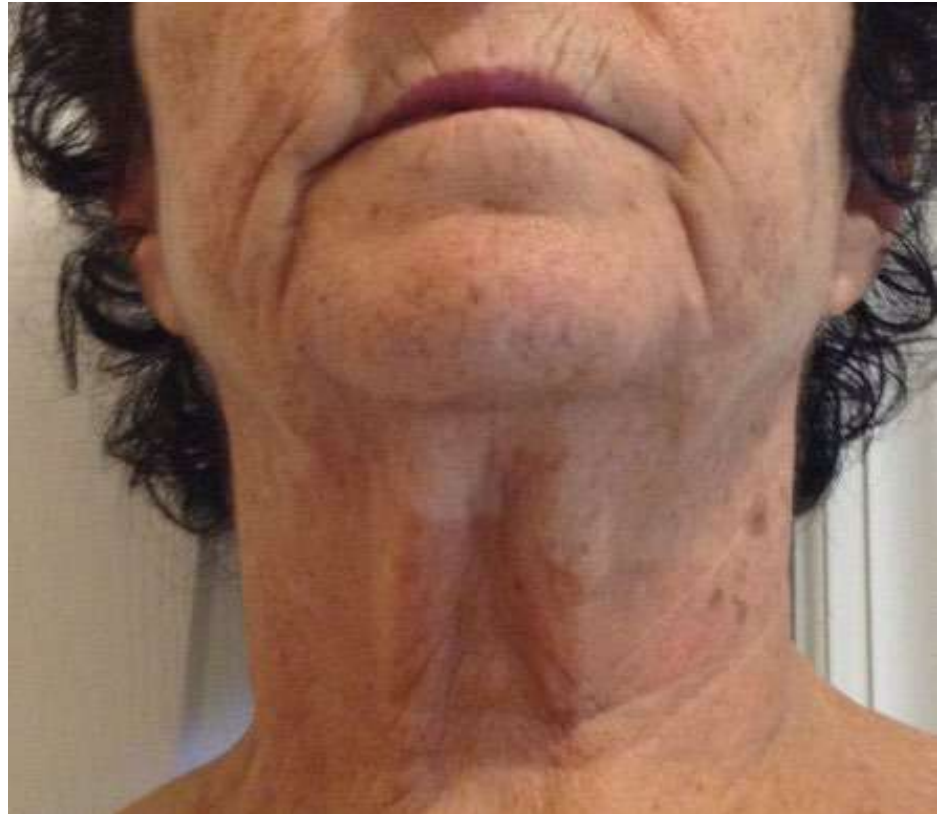After

Face

Case Study – RE#303-C	Viora Inc., USA
Patient	Female, 60 years old
Number of Treatments	3 V-ST



Before



After

Face

Case Study – RE#331-A

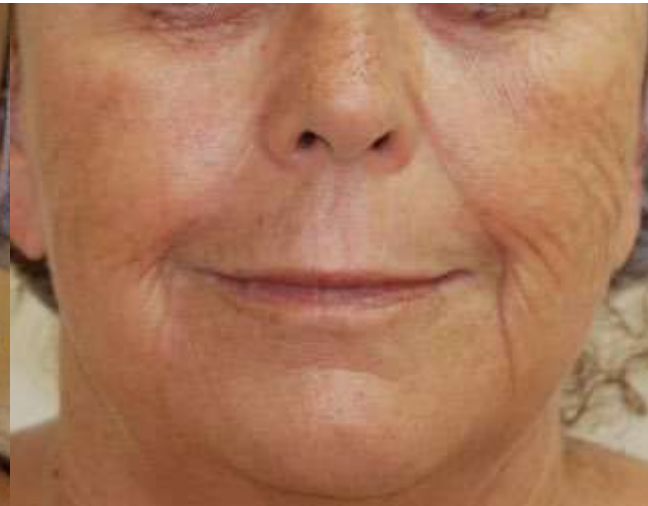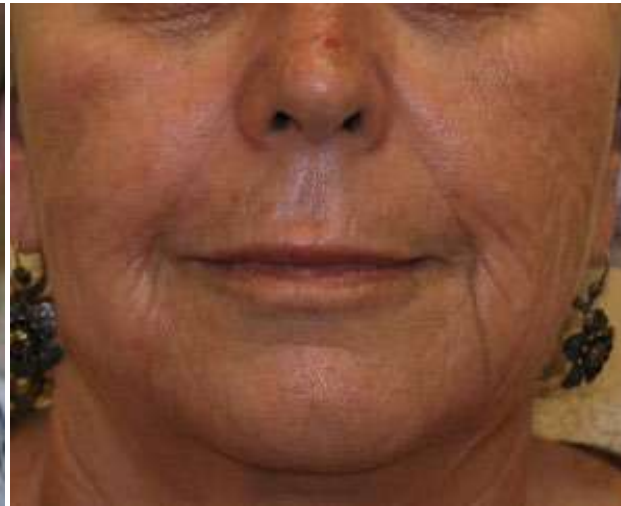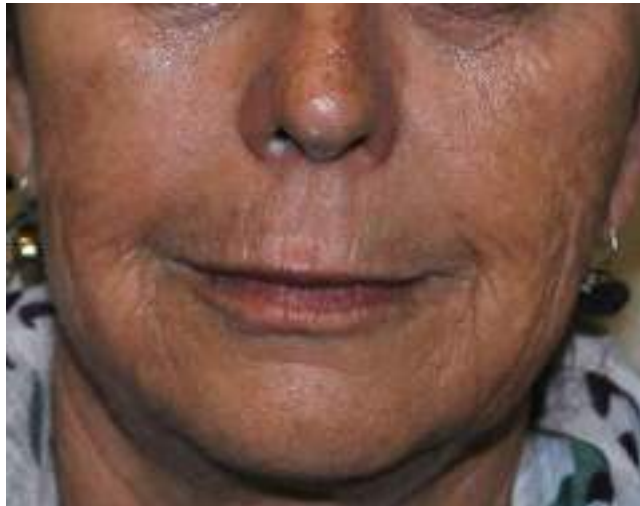Dr Monica Elman, Beit Harofim Medical Center, Israel

Patient

Female, 63 years old

Number of Treatments

5 V-ST



Before

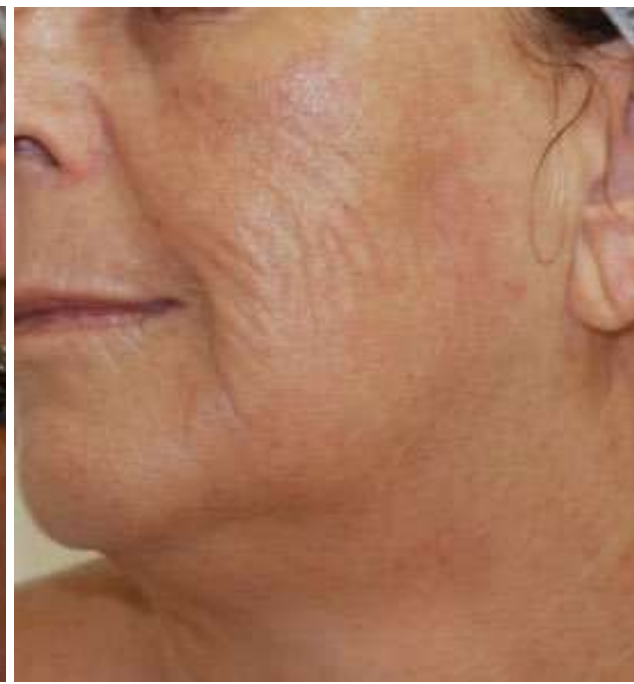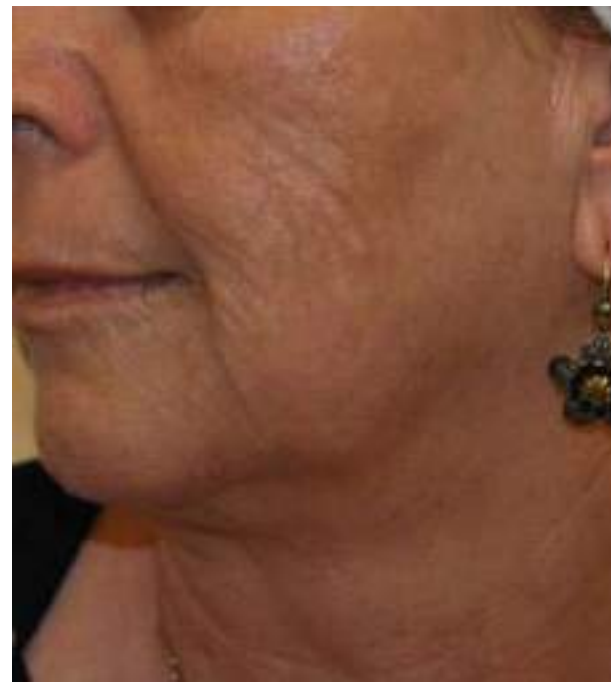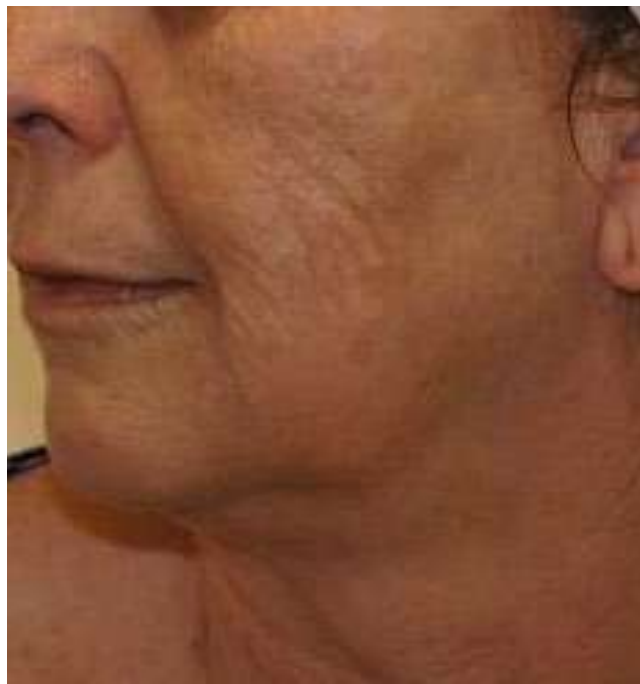After 5 treatments

Follow-up (3 month)



Face

Case Study – RE#331-B	Dr Monica Elman, Beit Harofim Medical Center, Israel
Patient	Female, 63 years old
Number of Treatments	5 V-ST



Before

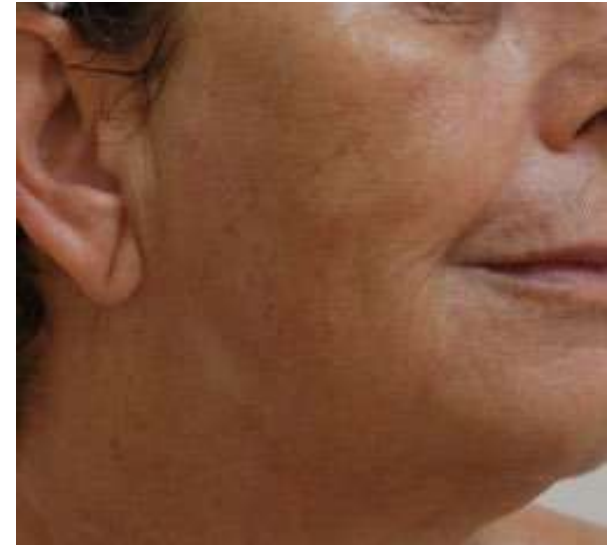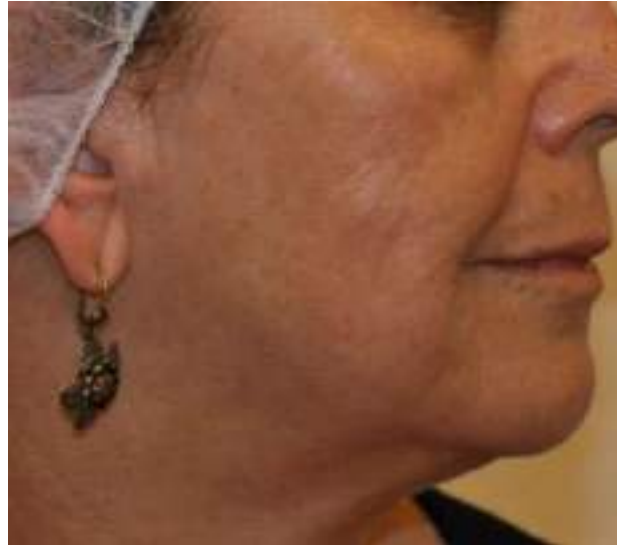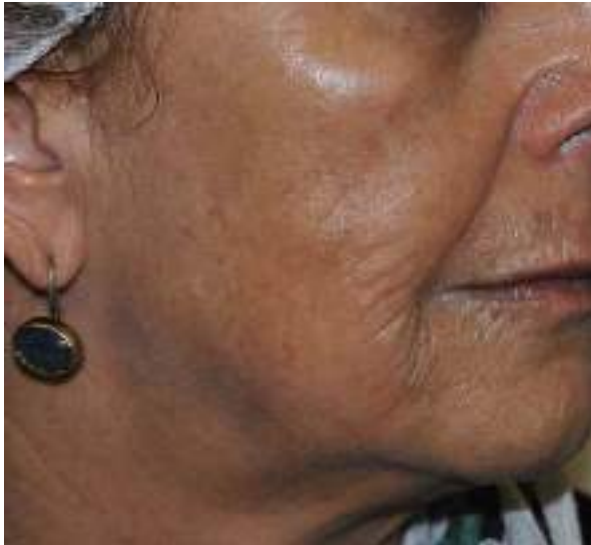After 5 treatments

Follow-up (3 month)



Face

Case Study – RE#331-C	Dr Monica Elman, Beit Harofim Medical Center, Israel
Patient	Female, 63 years old
Number of Treatments	5 V-ST



Before

After 5 treatments

Follow-up (3 month)



Face

Case Study – RE#333-A

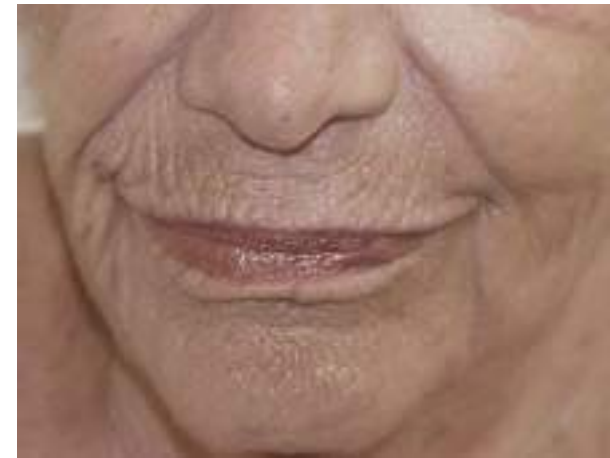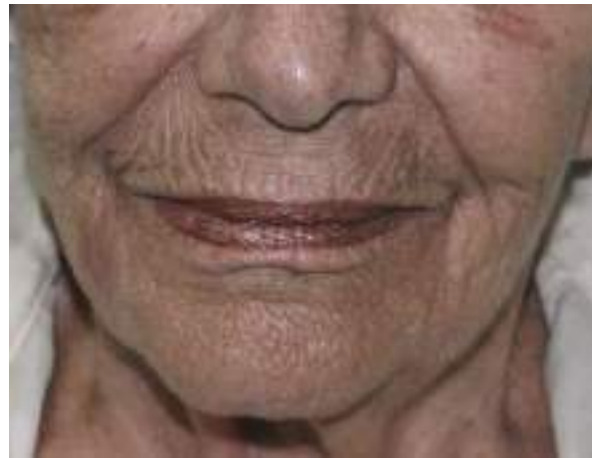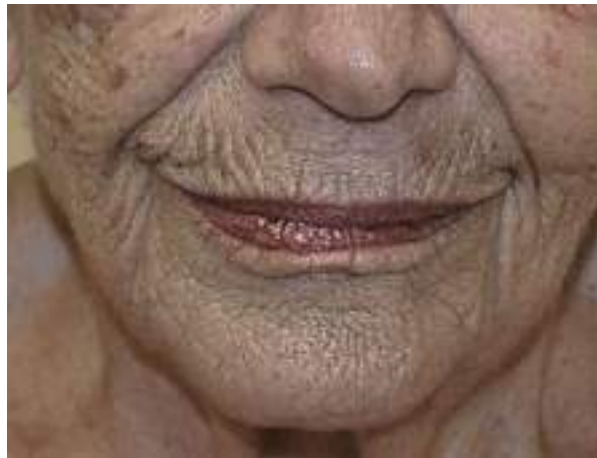Dr Monica Elman, Beit Harofim Medical Center, Israel

Patient

Female, 82 years old

Number of Treatments

5 V-ST



Before

After 5 treatments

Follow-up (3 month)



Face

Case Study – RE#333-B

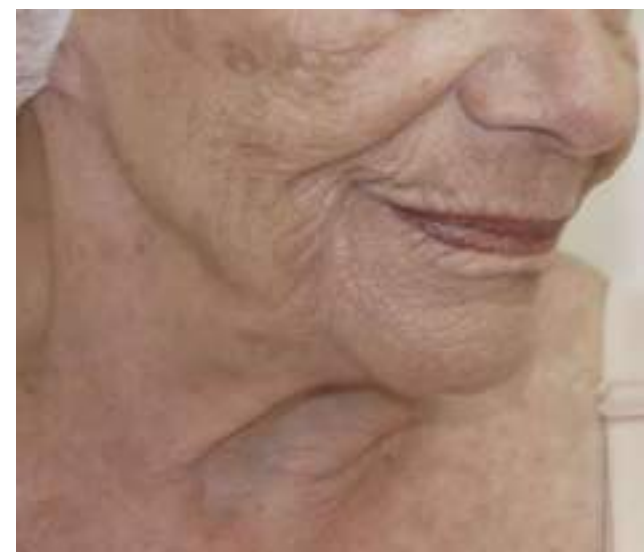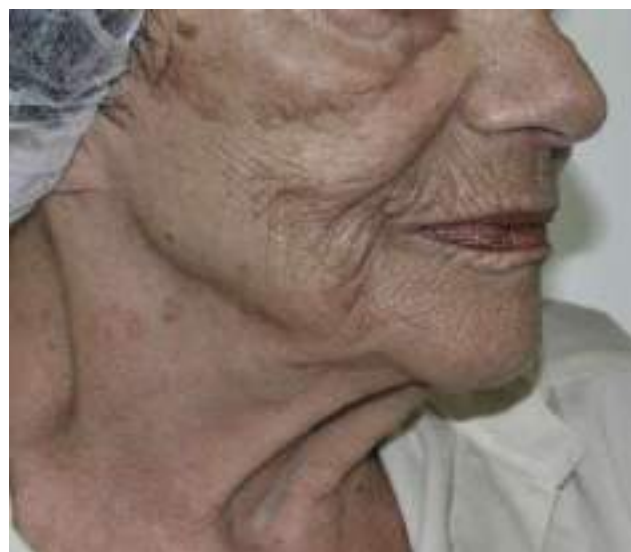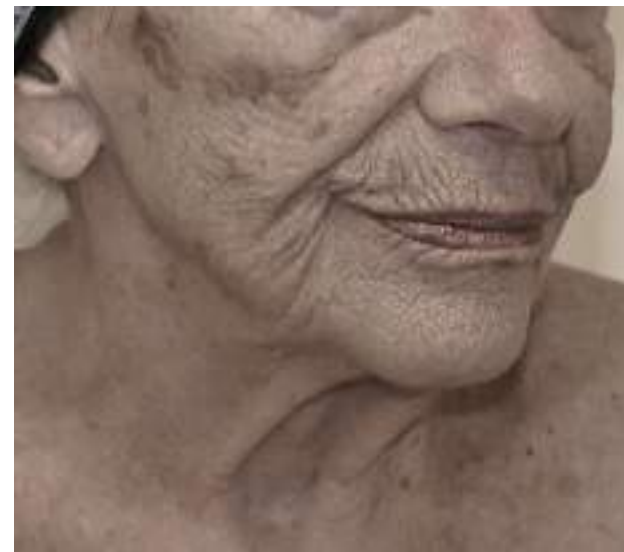Dr Monica Elman, Beit Harofim Medical Center, Israel

Patient

Female, 82 years old

Number of Treatments

5 V-ST



Before

After 5 treatments

Follow-up (3 month)



Face

Case Study – RE#333-C

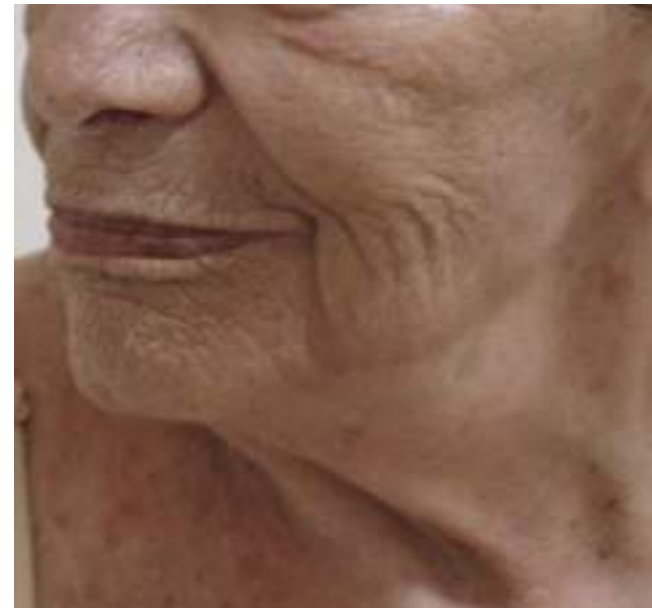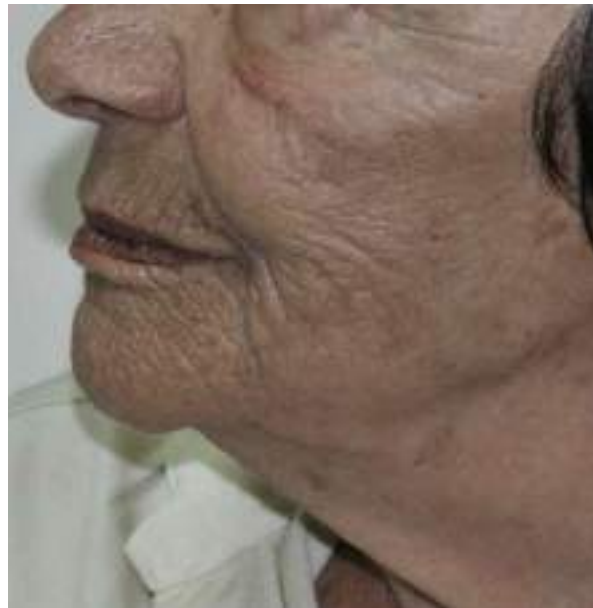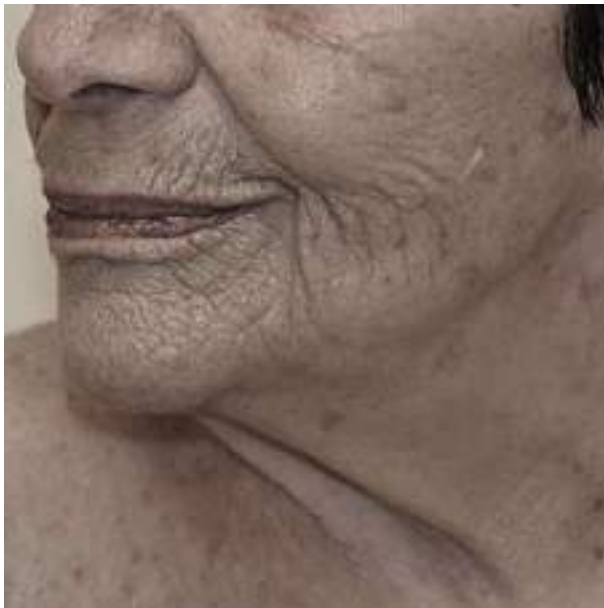Dr Monica Elman, Beit Harofim Medical Center, Israel

Patient

Female, 82 years old

Number of Treatments

5 V-ST



Before

After 5 treatments

Follow-up (3 month)



Face

Case Study – RE#334-A

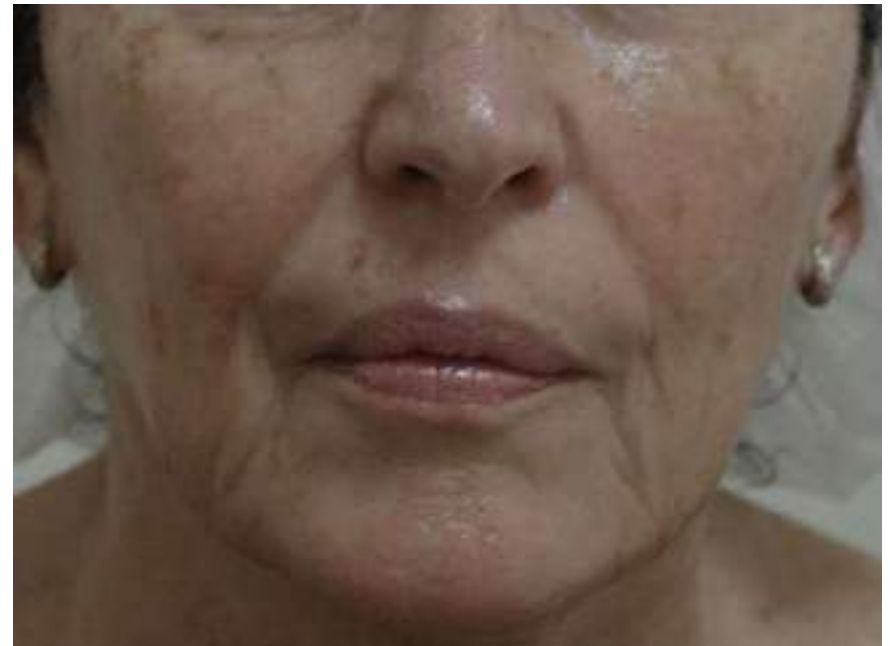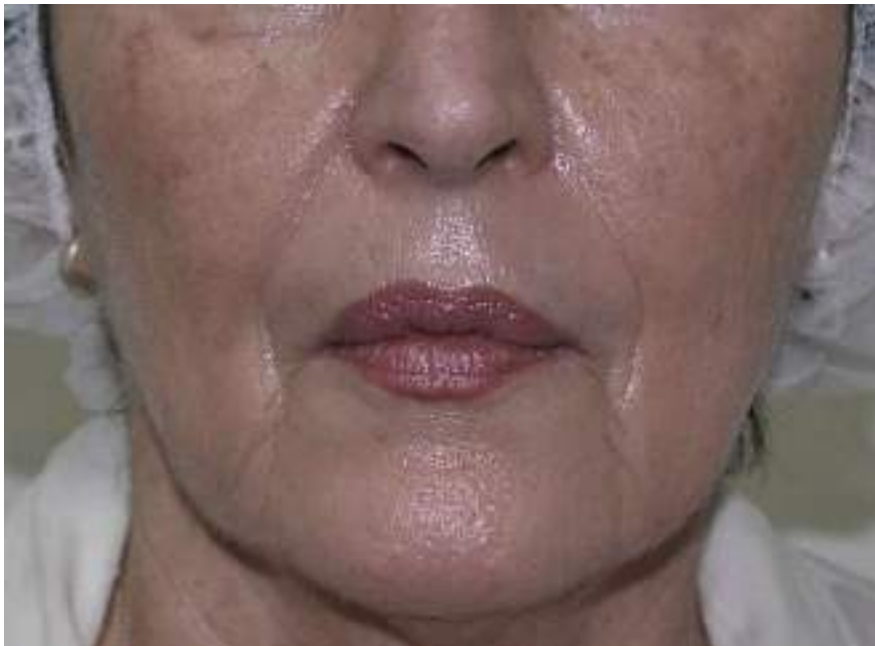Dr Monica Elman, Beit Harofim Medical Center, Israel

Patient

Female, 66 years old

Number of Treatments

5 V-ST



Before

After



Face

Case Study – RE#334-B

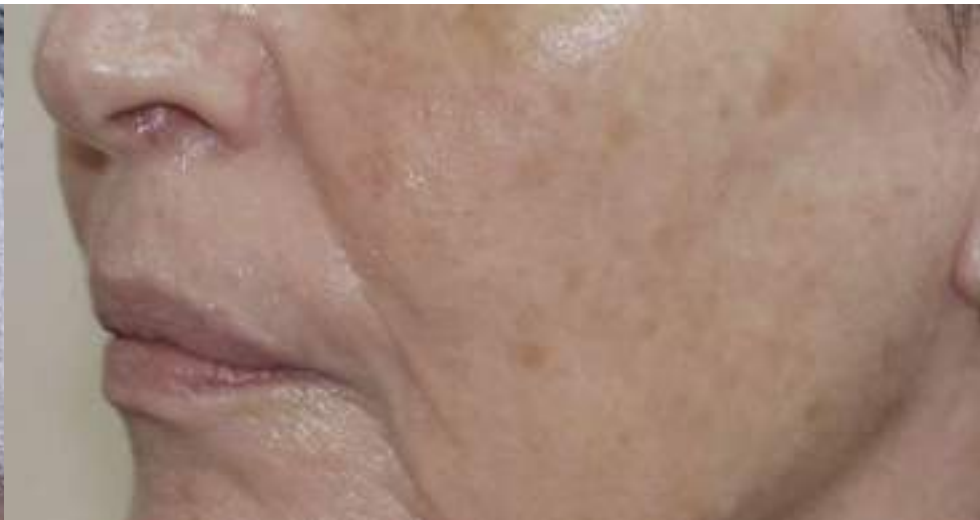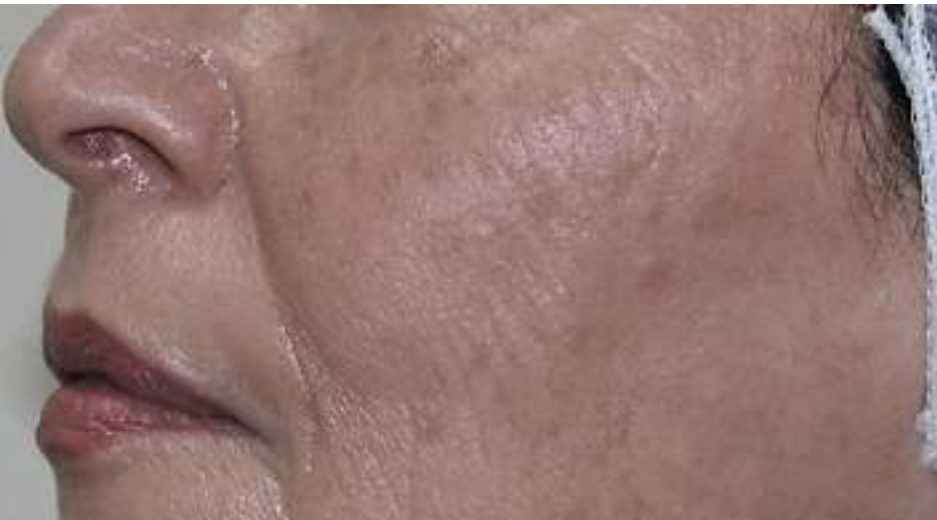Dr Monica Elman, Beit Harofim Medical Center, Israel

Patient

Female, 66 years old

Number of Treatments

5 V-ST



Before

After



Face

Case Study – RE#334-A

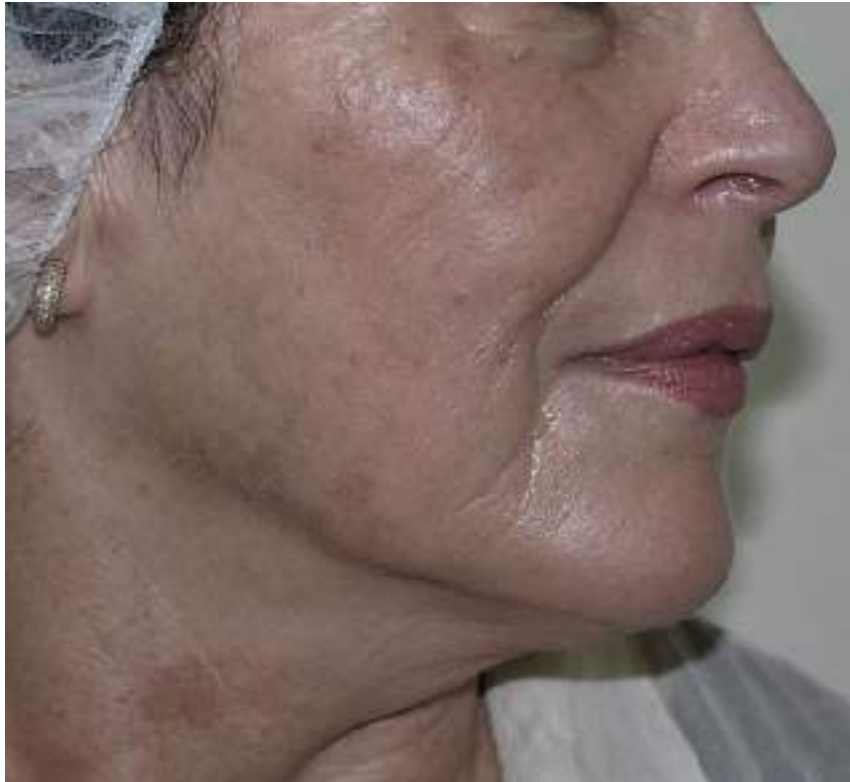Dr Monica Elman, Beit Harofim Medical Center, Israel

Patient

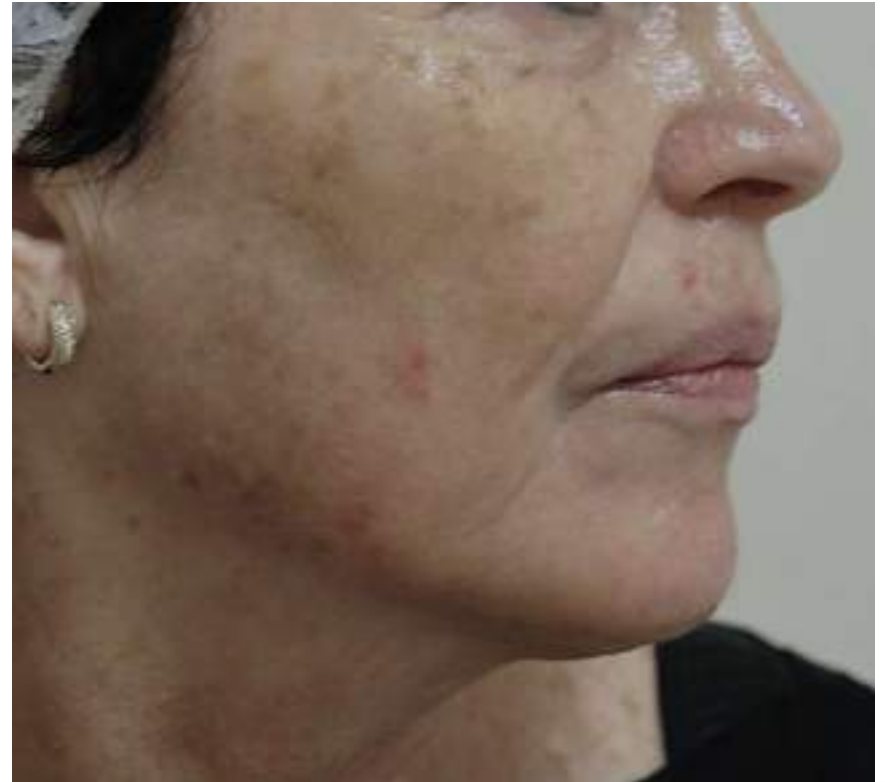Female, 66 years old

Number of Treatments

5 V-ST



Before



After

Face

Case Study – RE#335-A

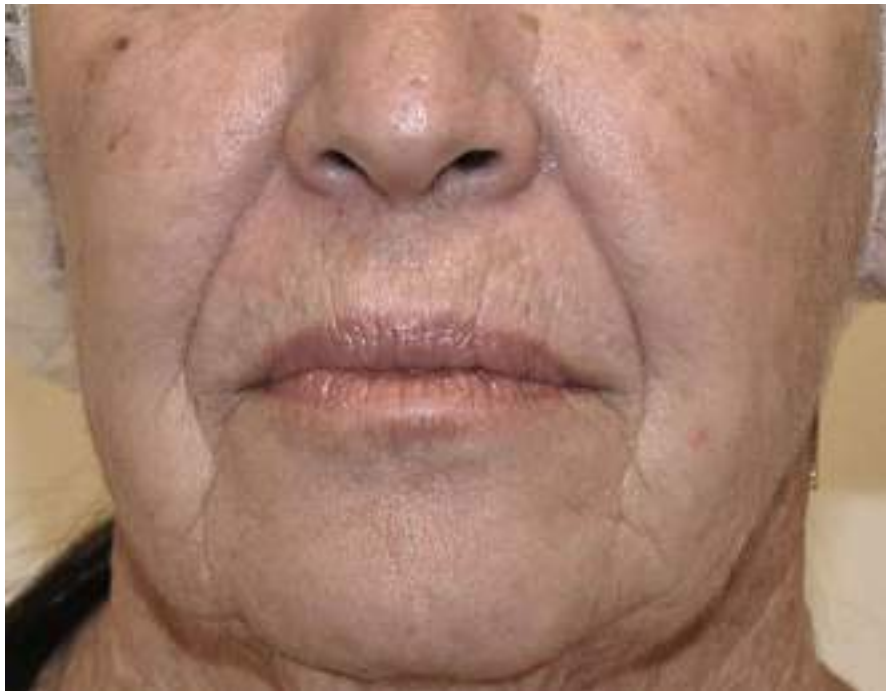Dr Monica Elman, Beit Harofim Medical Center, Israel

Patient

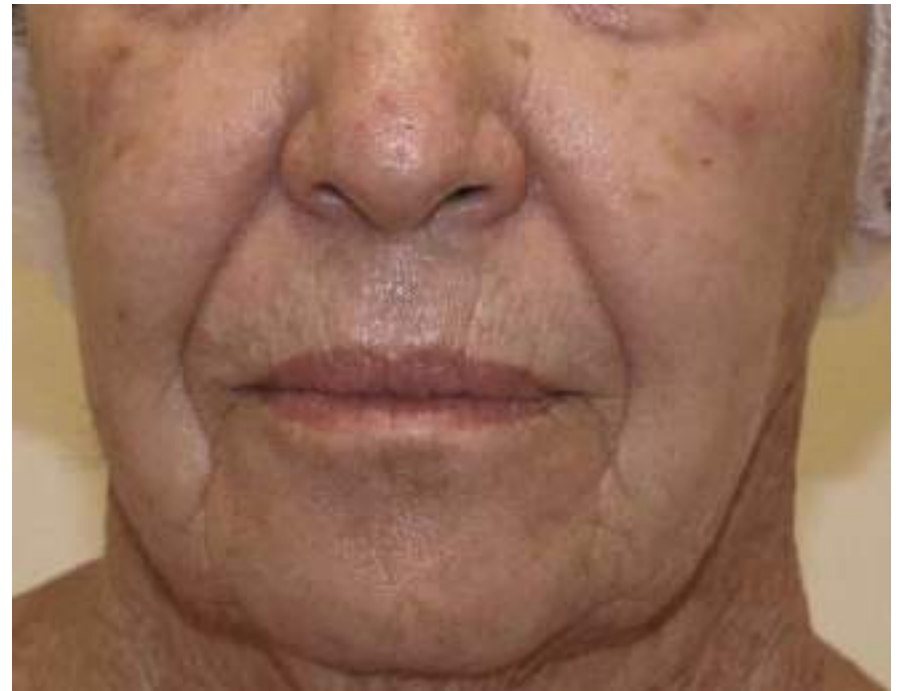Female, 72 years old

Number of Treatments

5 V-ST



Before



After



Face

Case Study – RE#335-B

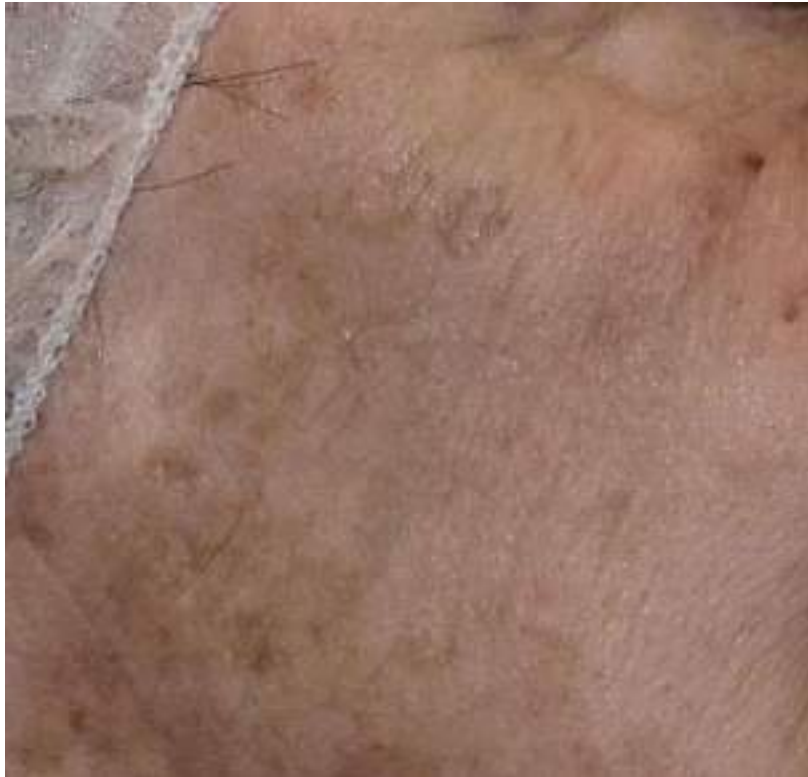Dr Monica Elman, Beit Harofim Medical Center, Israel

Patient

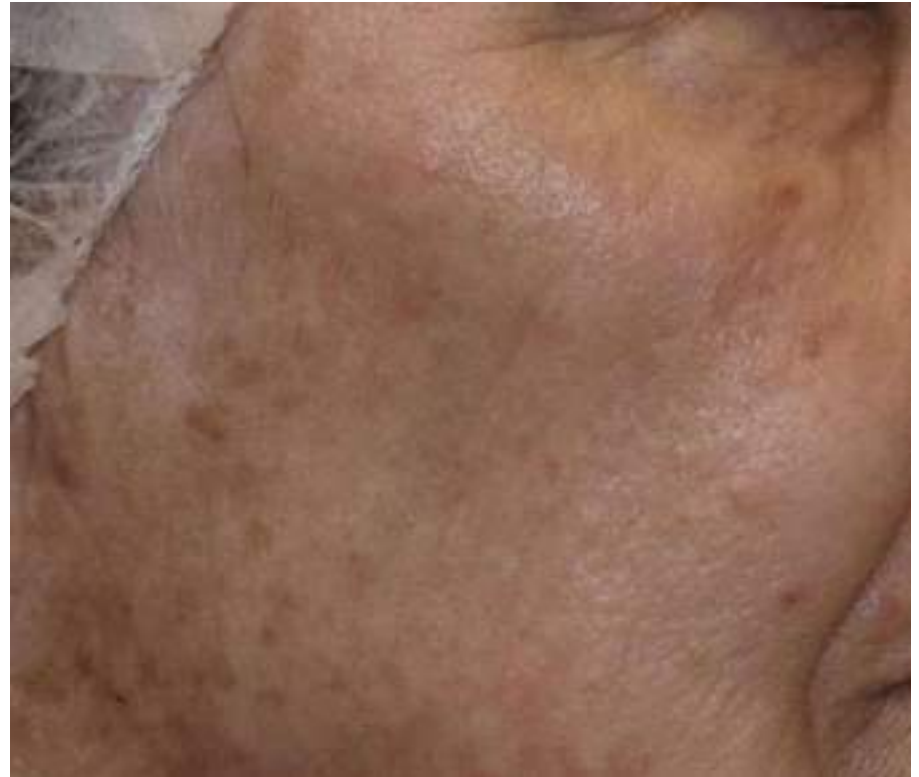Female, 72 years old

Number of Treatments

5 V-ST



Before



After



Face

Case Study – RE#335-C

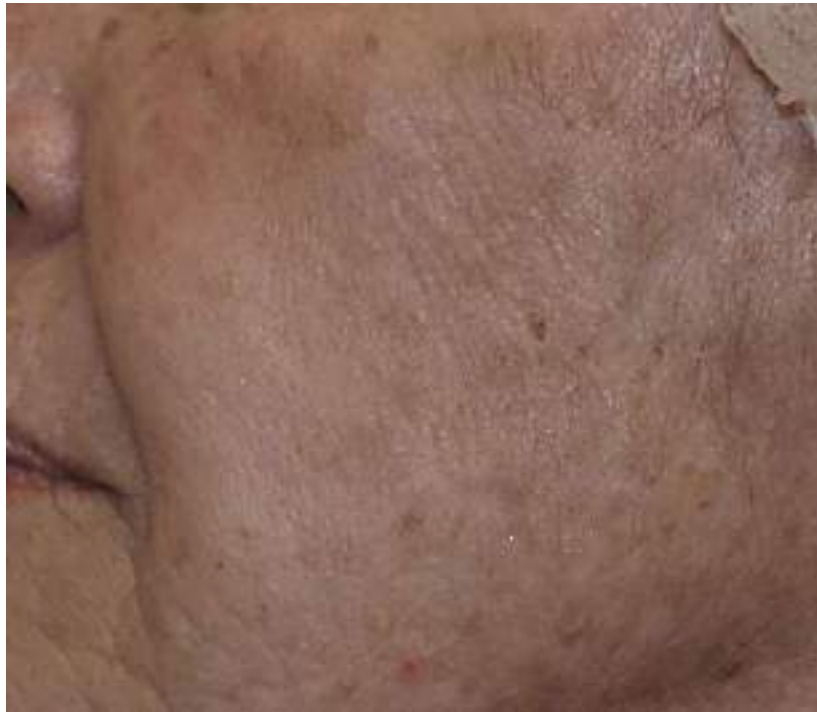Dr Monica Elman, Beit Harofim Medical Center, Israel

Patient

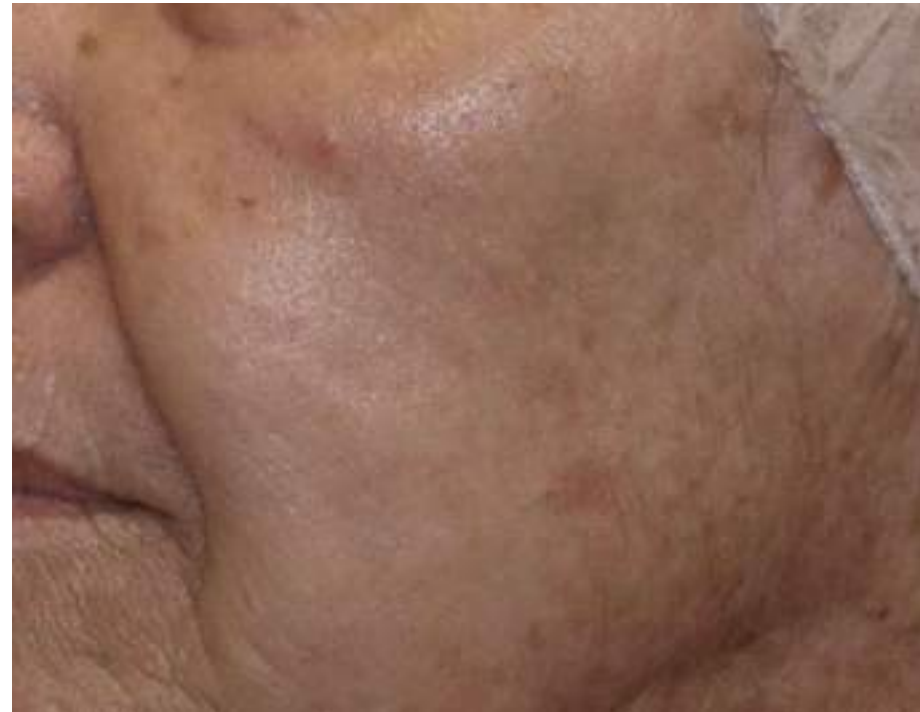Female, 72 years old

Number of Treatments

5 V-ST



Before

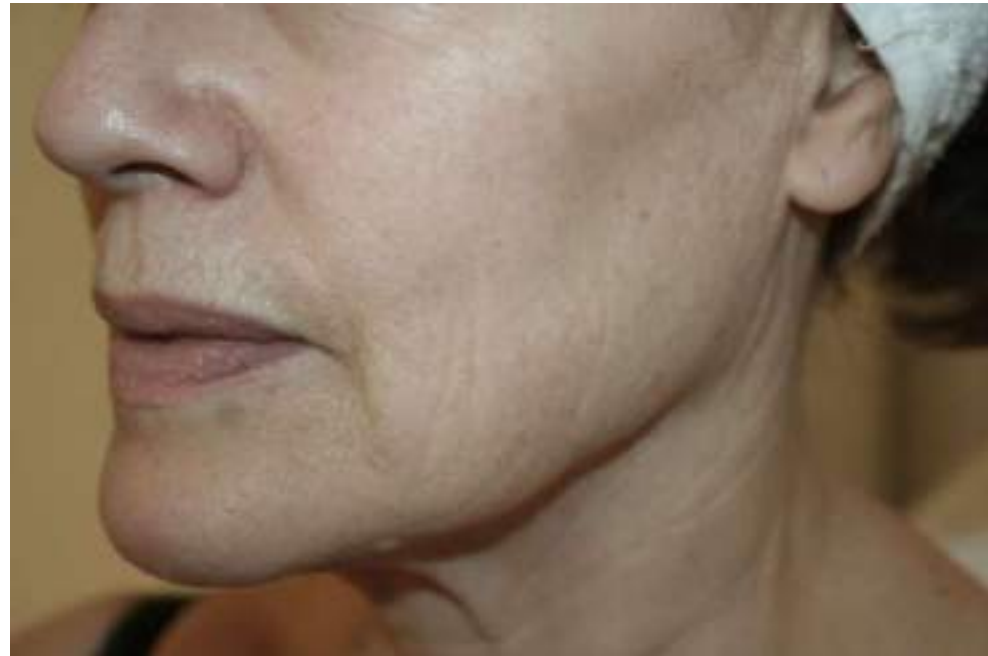
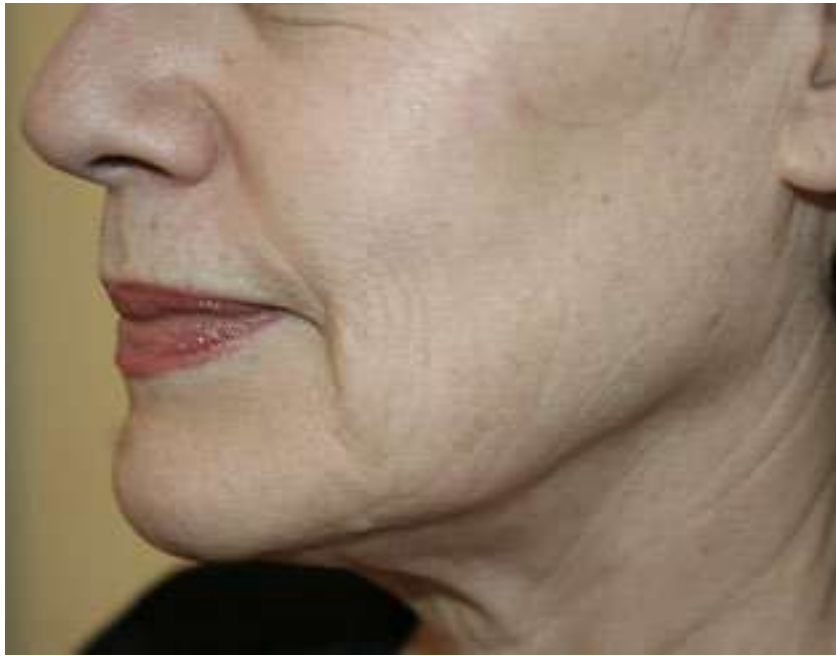
After



Sagging skin and wrinkles

Case Study – RE#315-A	Dr. Marina Vashkevich, Toronto, Canada
Patient	Female, 64 years old
Number of Treatments	5 V-ST



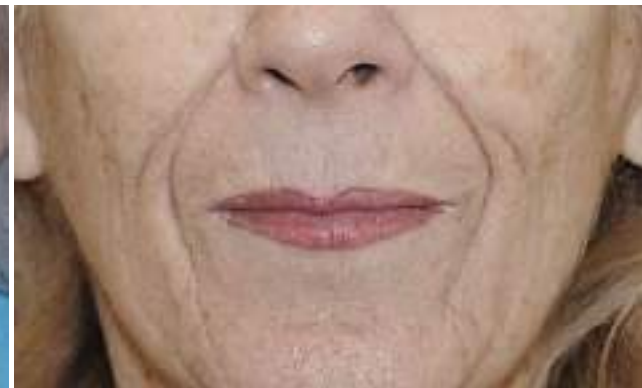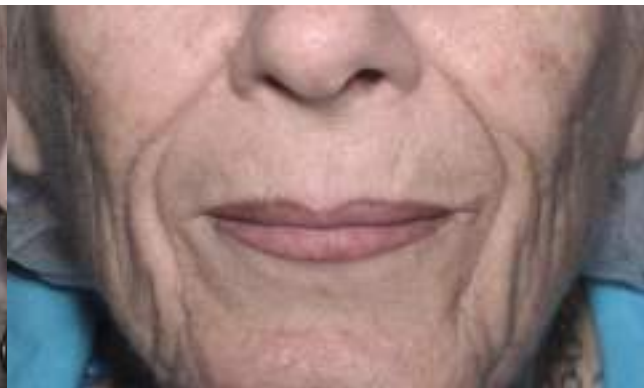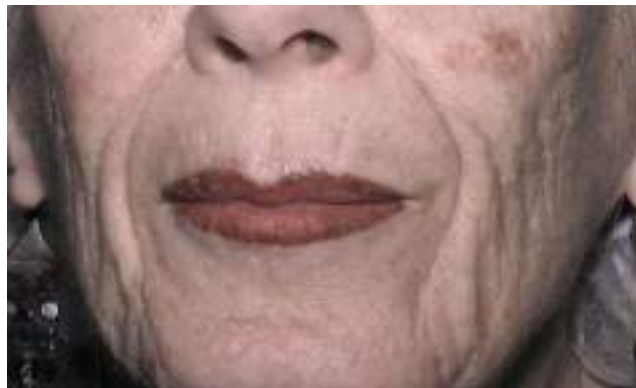Before

After



Face

Case Study – RE#343-A	Dr Monica Elman, Beit Harofim Medical Center, Israel
Patient	Female, 65 years old
Number of Treatments	6 V-ST



Before

Post 3 Treatments

Post 6 treatments



Face

Case Study – RE#343-B

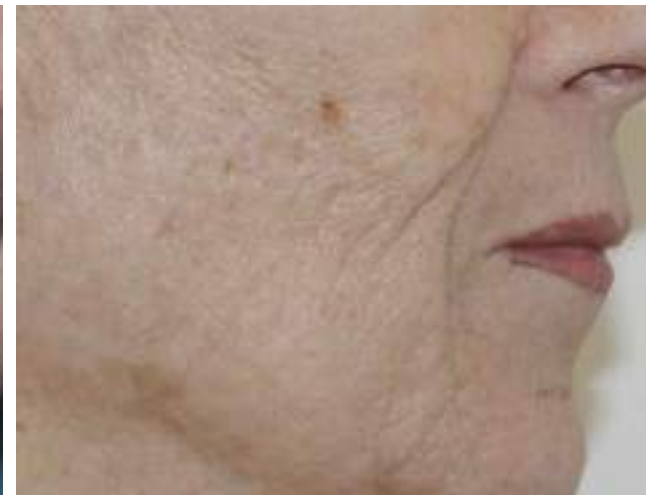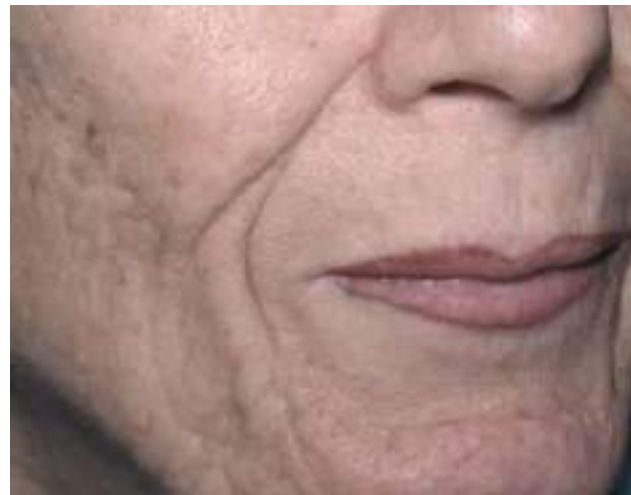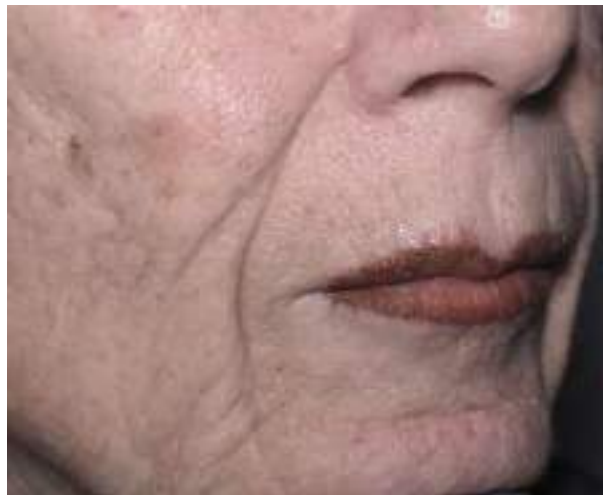Dr Monica Elman, Beit Harofim Medical Center, Israel

Patient

Female, 65 years old

Number of Treatments

6 V-ST



Before

Post 3 Treatments

Post 6 treatments



Face

Case Study – RE#343-C

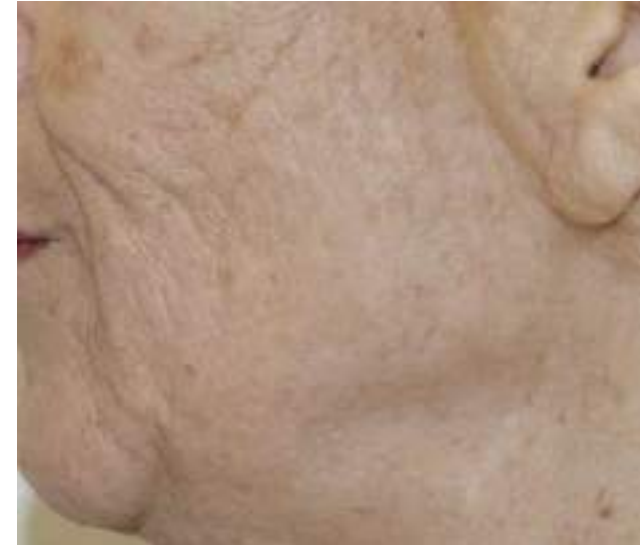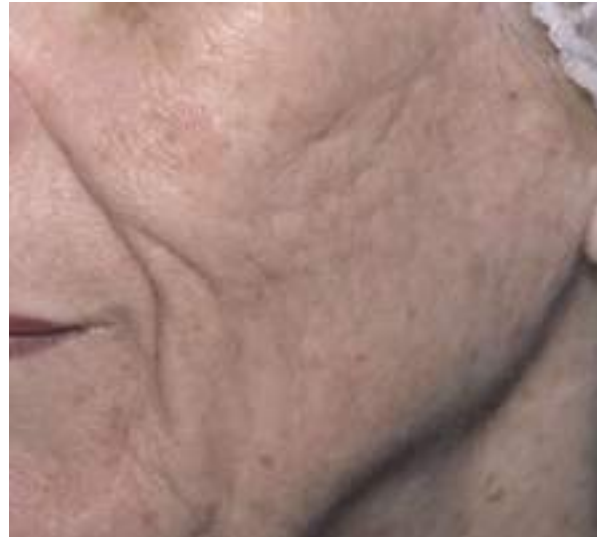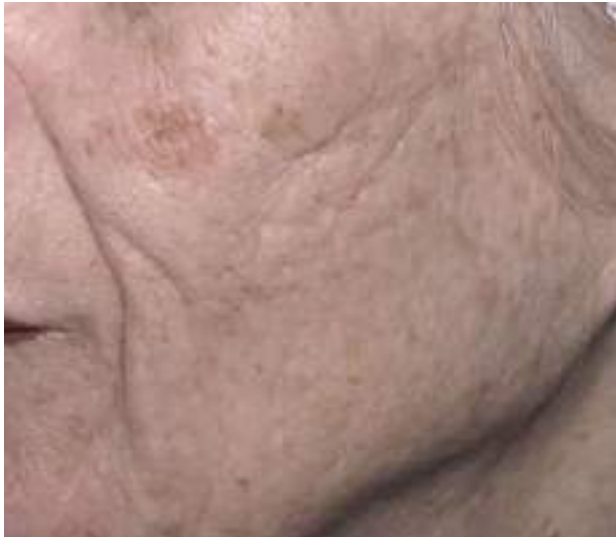Dr Monica Elman, Beit Harofim Medical Center, Israel

Patient

Female, 65 years old

Number of Treatments

6 V-ST



Before

Post 3 Treatments

Post 6 treatments



Face

Case Study – RE#344-A

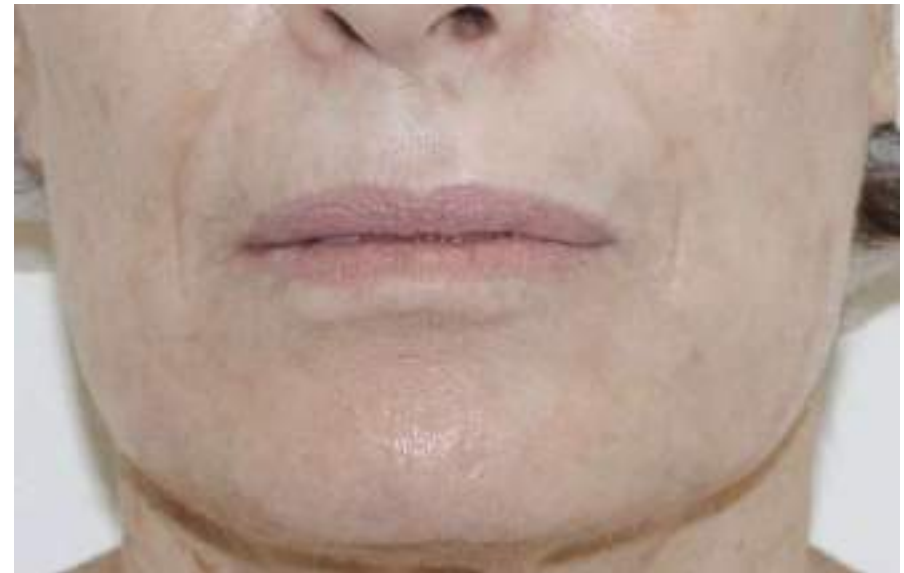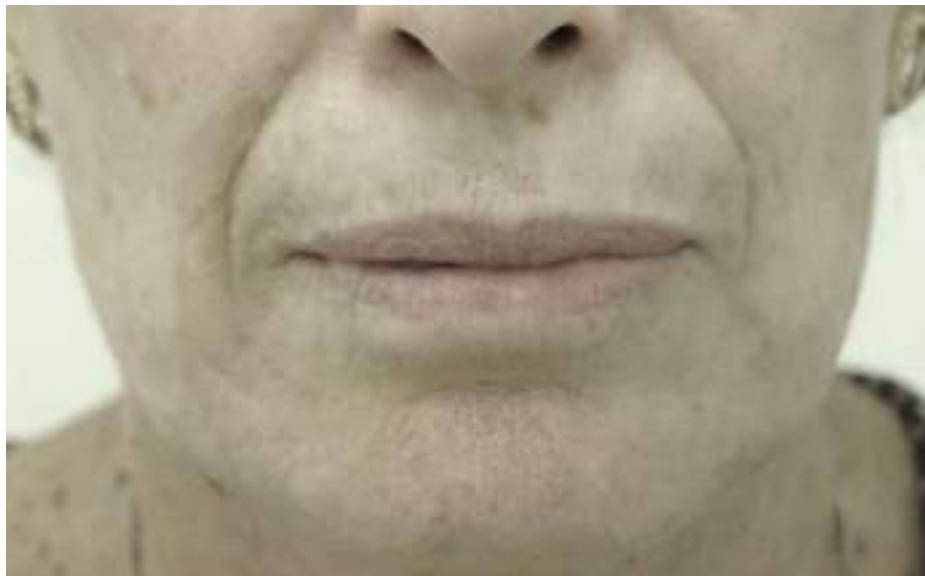Dr Monica Elman, Beit Harofim Medical Center, Israel

Patient

Female, 64 years old

Number of Treatments

3 V-ST



Before

After



Face

Case Study – RE#344-C

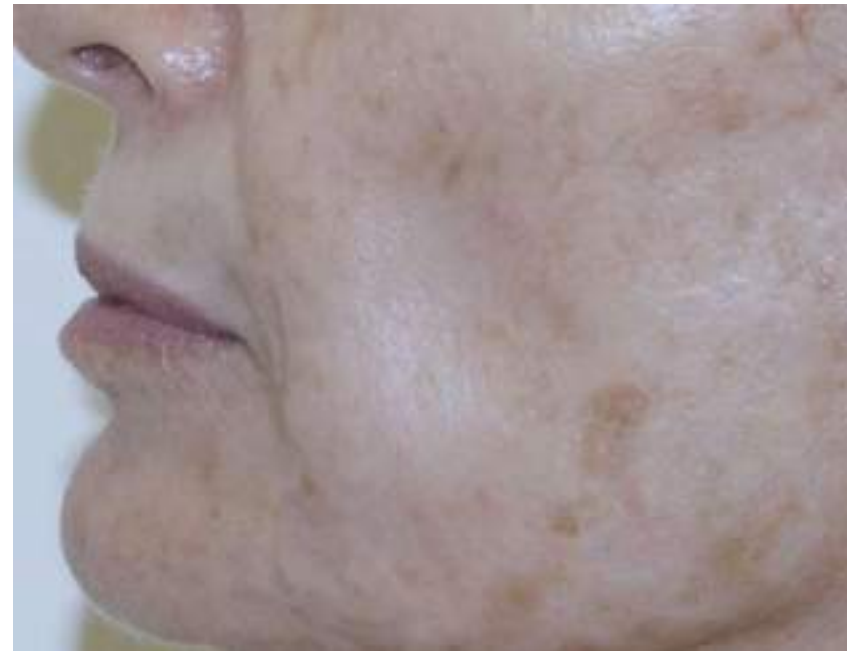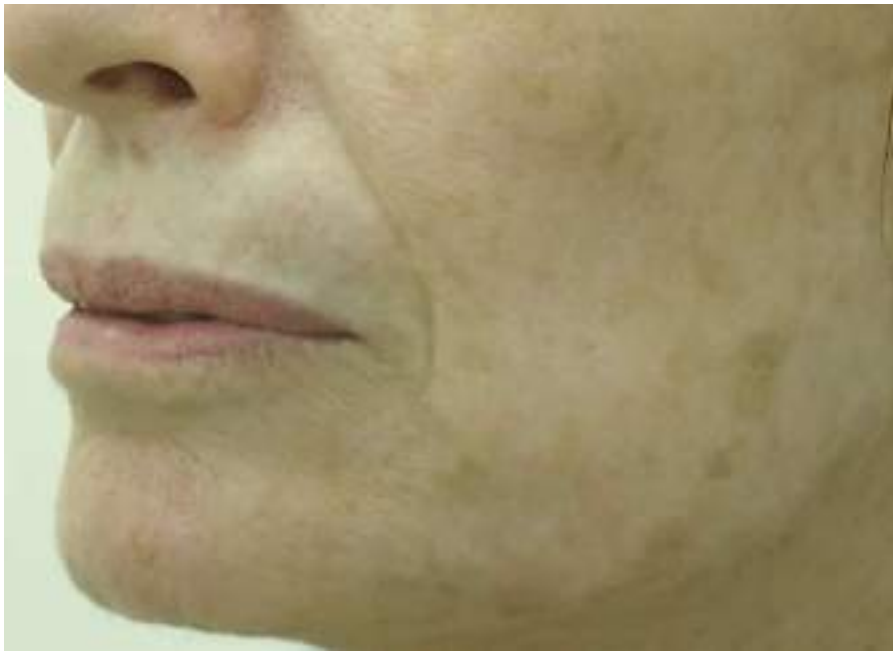Dr Monica Elman, Beit Harofim Medical Center, Israel

Patient

Female, 64 years old

Number of Treatments

3 V-ST



Before

After



Face

Case Study – RE#344-D

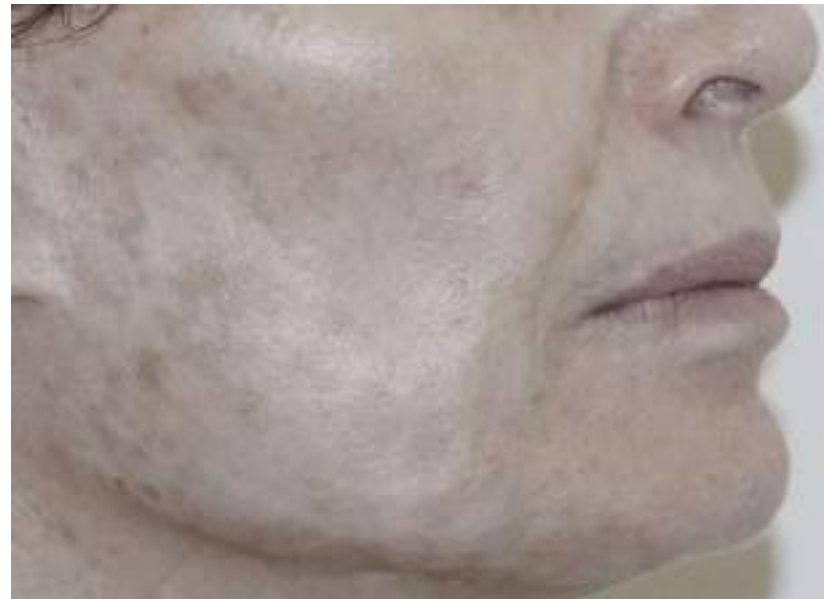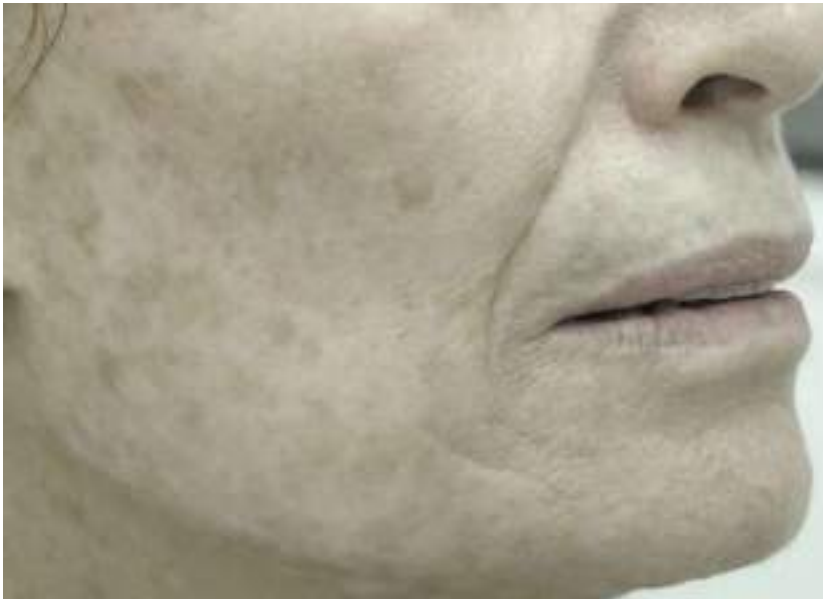Dr Monica Elman, Beit Harofim Medical Center, Israel

Patient

Female, 64 years old

Number of Treatments

3 V-ST



Before

After



Face

Case Study – RE#345-A

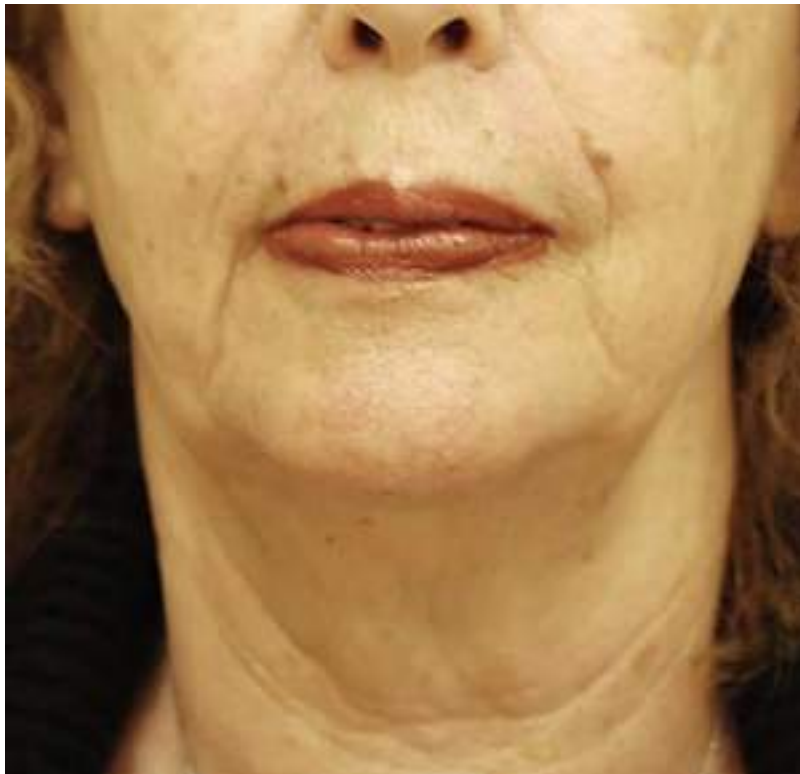Dr Monica Elman, Beit Harofim Medical Center, Israel

Patient

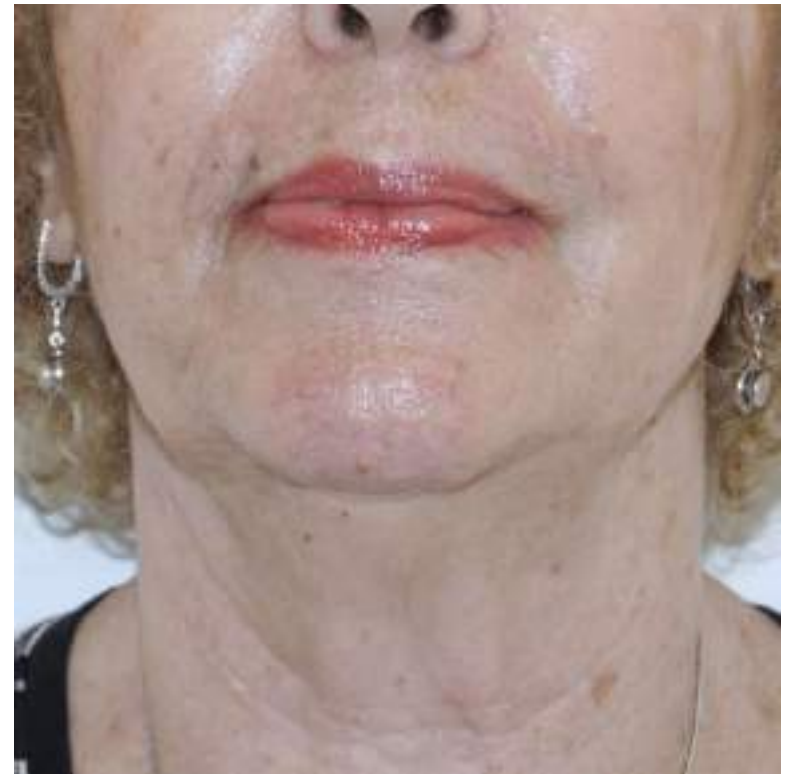Female, 77 years old

Number of Treatments

6 V-ST



Before



After



Face

Case Study – RE#345-B

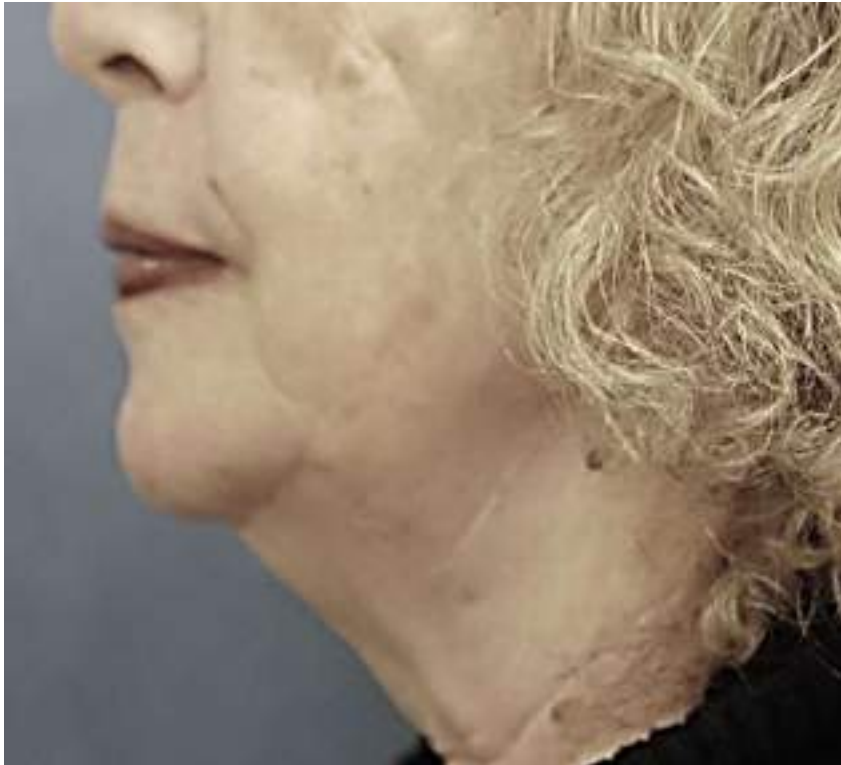Dr Monica Elman, Beit Harofim Medical Center, Israel

Patient

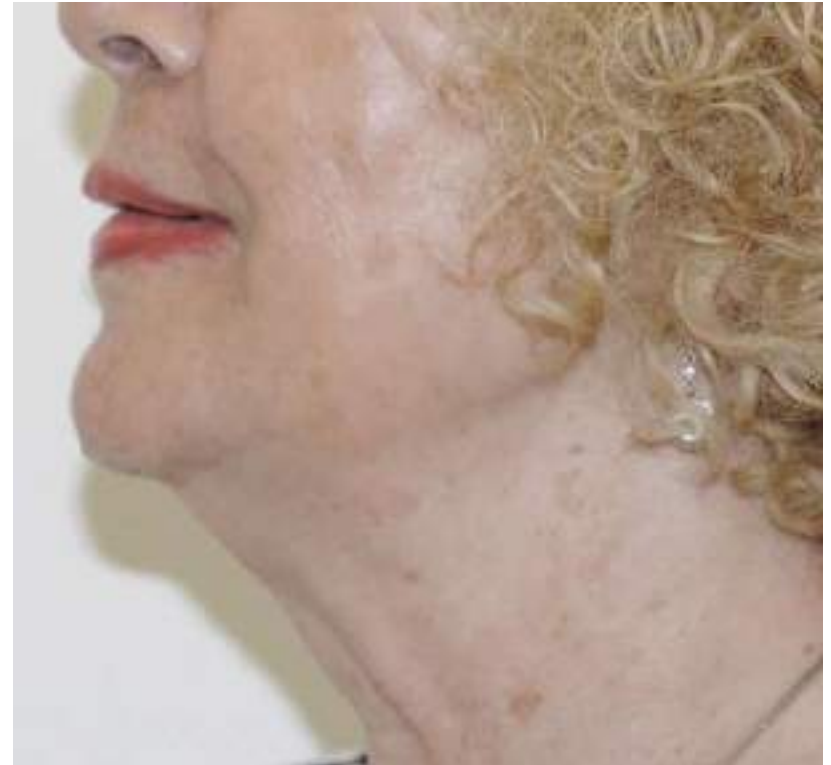Female, 77 years old

Number of Treatments

6 V-ST



Before



After



Face

Case Study – RE#345-C

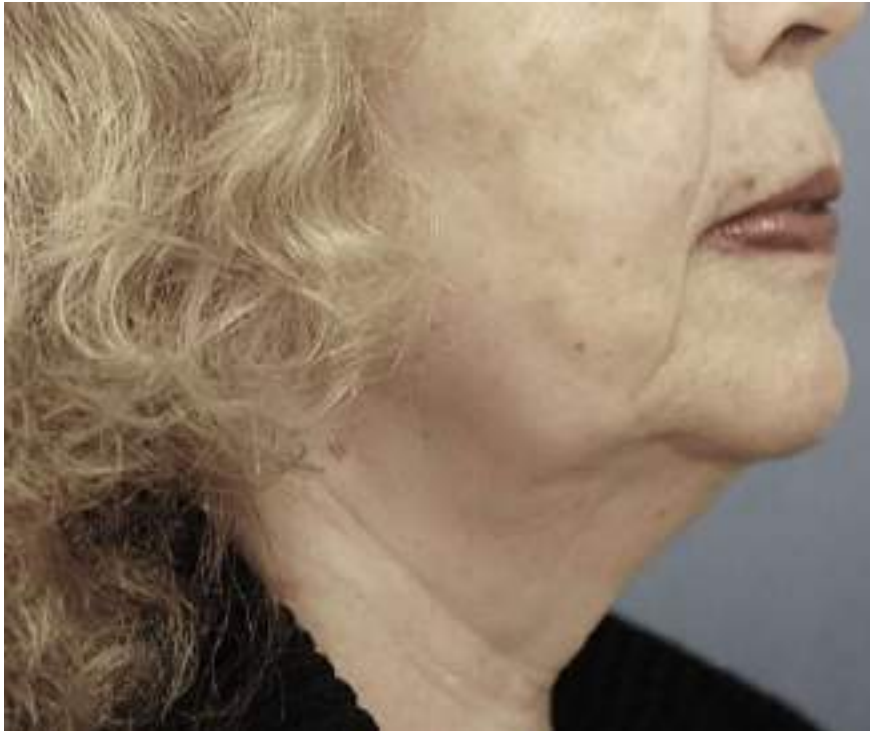Dr Monica Elman, Beit Harofim Medical Center, Israel

Patient

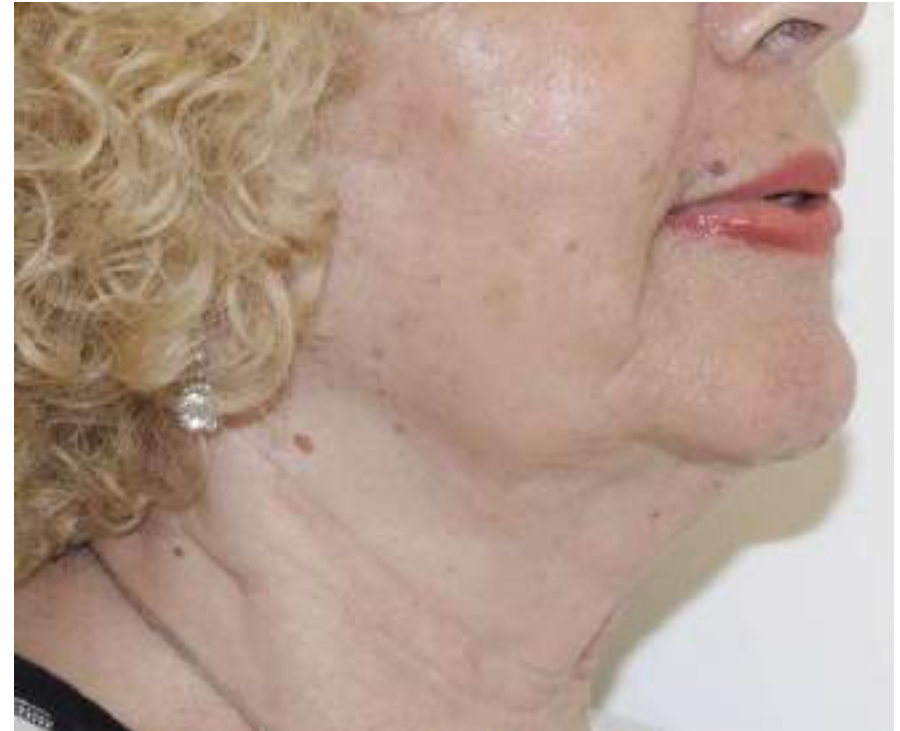Female, 77 years old

Number of Treatments

6 V-ST



Before



After

Face

Case Study – RE#346-A

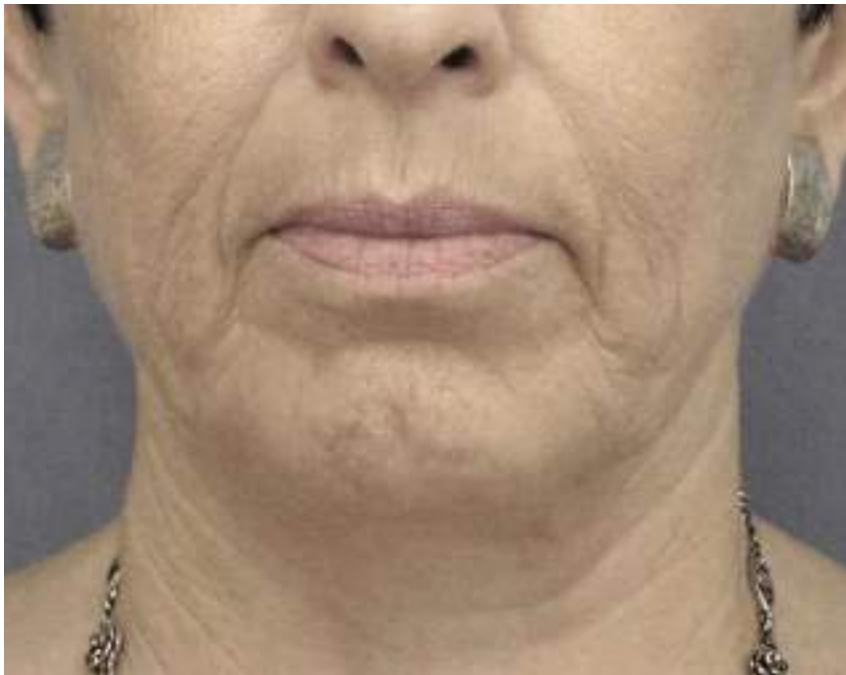Dr Monica Elman, Beit Harofim Medical Center, Israel

Patient

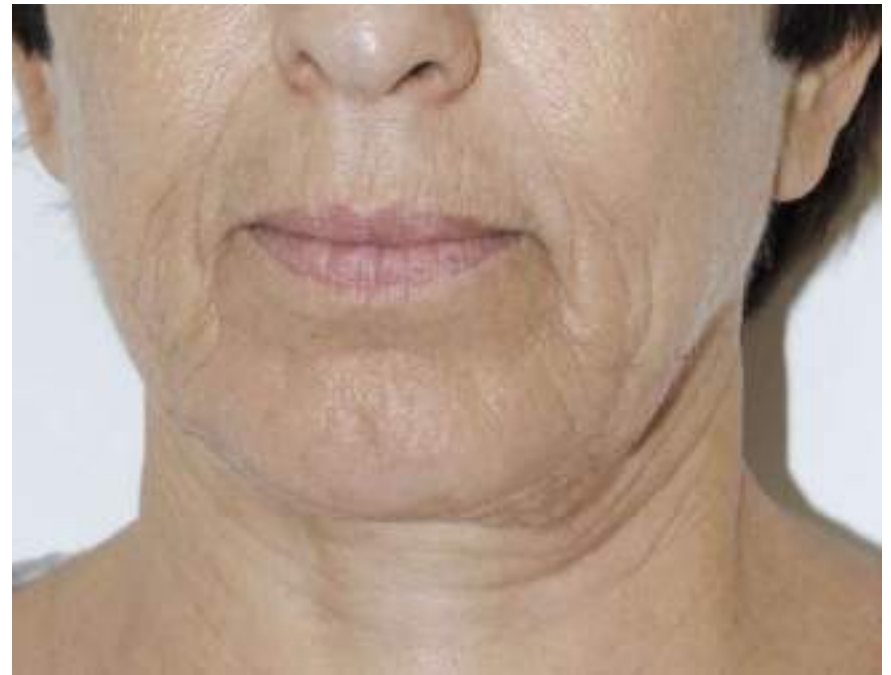Female, 67 years old

Number of Treatments

3 V-ST



Before



After



Face

Case Study – RE#346-B

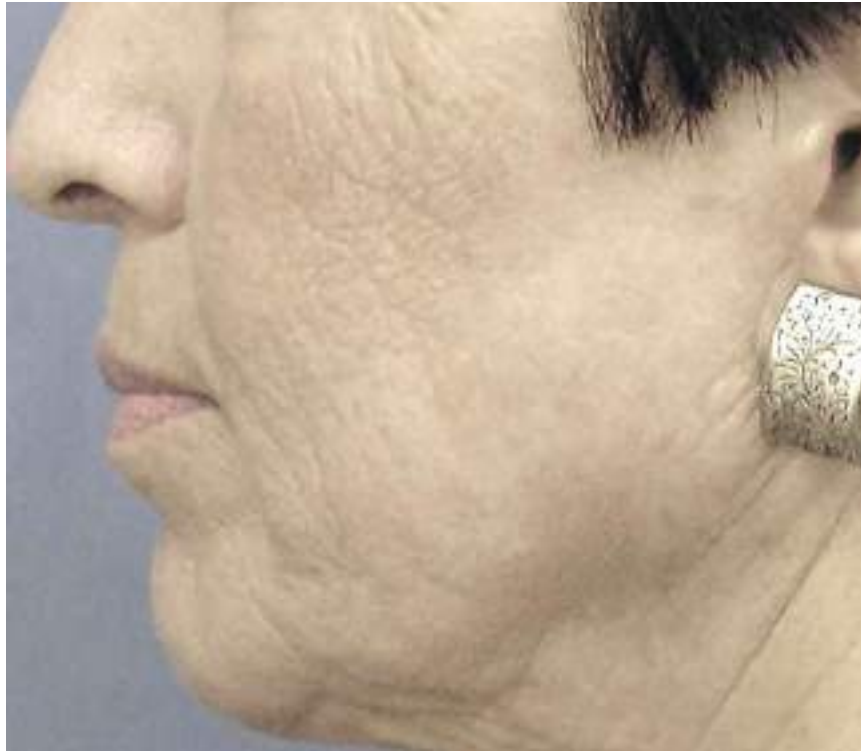Dr Monica Elman, Beit Harofim Medical Center, Israel

Patient

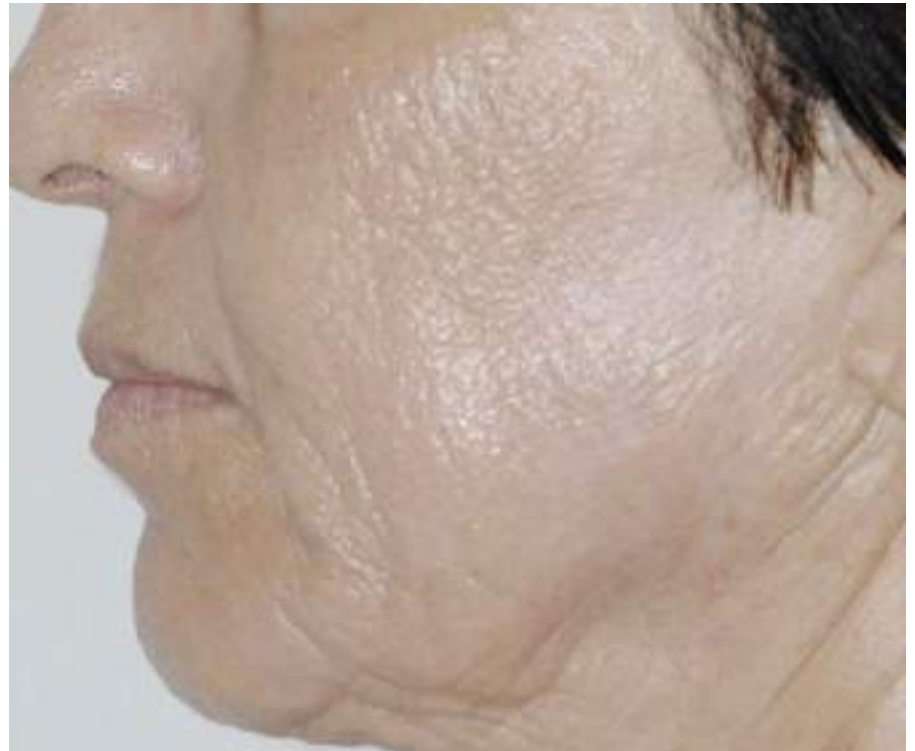Female, 67 years old

Number of Treatments

3 V-ST



Before



After



Face

Case Study – RE#346-C

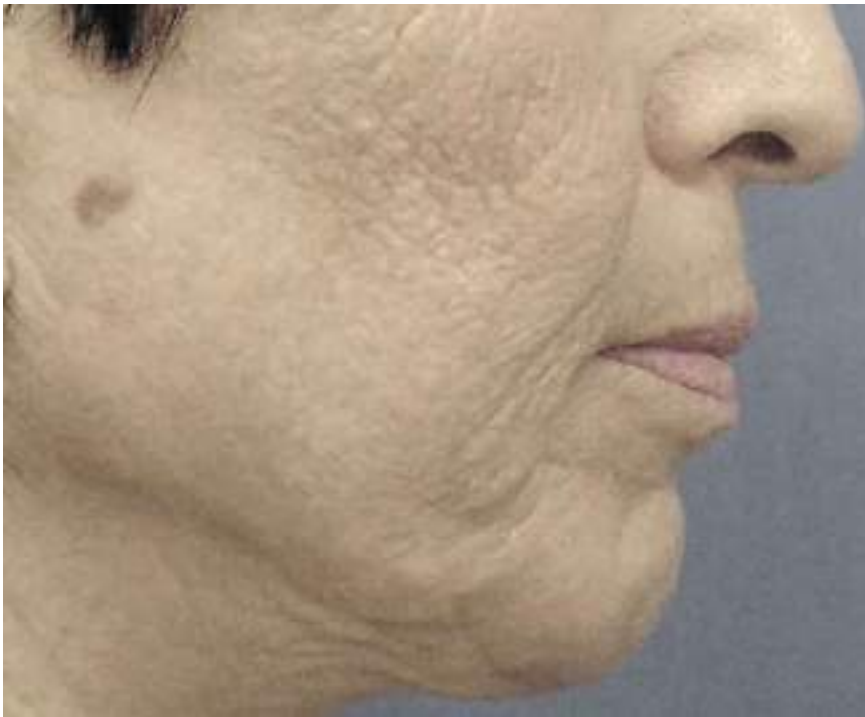Dr Monica Elman, Beit Harofim Medical Center, Israel

Patient

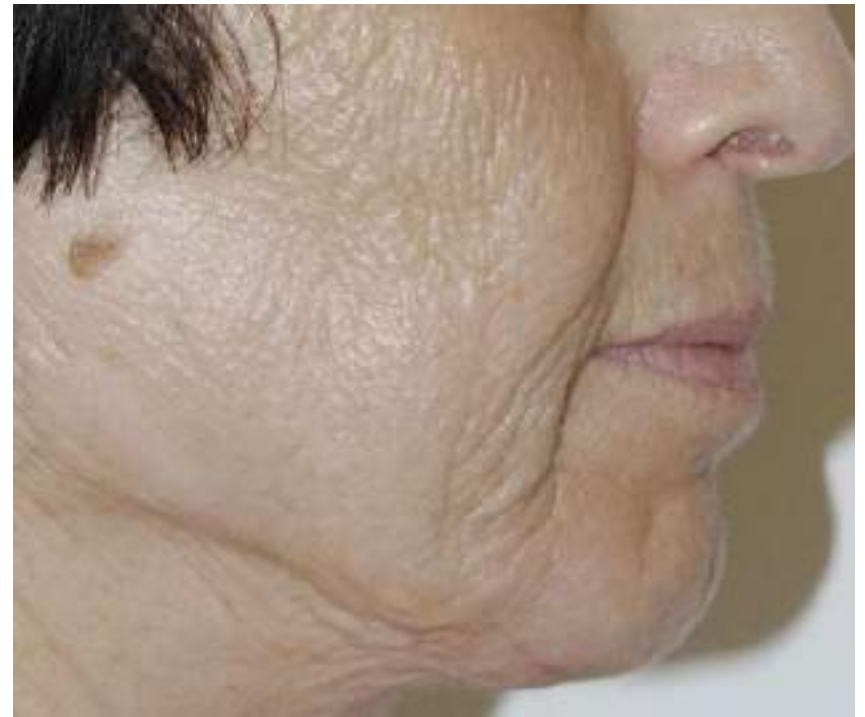Female, 67 years old

Number of Treatments

3 V-ST



Before

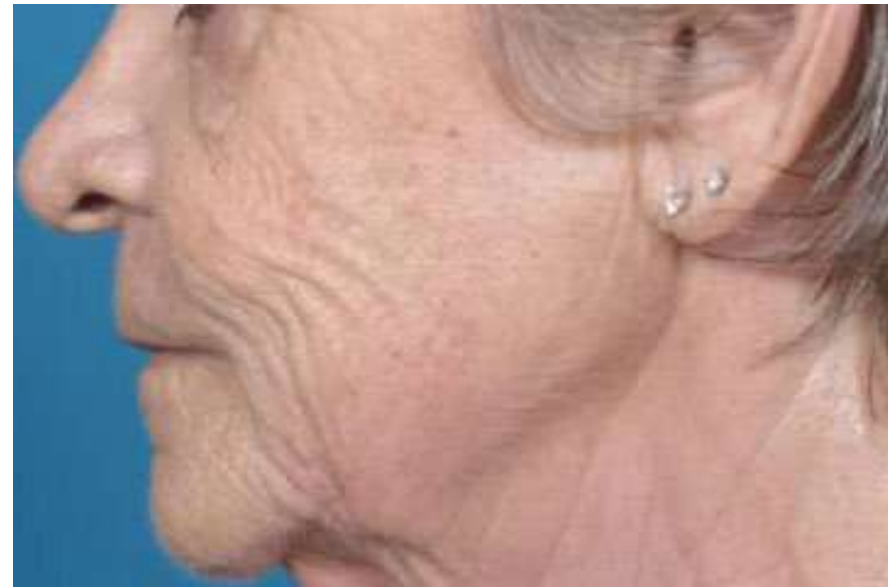
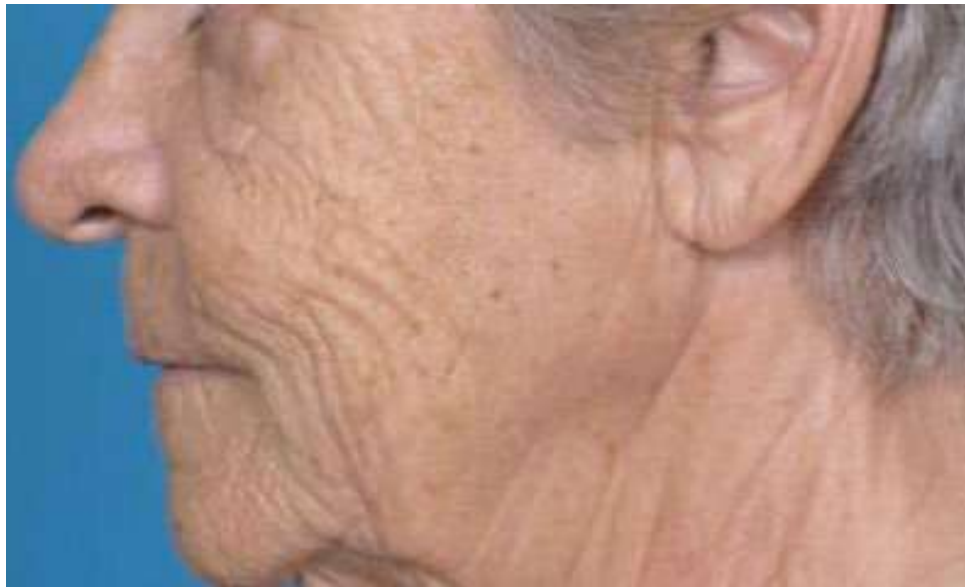
After



Sagging skin and wrinkles

Case Study – RE#355-B	Dr. Daniel Man, Boca Raton, Florida, USA
Patient	Female, 72 years old
Number of Treatments	9 V-ST



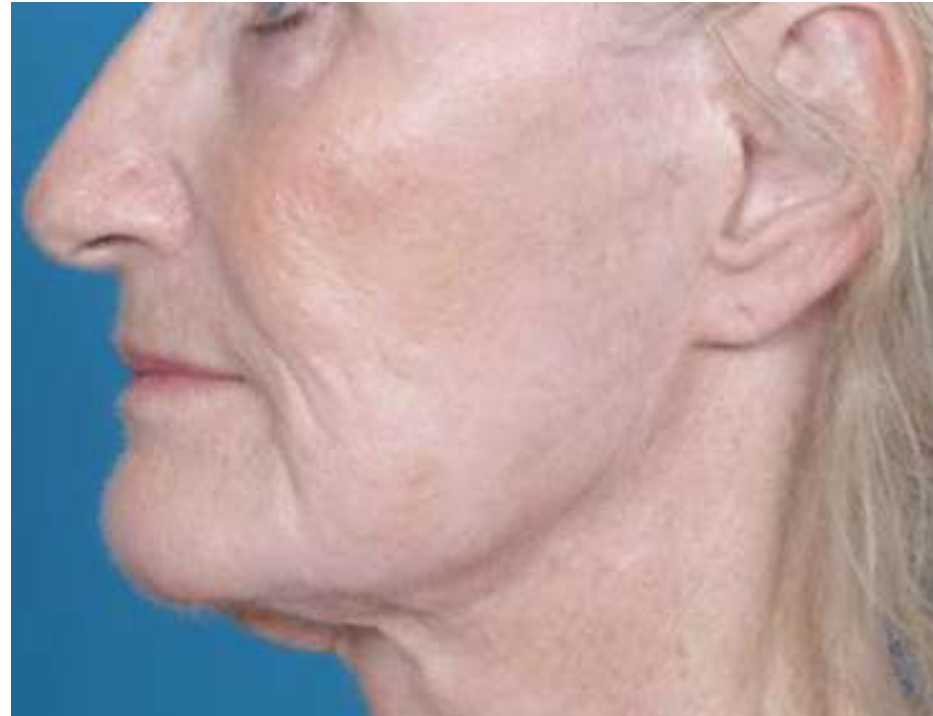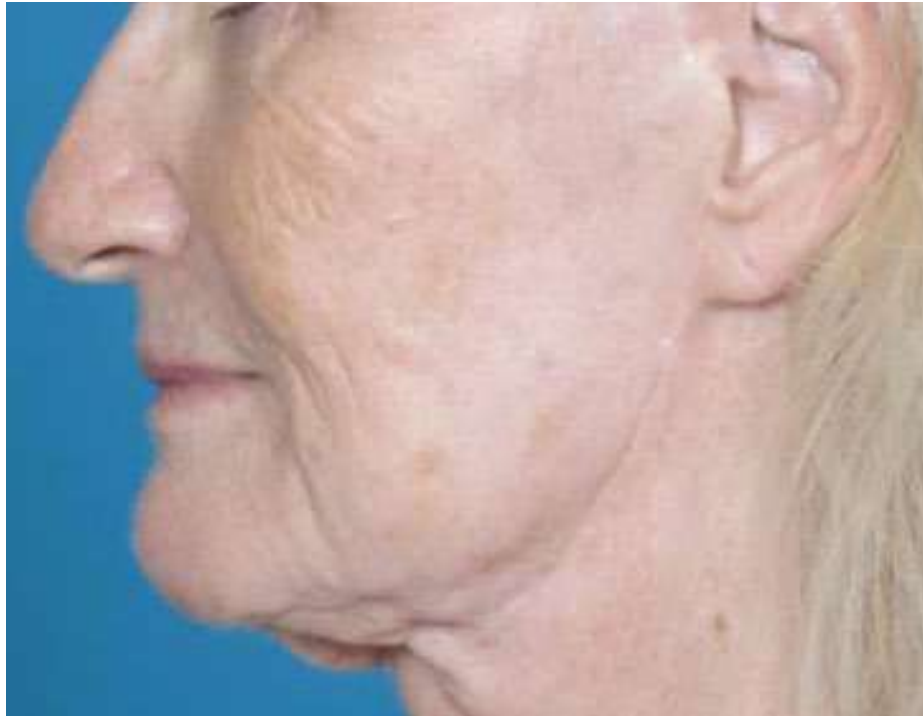Before

After



Sagging skin and wrinkles

Case Study – RE#356	Dr. Daniel Man, Boca Raton, Florida, USA
Patient	Female, 68 years old
Number of Treatments	9 V-ST



Before

After



Nasolabial Lines

Case Study – VST#001

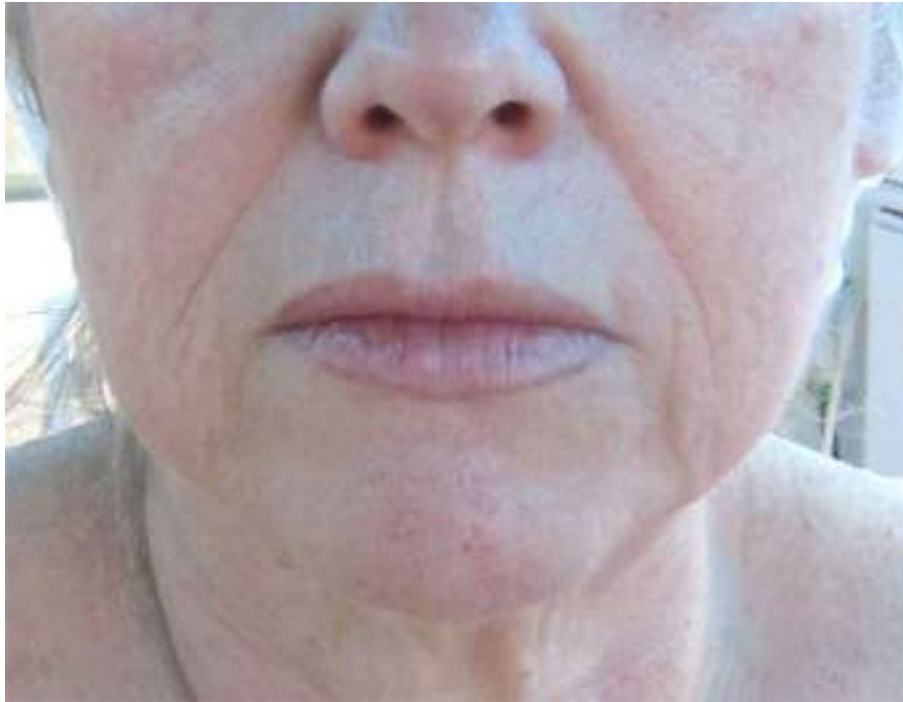Ronit Sade, Israel

Patient

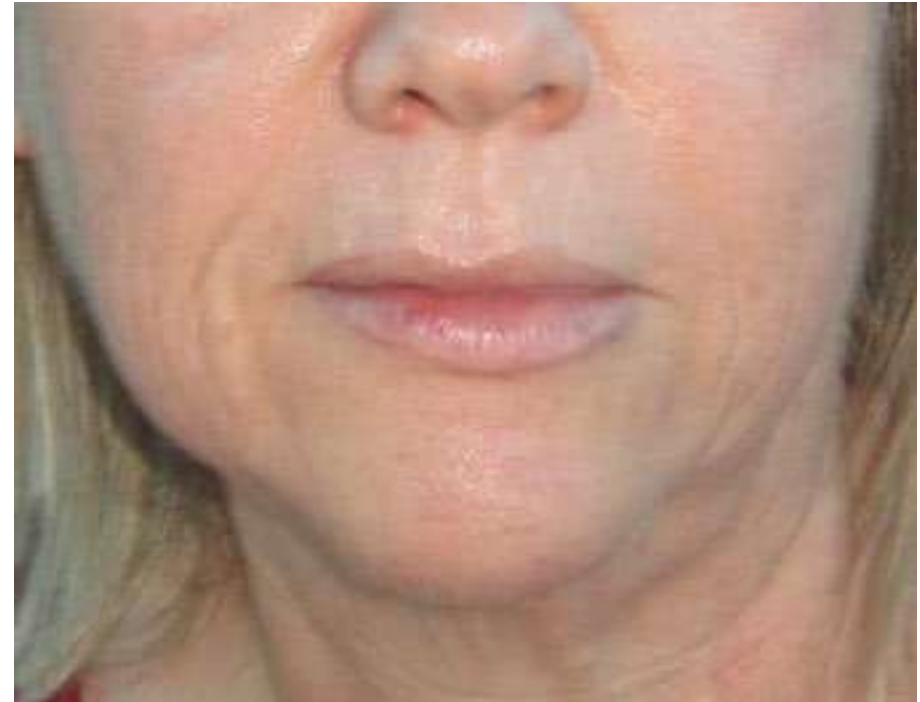Female

Number of Treatments

1 V-ST



Before



After



Nasolabial Lines

Case Study – VST#002

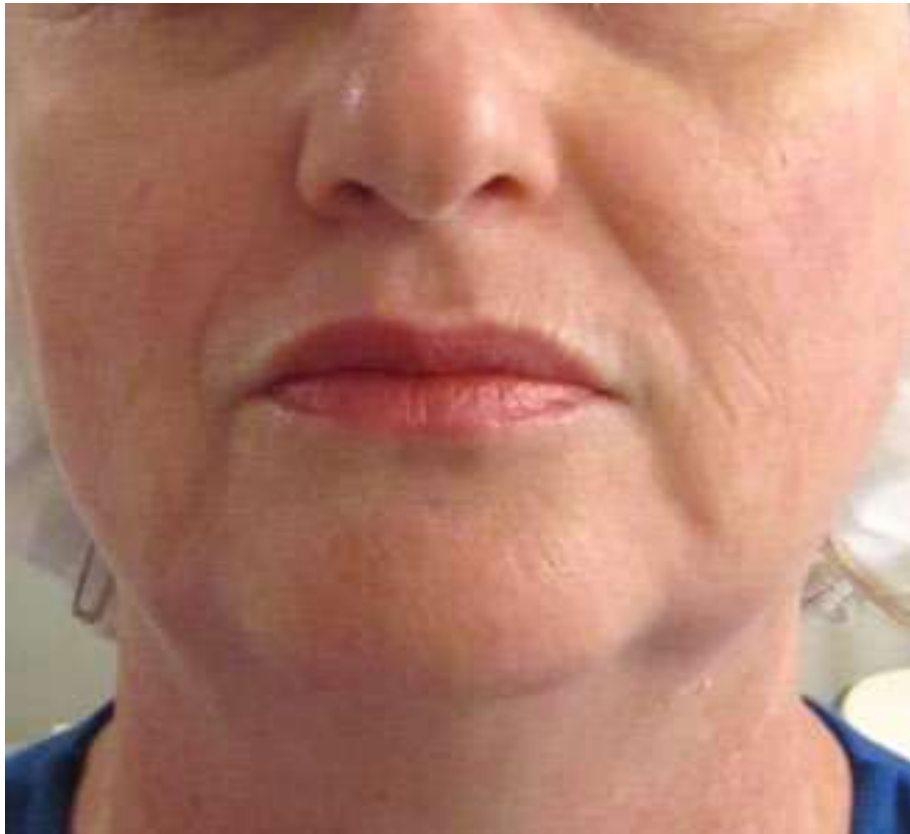Ronit Sade, Israel

Patient

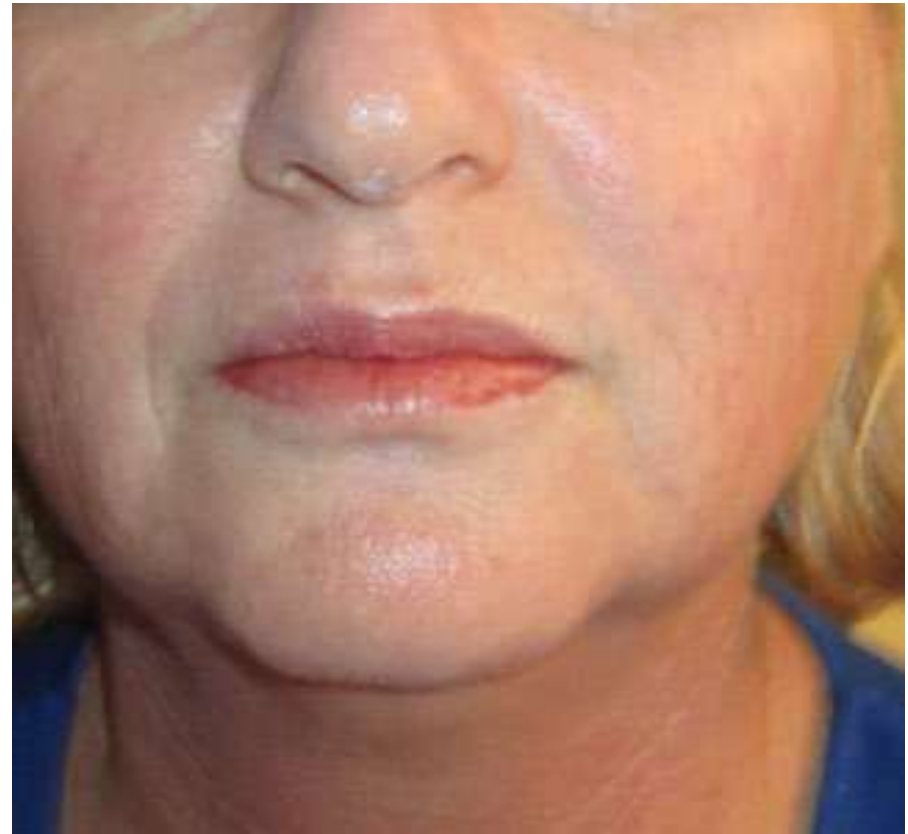Female

Number of Treatments

1 V-ST



Before



After



Lower face

Case Study – RE #381

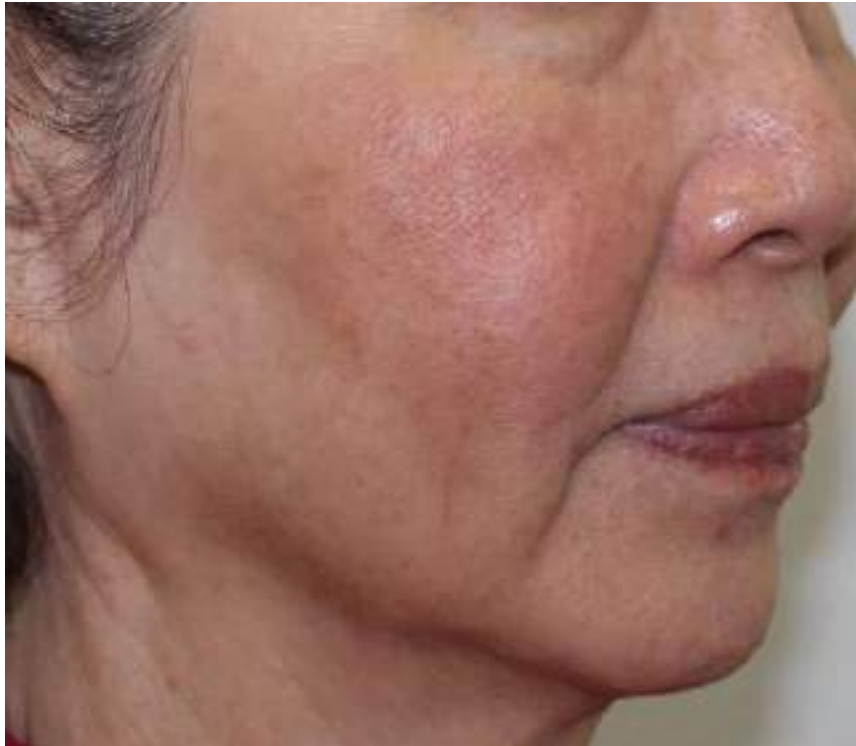TBMS Clinical Specialist, Taipei, Taiwan

Patient

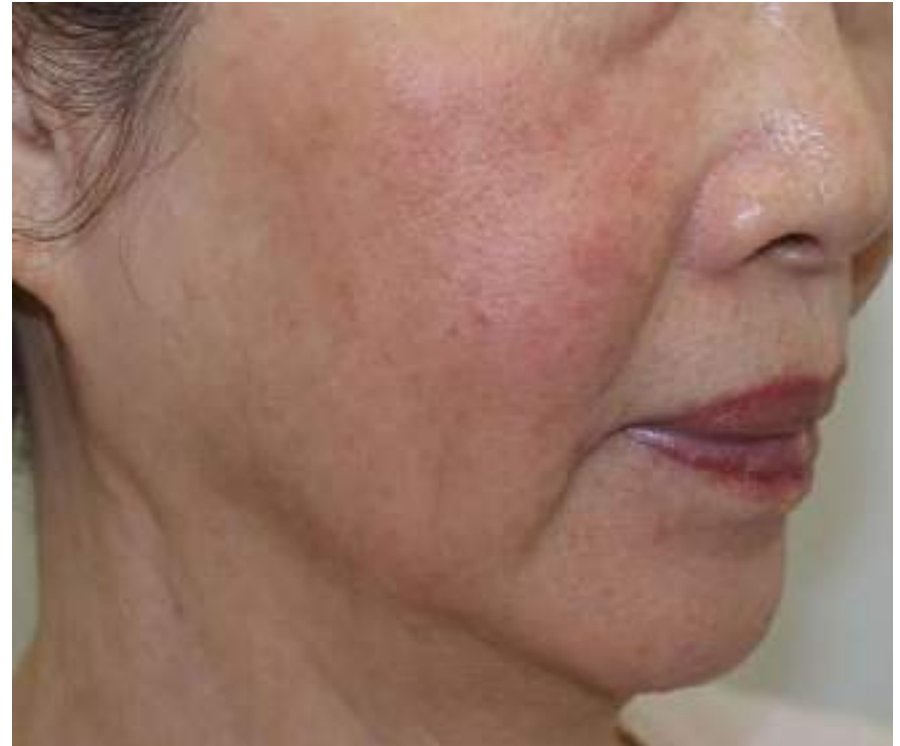Female, 70 years old

Number of Treatments

1 V-ST



Before

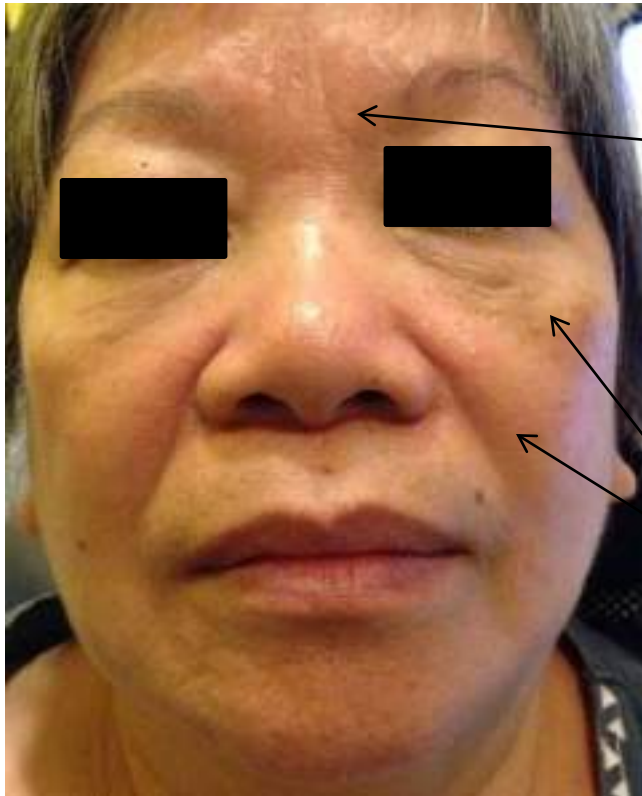

After 8 weeks

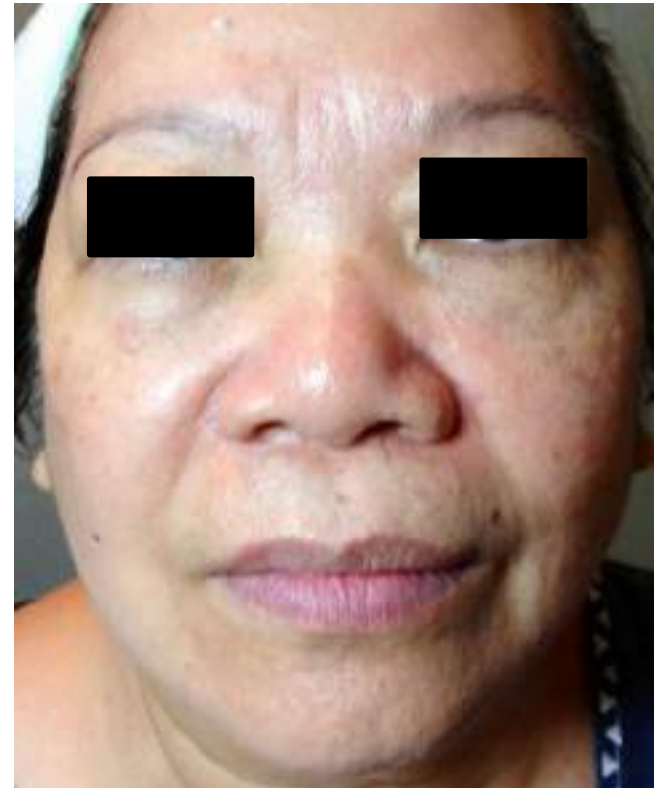

Face

Case Study – VST#007	Dr Kristine Cabel-Castaneda, Quezon City, Philippines
Patient	Female, 63 years old
Number of Treatments	1 V-ST



Before

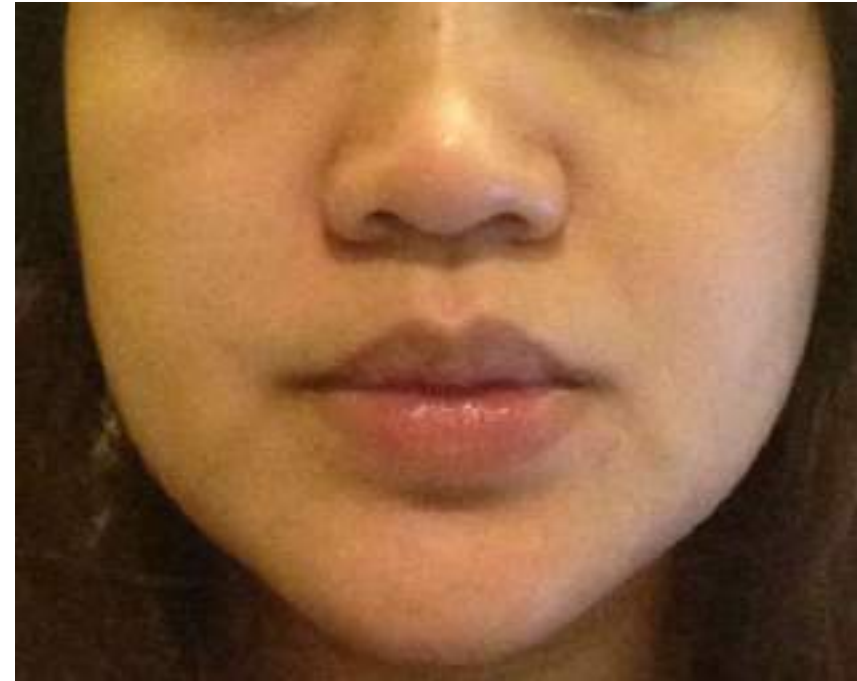
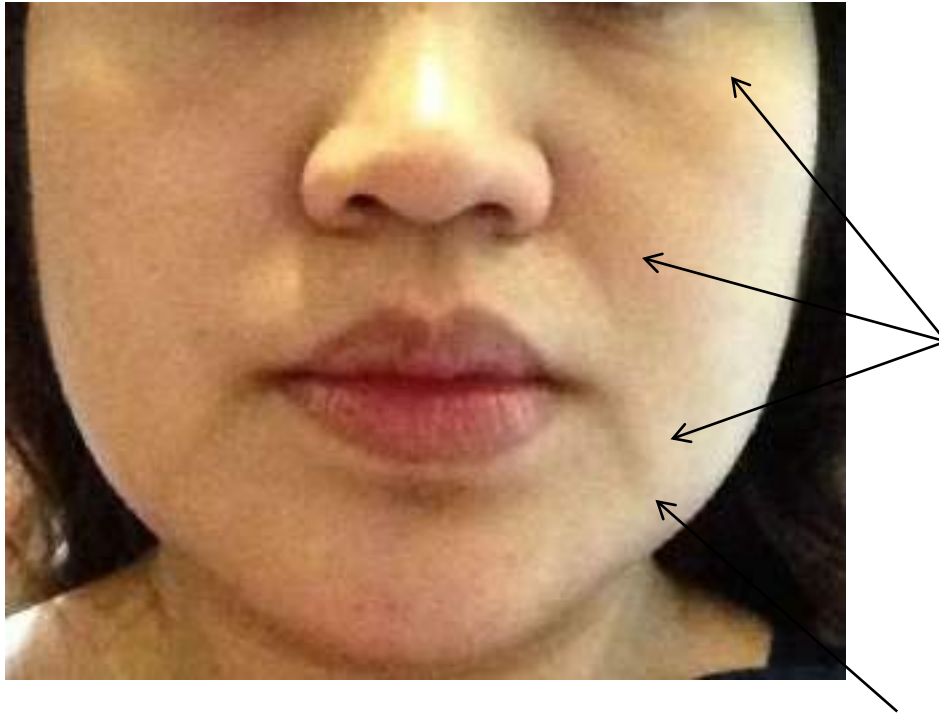
After



Face

Case Study – VST#008	Dr Kristine Cabel-Castaneda, Quezon City, Philippines
Patient	Female, 36 years old
Number of Treatments	1 V-ST



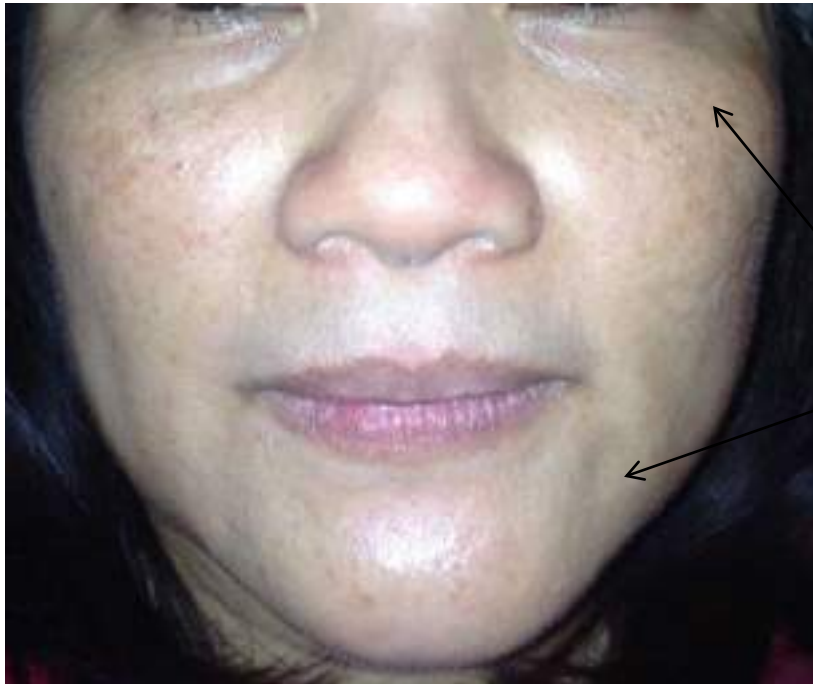Before

After

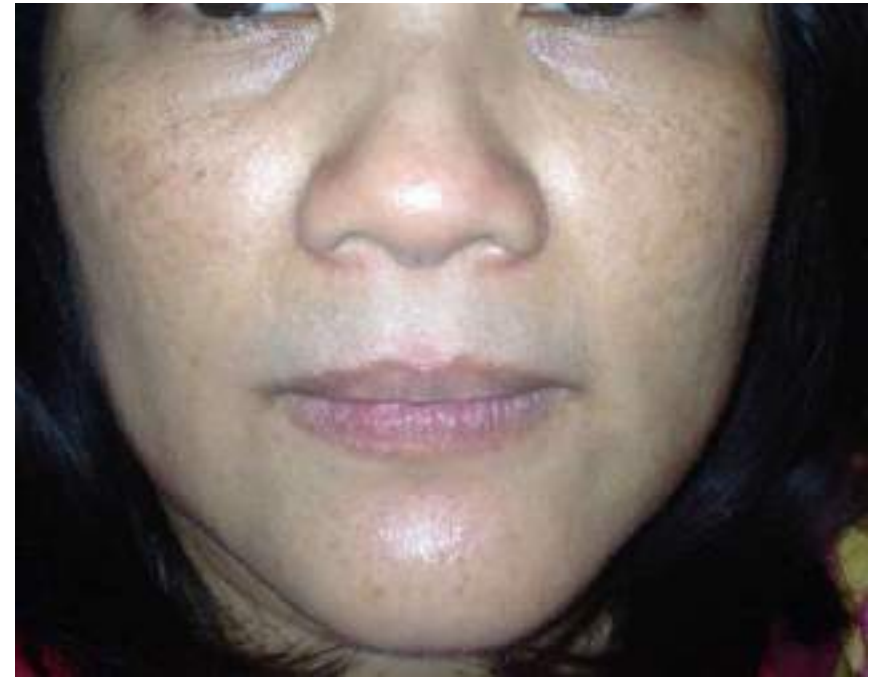

Face

Case Study – VST#009	Dr Kristine Cabel-Castaneda, Quezon City, Philippines
Patient	Female, 53 years old
Number of Treatments	1 V-ST



Before

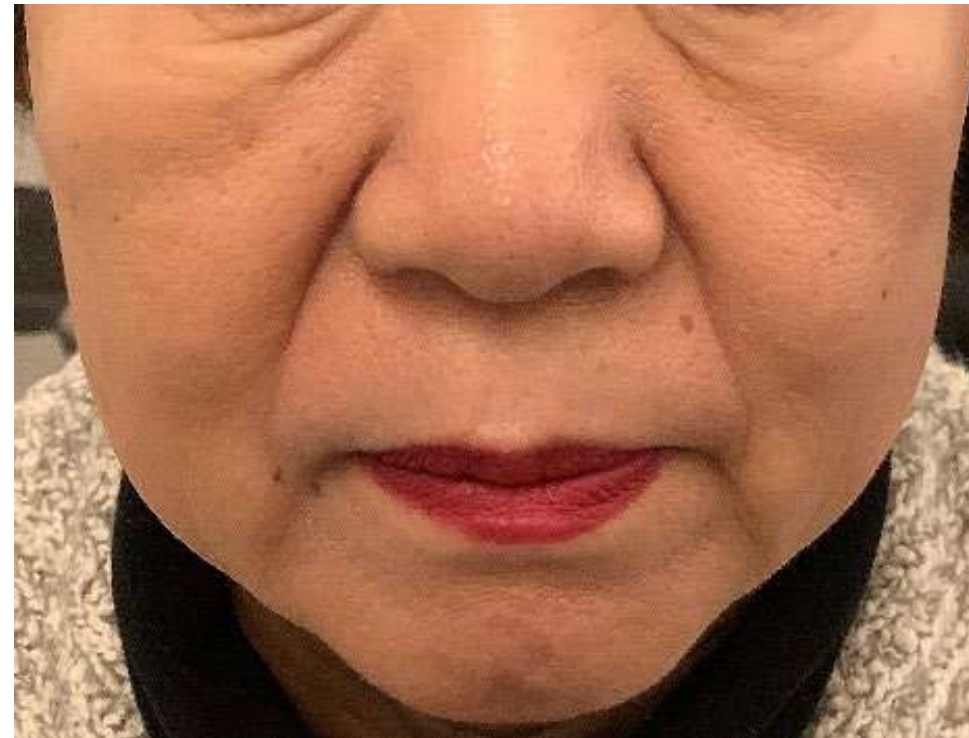

After

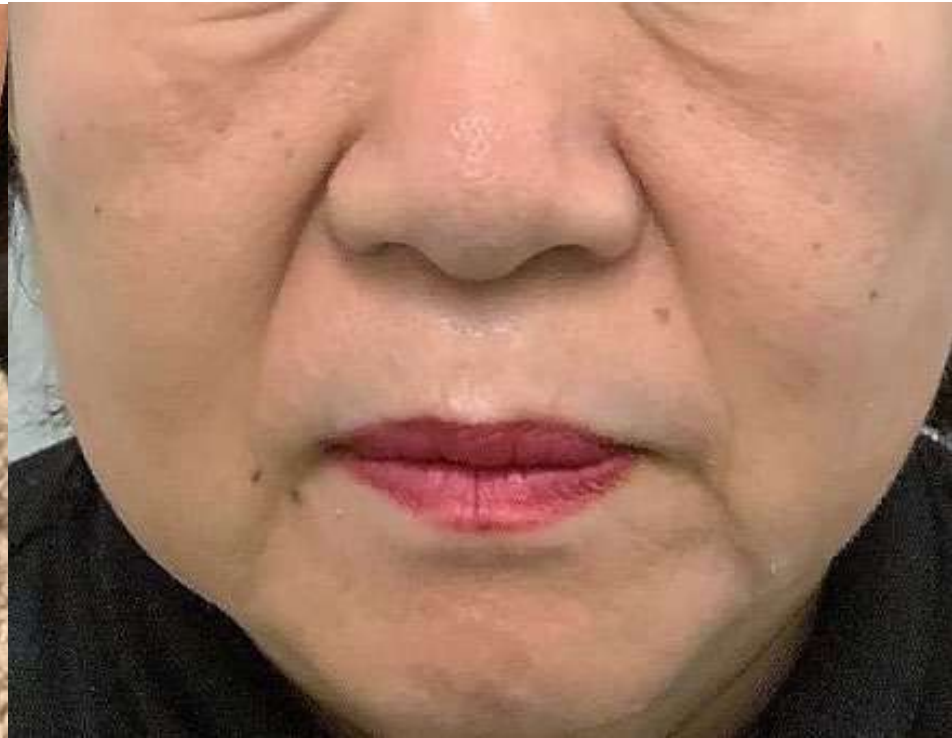

Face

Case Study – VST#036-A	Viora, Inc. USA
Patient	Female, 66 Years old
Number of Treatments	2 V-ST



Before

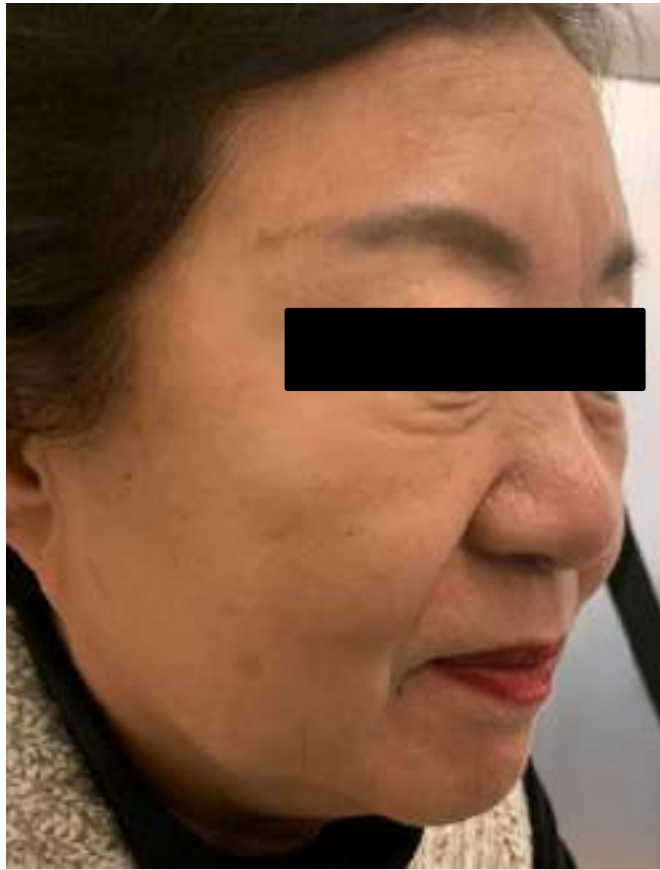

After

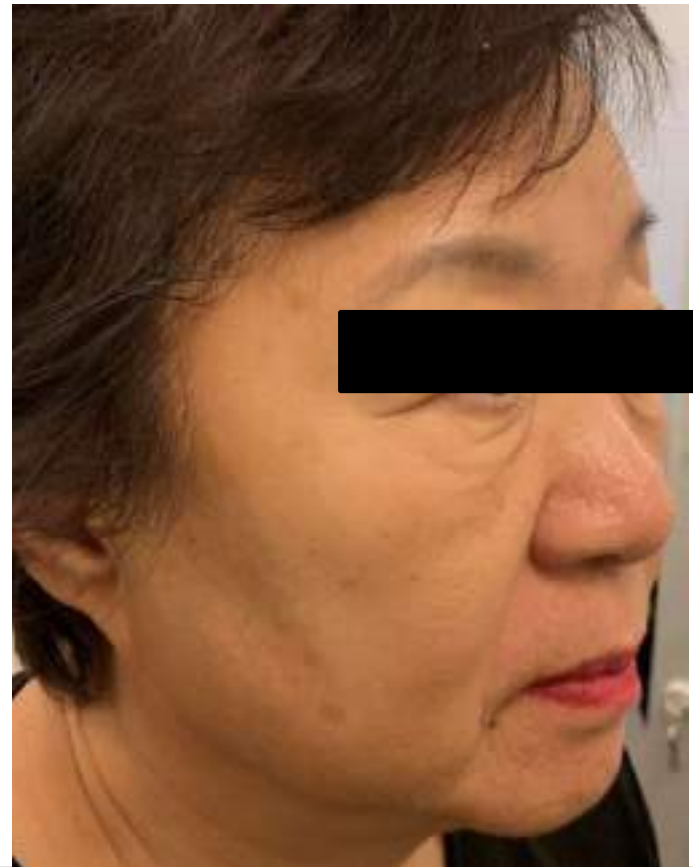

Face

Case Study – VST#036-B	Viora, Inc. USA
Patient	Female, 66 Years old
Number of Treatments	4 V-ST



Before

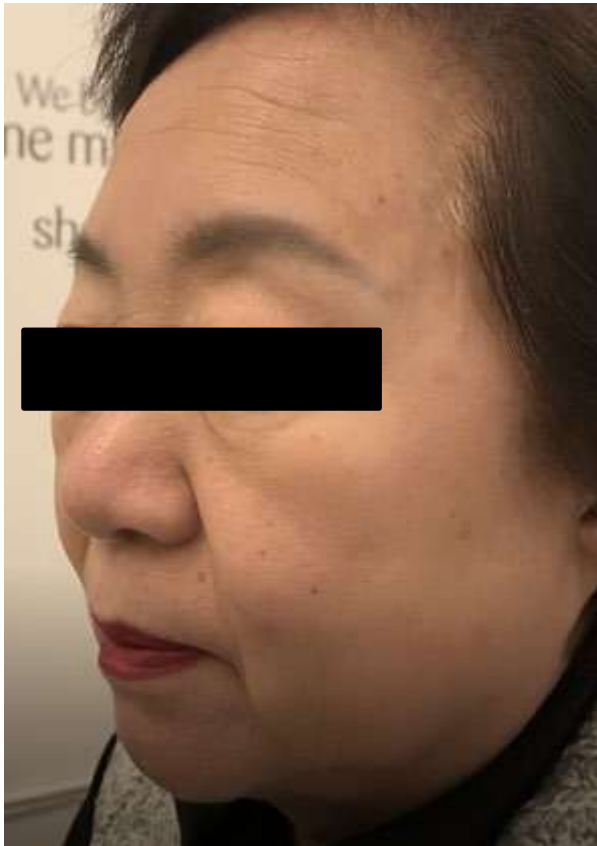

After

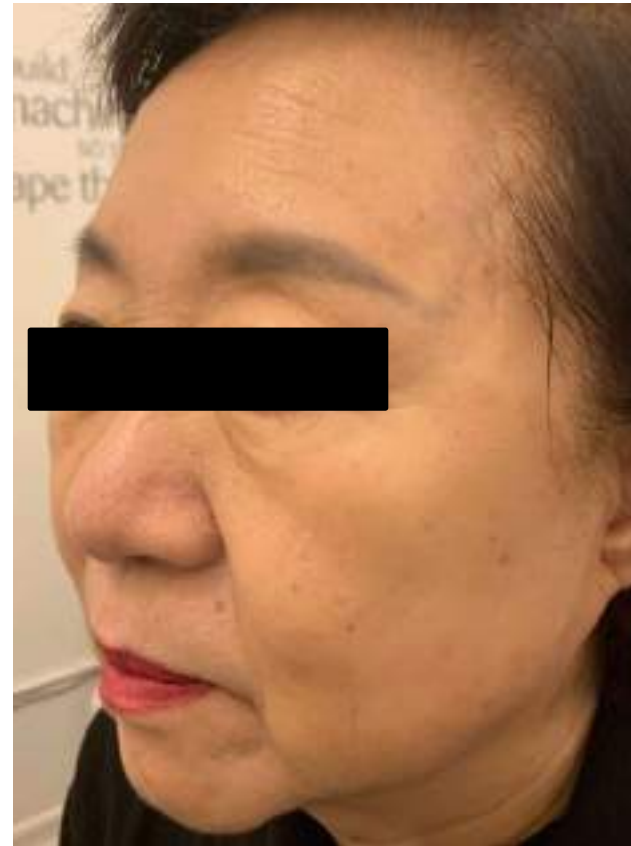

Face

Case Study – VST#036-C	Viora, Inc. USA
Patient	Female, 66 Years old
Number of Treatments	2 V-ST



Before



After

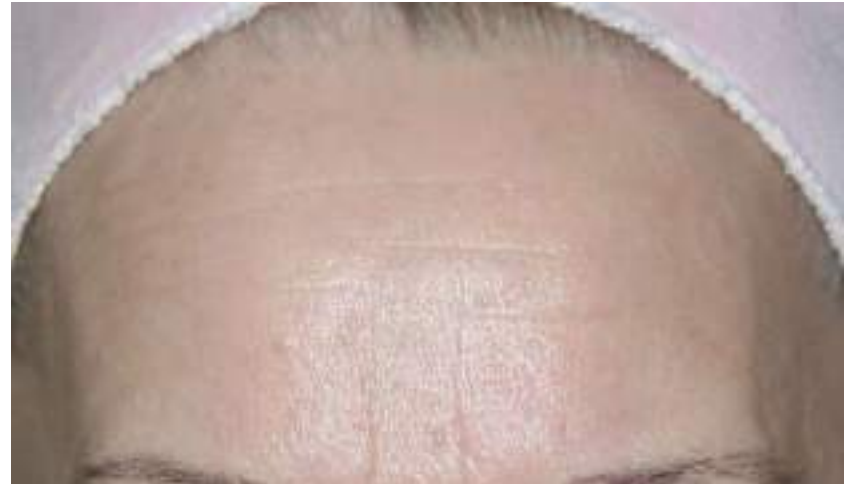
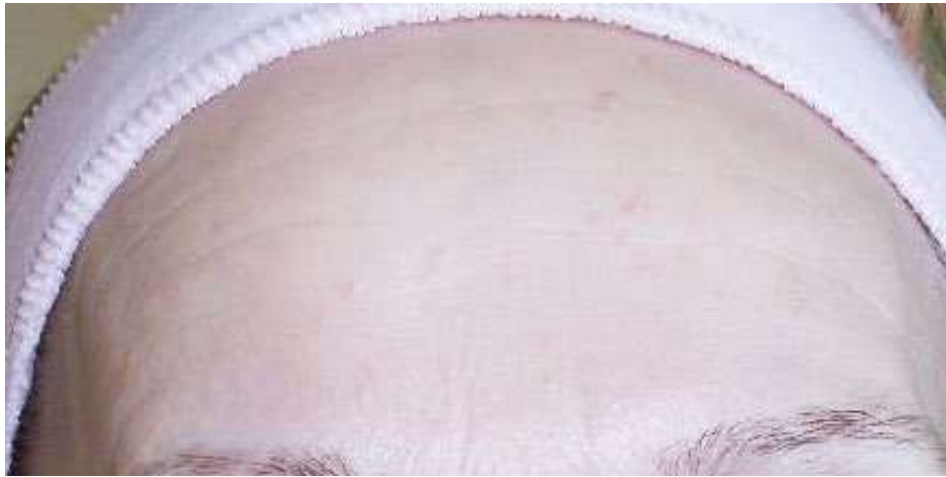
Forehead


VIORA

Forehead

Case Study – RE #176-A	Dr. Marina Vashkevich, Grodno, Belarus
Patient	Female, 58 years old
Number of Treatments	3 V-ST



Before

6 Months Follow-up



Face

Case Study – RE#344-B

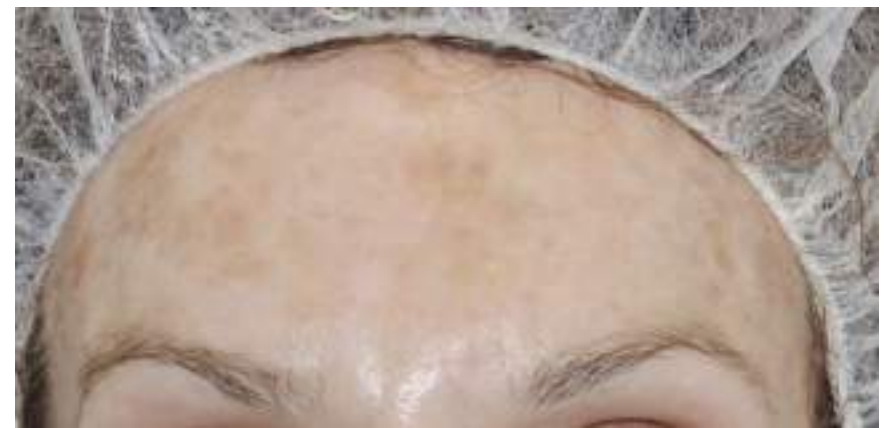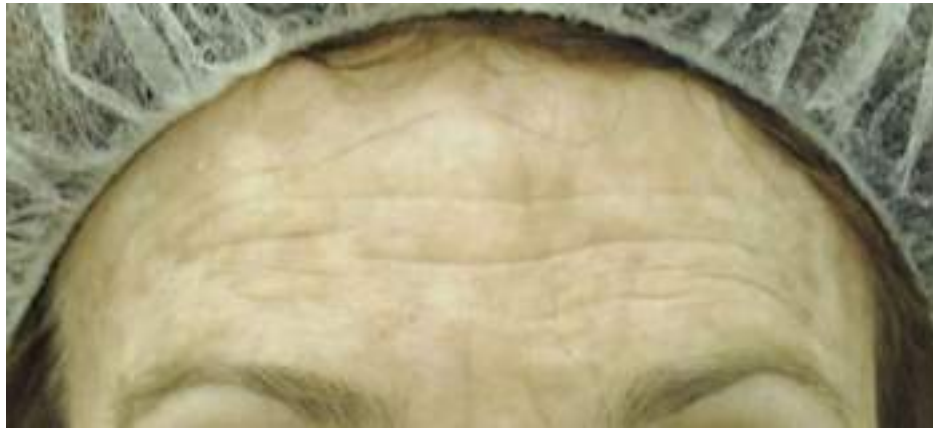Dr Monica Elman, Beit Harofim Medical Center, Israel

Patient

Female, 64 years old

Number of Treatments

3 V-ST



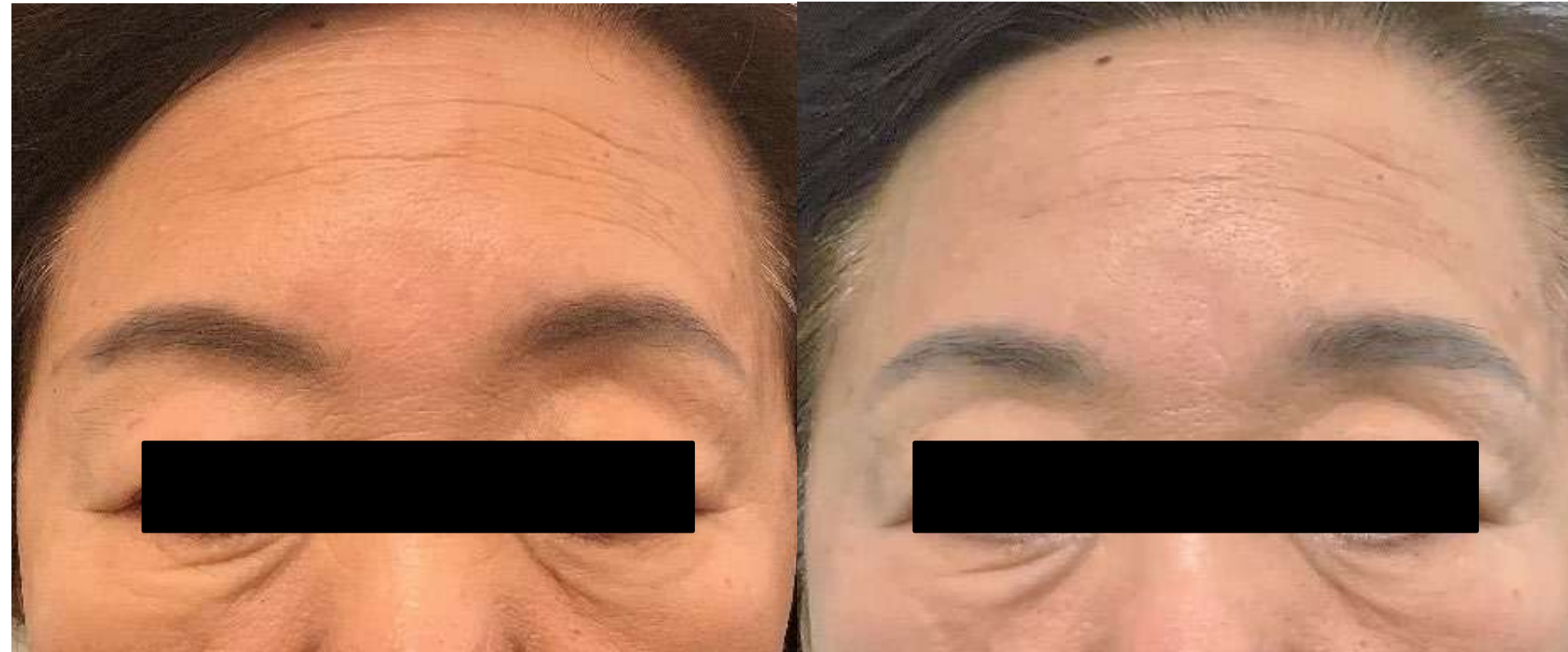Before

After



Forehead & Eyes

Case Study – VST#036-B	Viora, Inc. USA
Patient	Female, 66 Years old
Number of Treatments	2 V-ST



Before

After



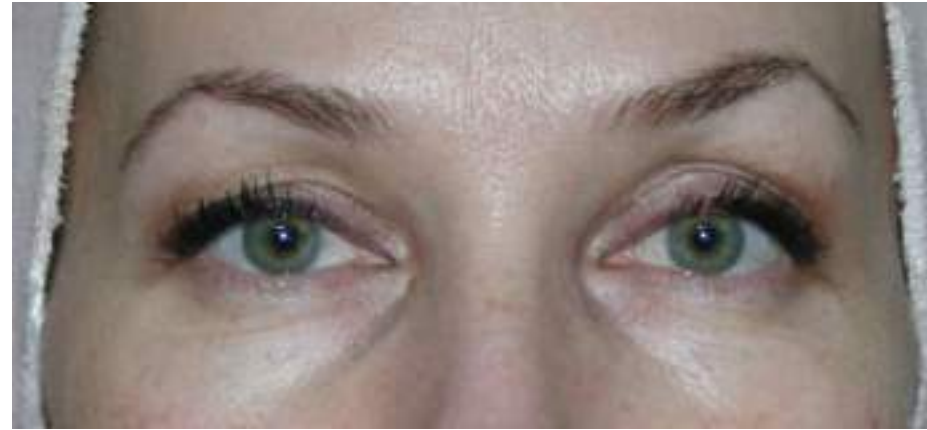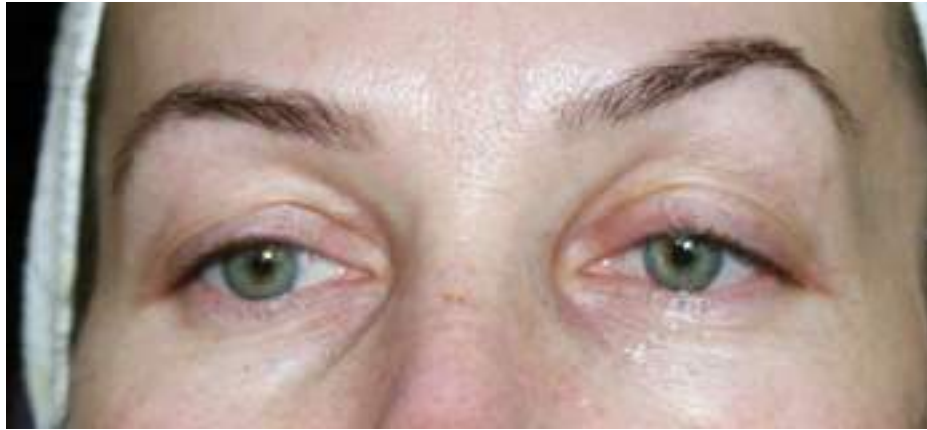Eyes


VIORA



Eyes

Case Study – RE #177	Dr. Marina Vashkevich, Grodno, Belarus
Patient	Female, 42 years old
Number of Treatments	6 V-ST



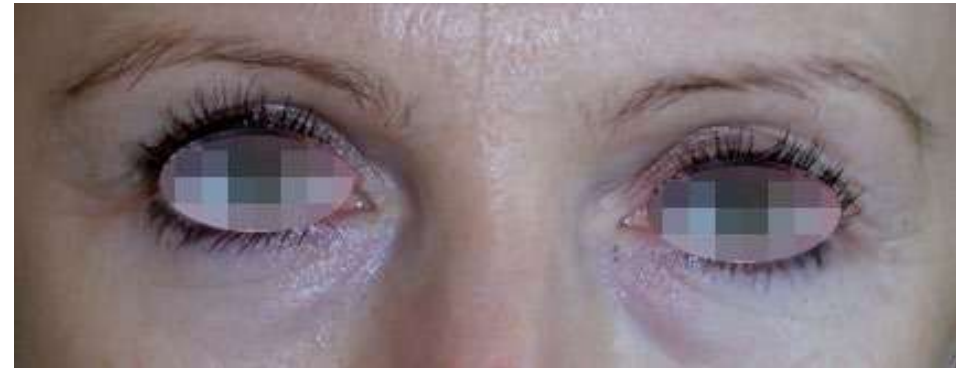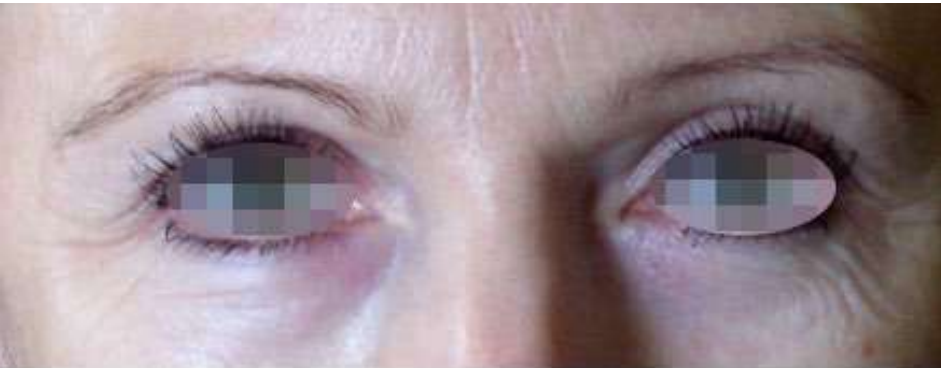
Before

After



Eyes

Case Study – RE#178	Dr. Marina Vashkevich, Canada
Patient	Female, 53 years old
Number of Treatments	1 V-ST



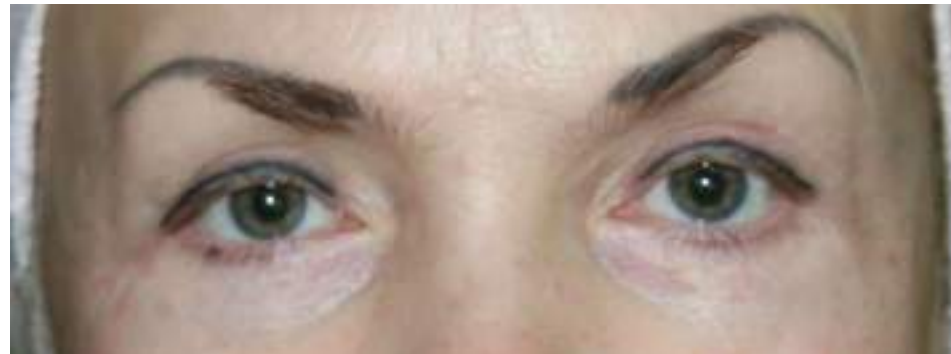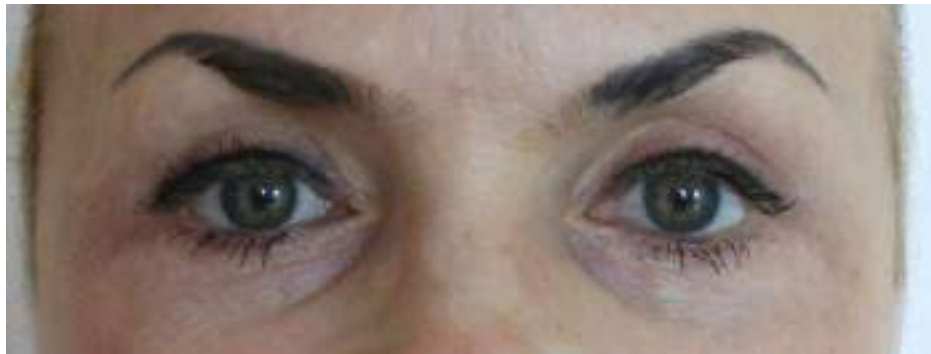Before

After



Forehead

Case Study – RE #180-A	Dr. Marina Vashkevich, Grodno, Belarus
Patient	Female, 42 years old
Number of Treatments	5 V-ST



Before

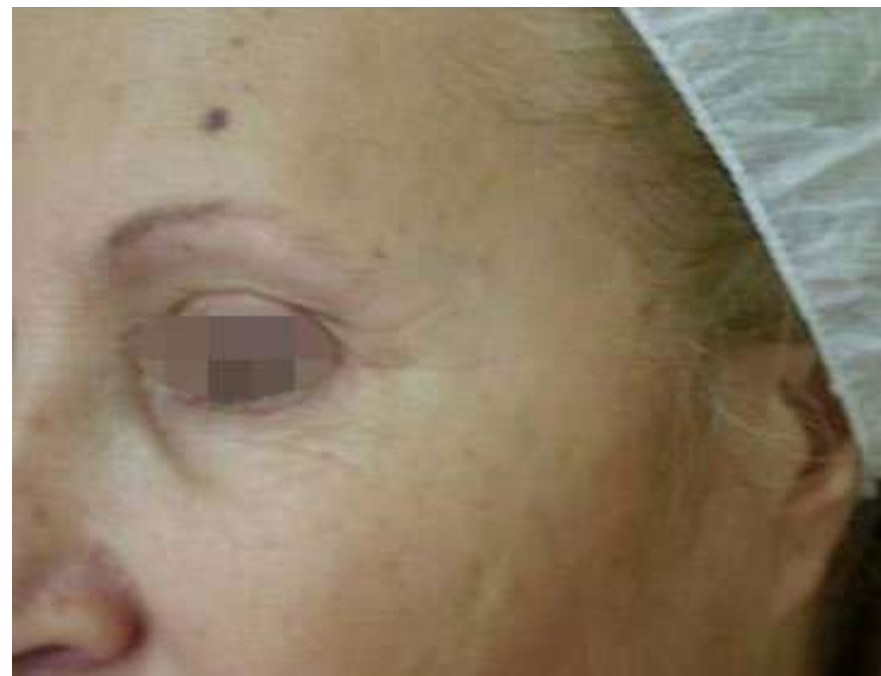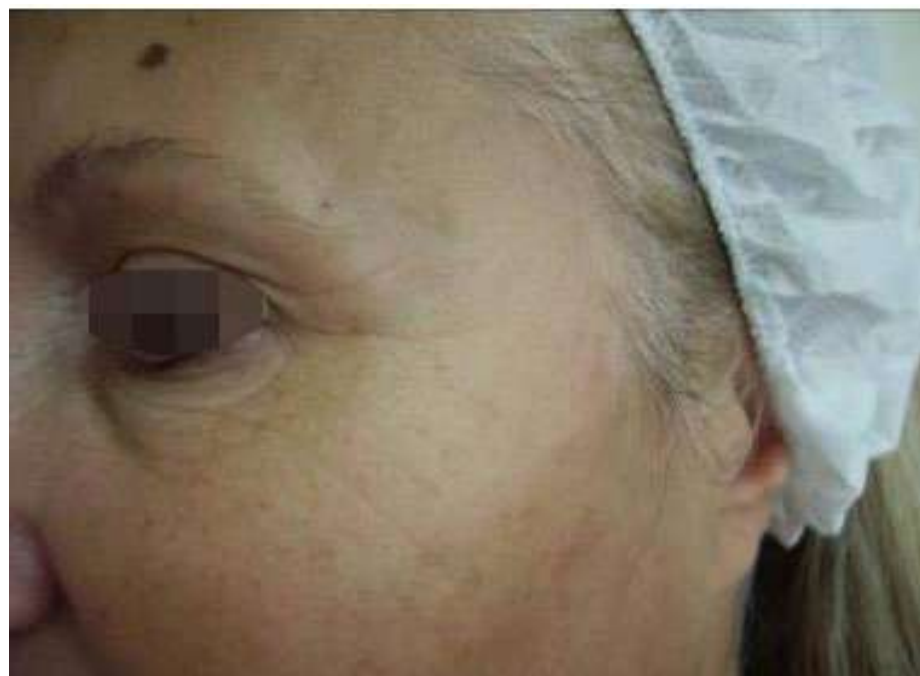After





Crow's Feet

Case Study – RE #119	Keren Or Medical Aesthetic Center, Israel
Patient	Female, 55 years old
Number of Treatments	4 V-ST



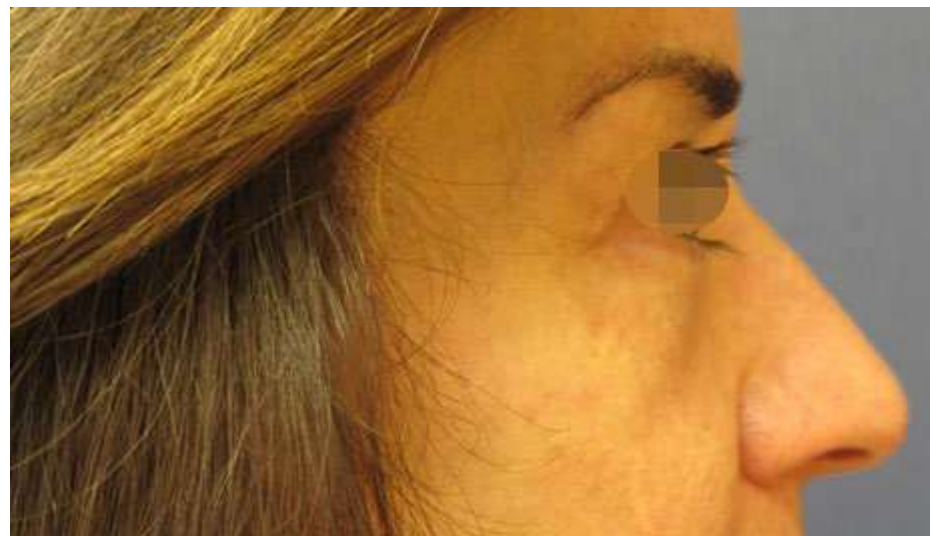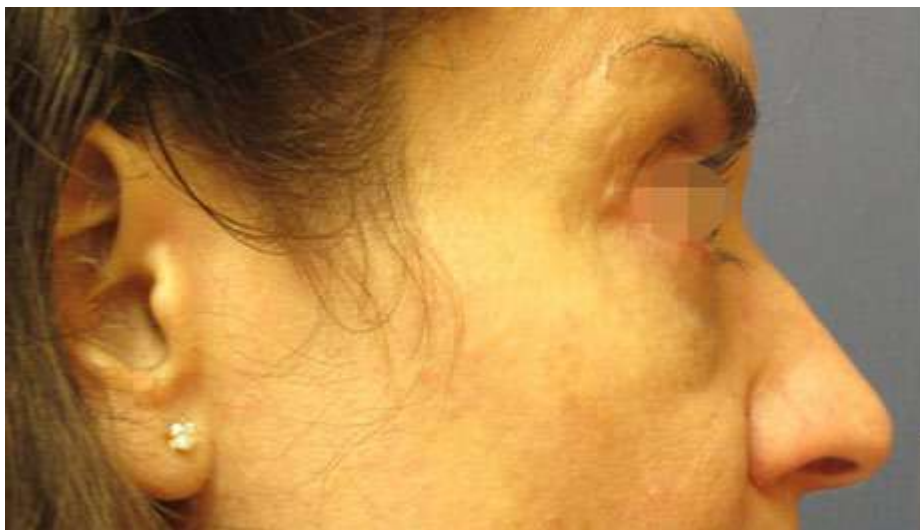
Before

After



Eyes

Case Study – RE#291	Dr. Aaron Shapiro & Richard Goldfarb, PA, USA
Patient	Female, 50 years old
Number of Treatments	5 V-ST



Before

After



Eyes

Case Study – RE#298

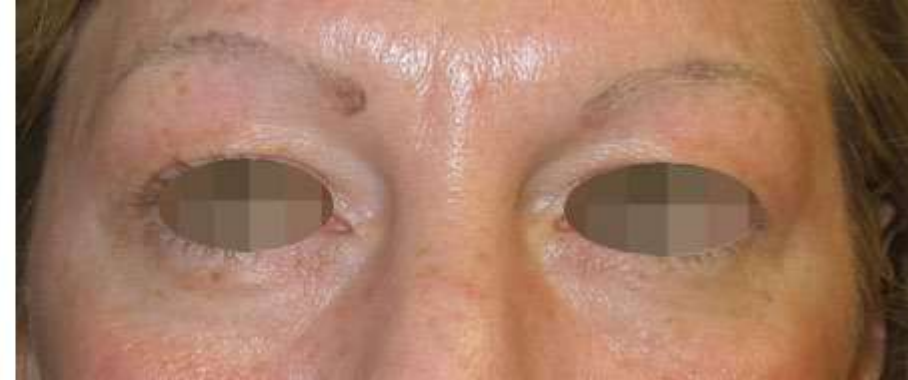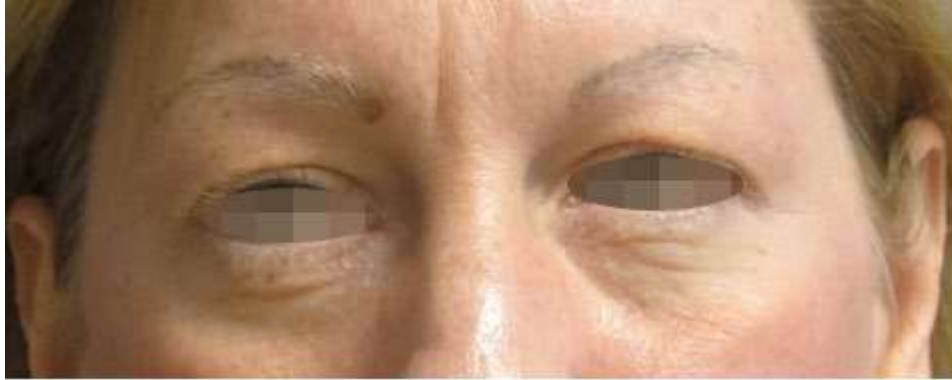Dr Robert Jackson (by Amber Aimen), Fishers, IN, USA

Patient

Female, 46 years old

Number of Treatments

1 V-ST



Before

After



Eyes

Case Study – RE#292

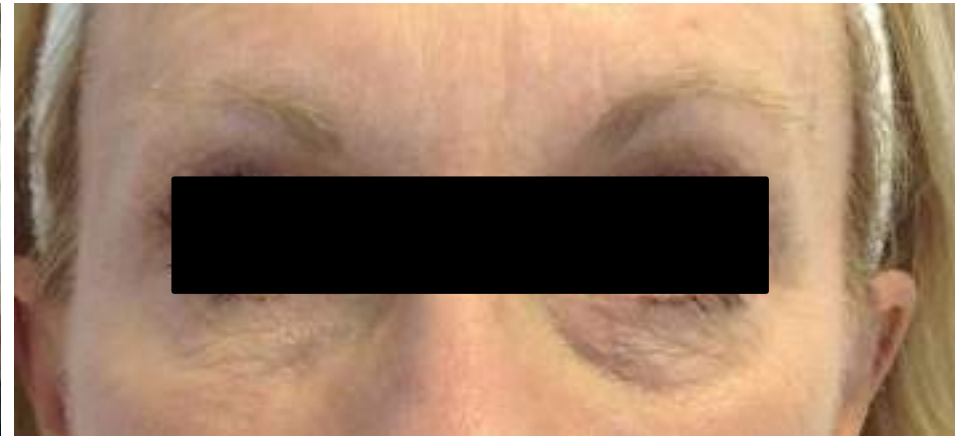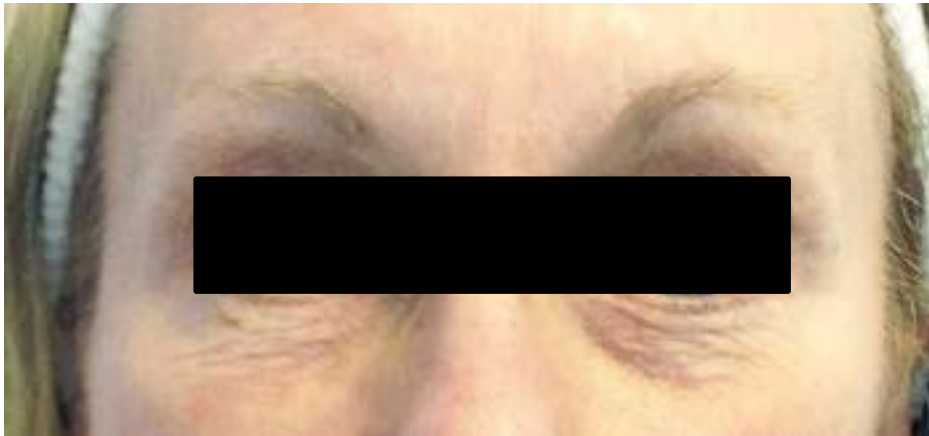Dr. Nicole Hayre, VA, USA

Patient

Female

Number of Treatments

2 V-ST



Before

After



Eyes

Case Study – RE#304

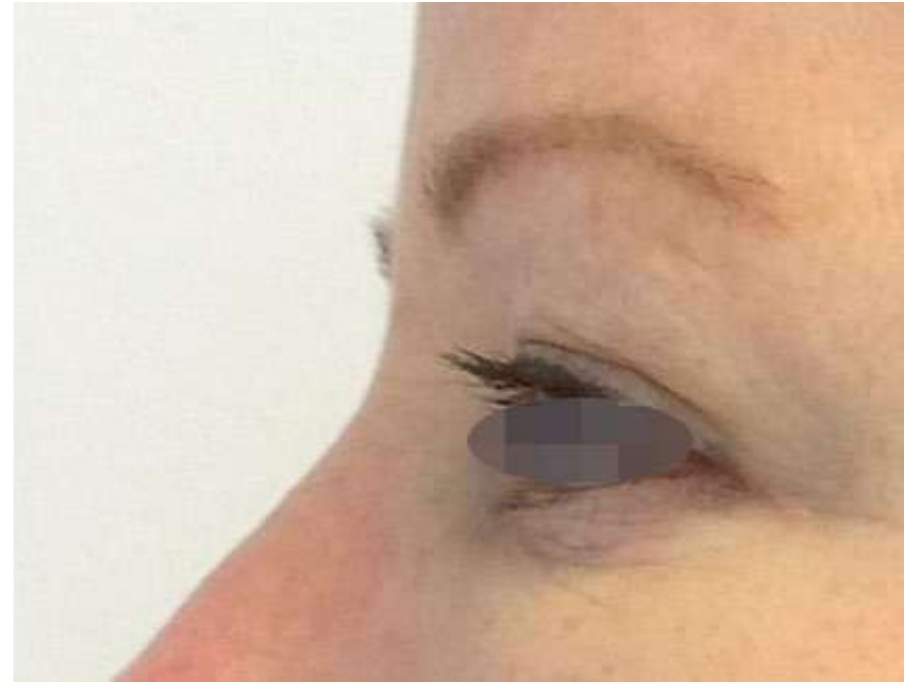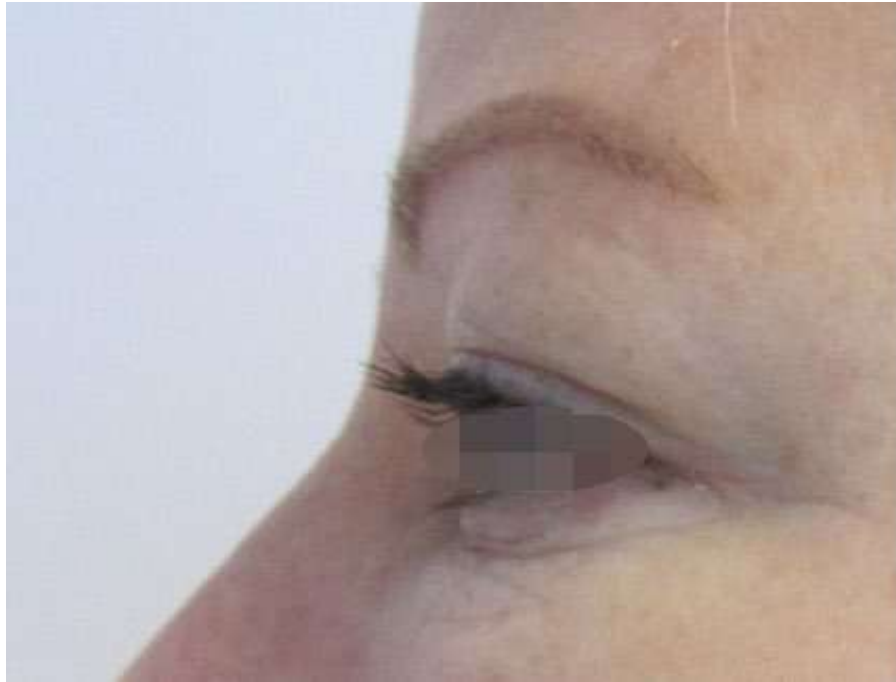Dr. Nicole Hayre, VA, USA

Patient

Female, 47 years old

Number of Treatments

1 V-ST



Before

After



Eyes

Case Study – RE#305

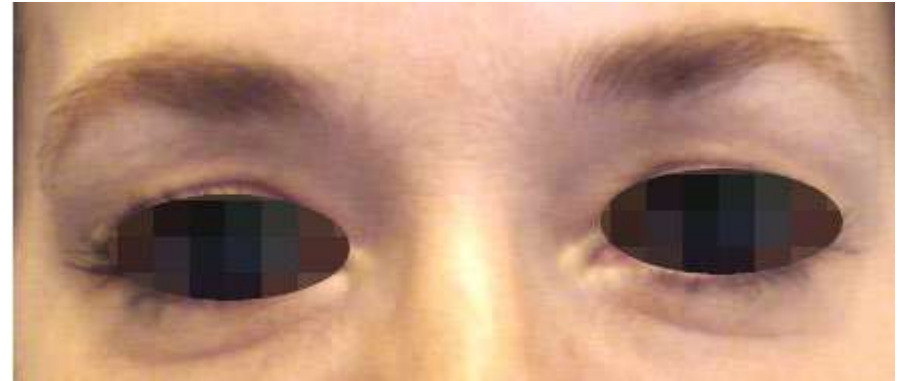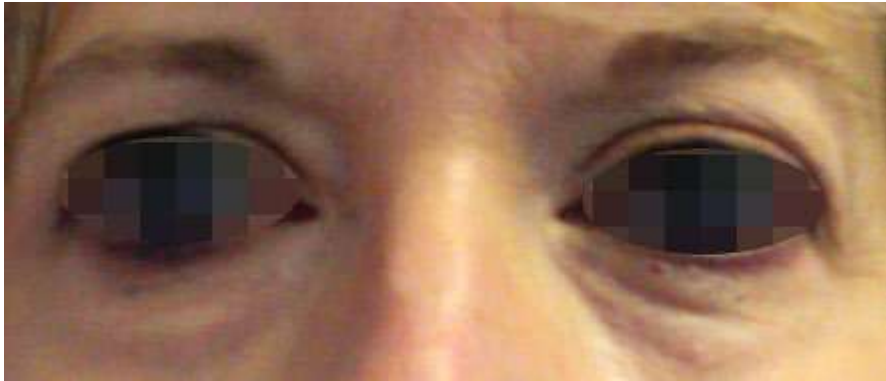Dr. Nicole Hayre, VA, USA

Patient

Female

Number of Treatments

3 V-ST



Before

After



Eyes

Case Study – RE#354

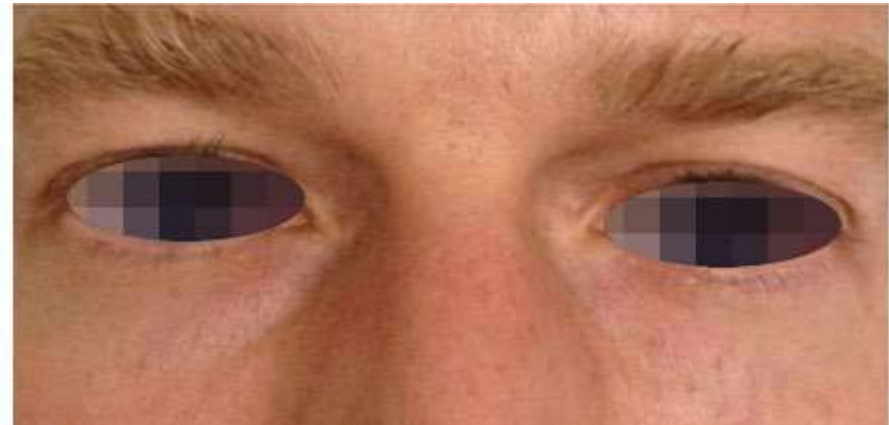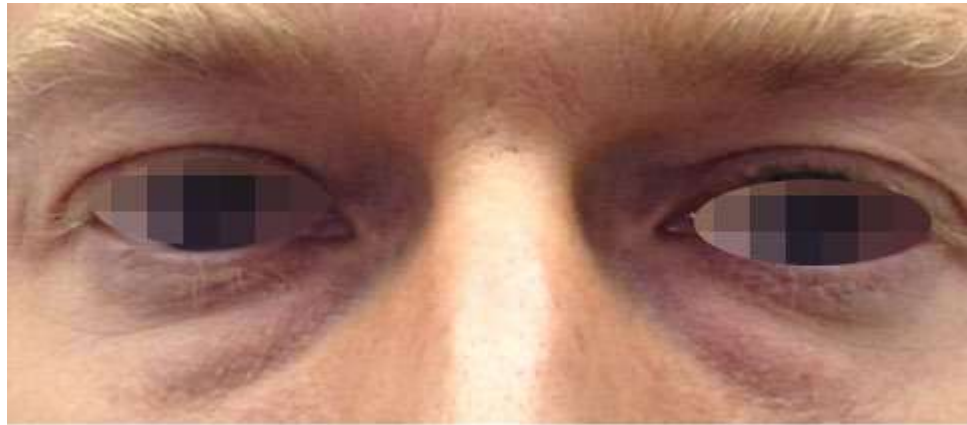Viora Inc., USA

Patient

Male, 35 years old

Number of Treatments

4 V-ST



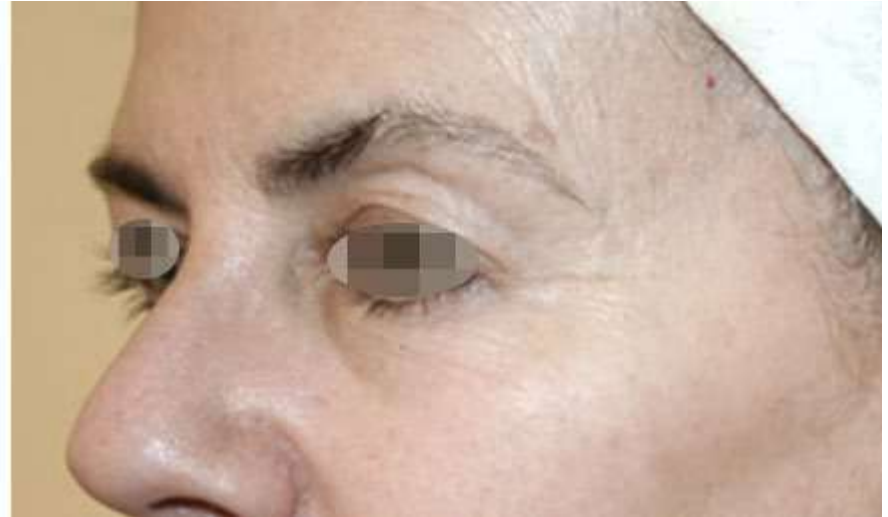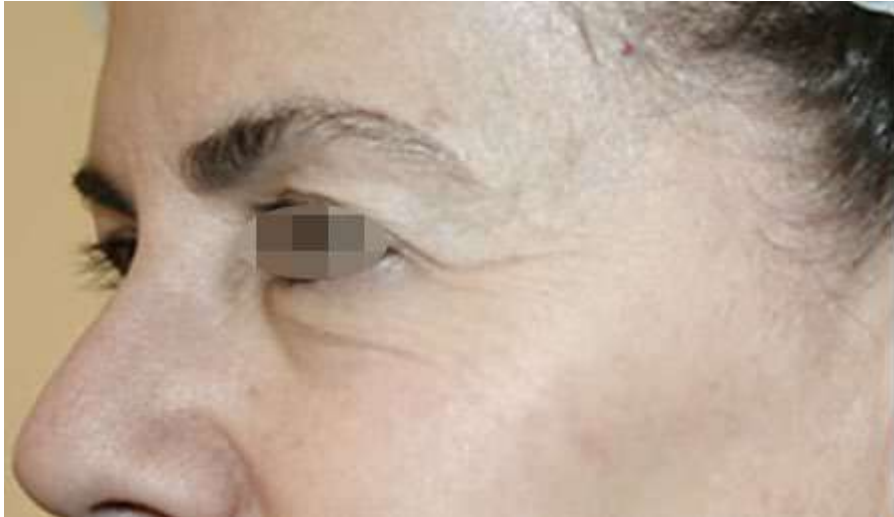Before

After



Eyes

Case Study – RE#315-B	Dr. Marina Vashkevich, Toronto, Canada
Patient	Female, 64 years old
Number of Treatments	5 V-ST



Before

After



Eyes

Case Study – RE#361

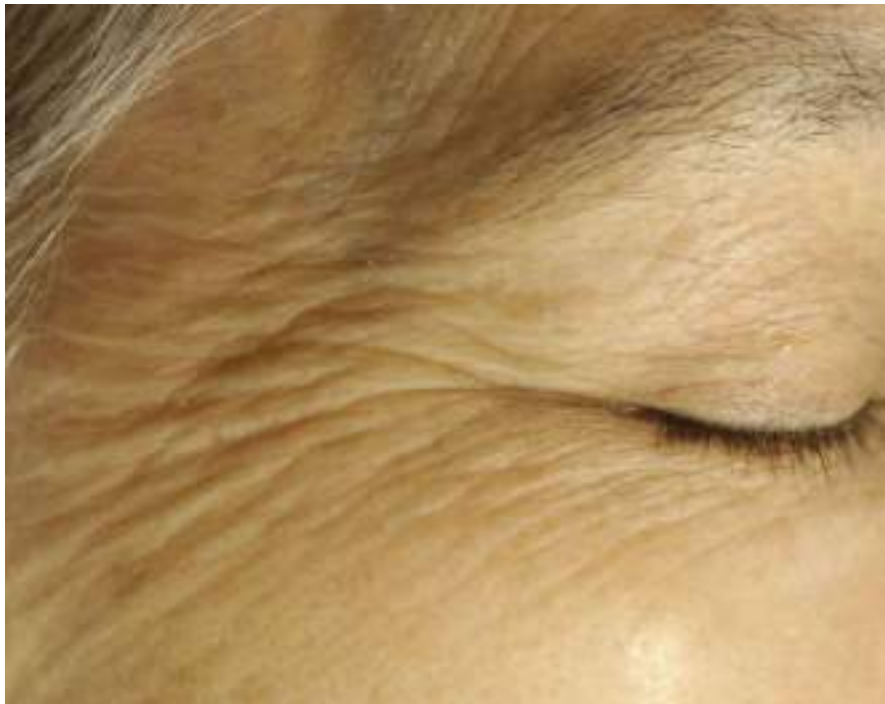TBMS Clinical Specialist, Taipei, Taiwan

Patient

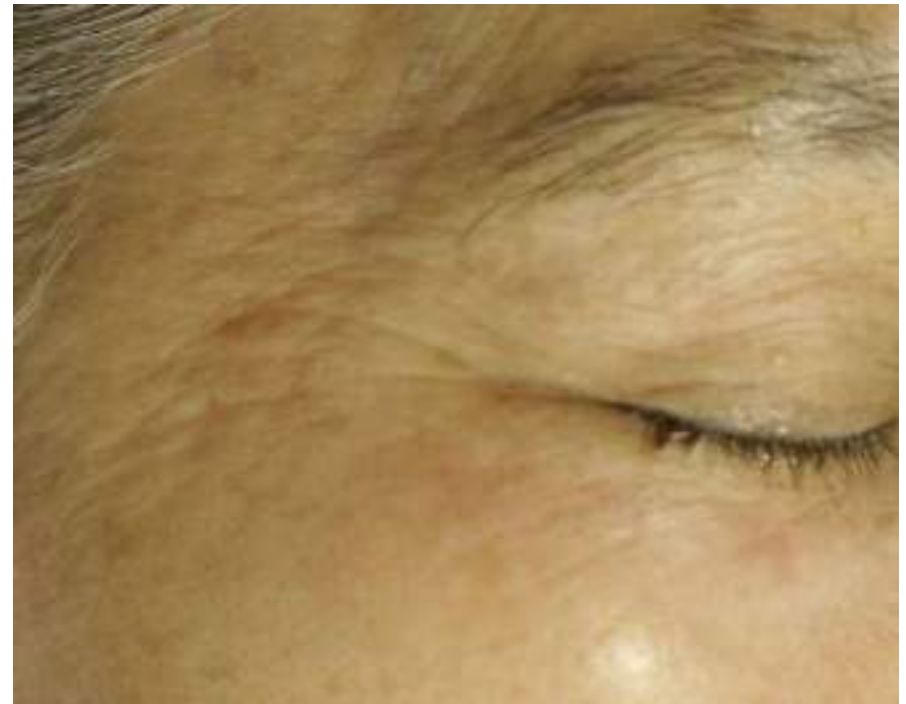Female, 40 years old

Number of Treatments

2 V-ST (Mode III, 76 J/cm³, 5 passes)



Before



After



Eyes

Case Study – RE#368

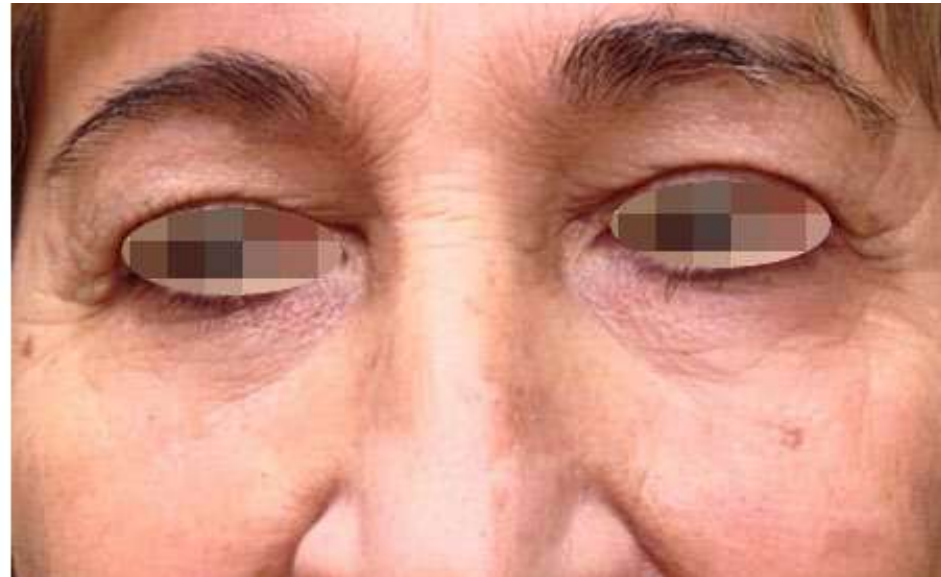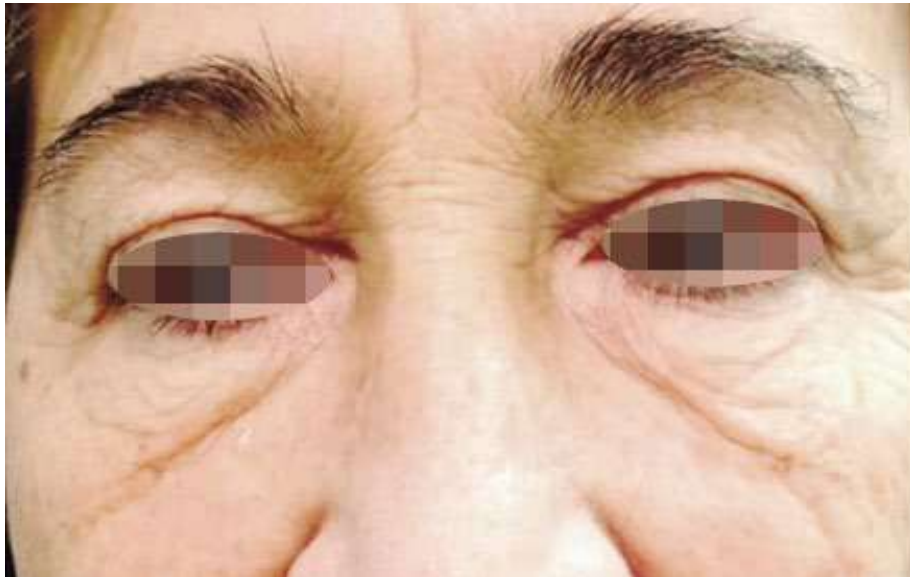Wow Me LLC, CO, USA

Patient

Female, 69 years old

Number of Treatments

8 V-ST



Before

After



Eyes

Case Study – RE#316-A

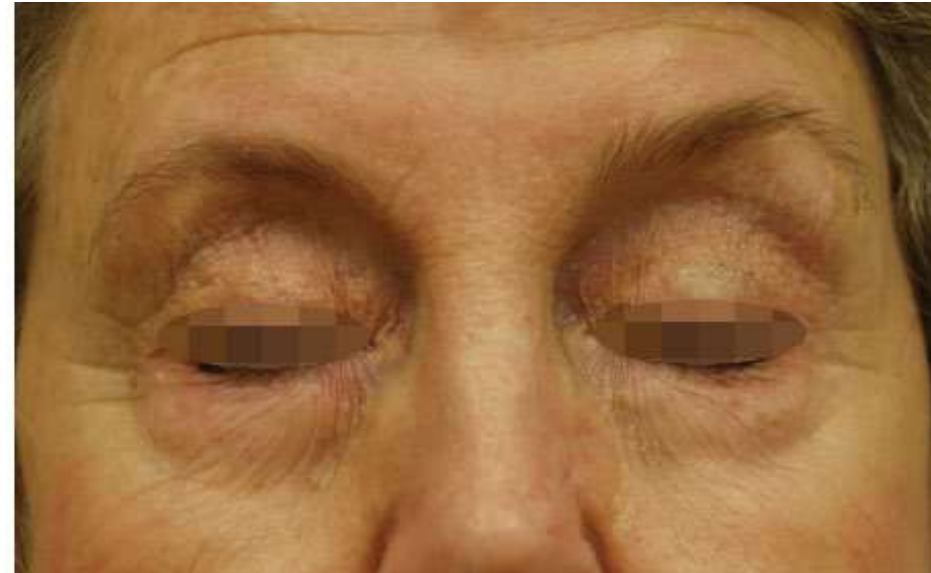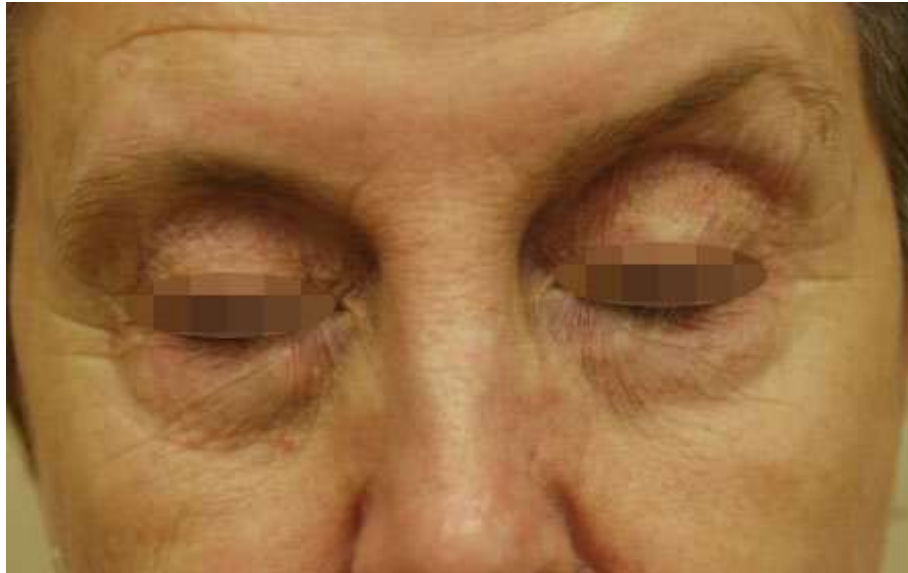Dr Kate Shattenkirk, NC, USA

Patient

Female

Number of Treatments

3 V-ST



Before

After



Eyes

Case Study – RE#316-B

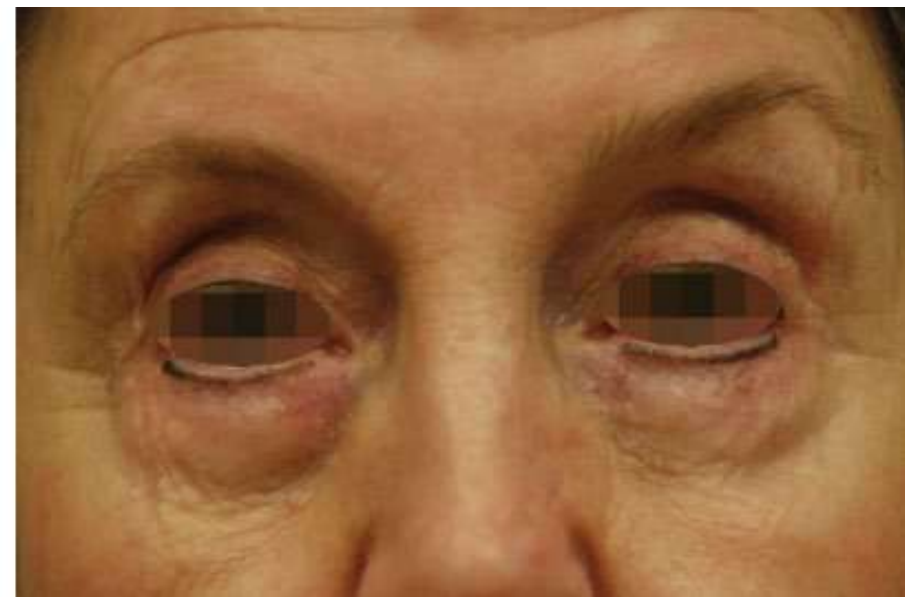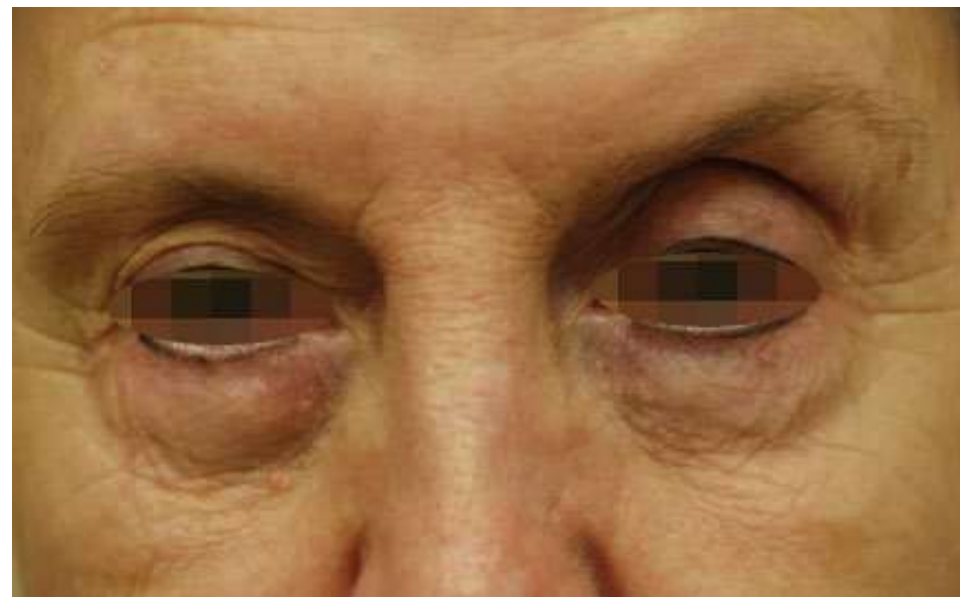Dr Kate Shattenkirk, NC, USA

Patient

Female

Number of Treatments

3 V-ST



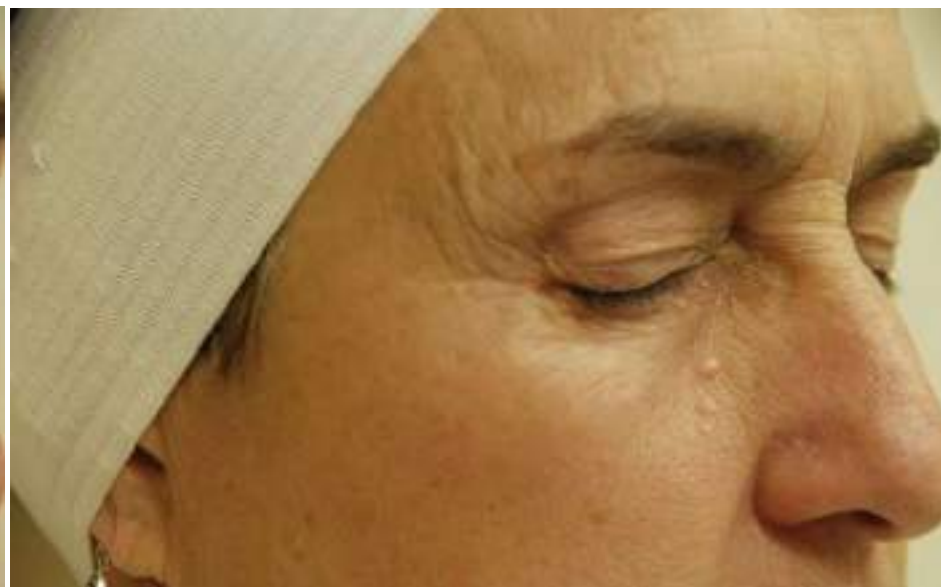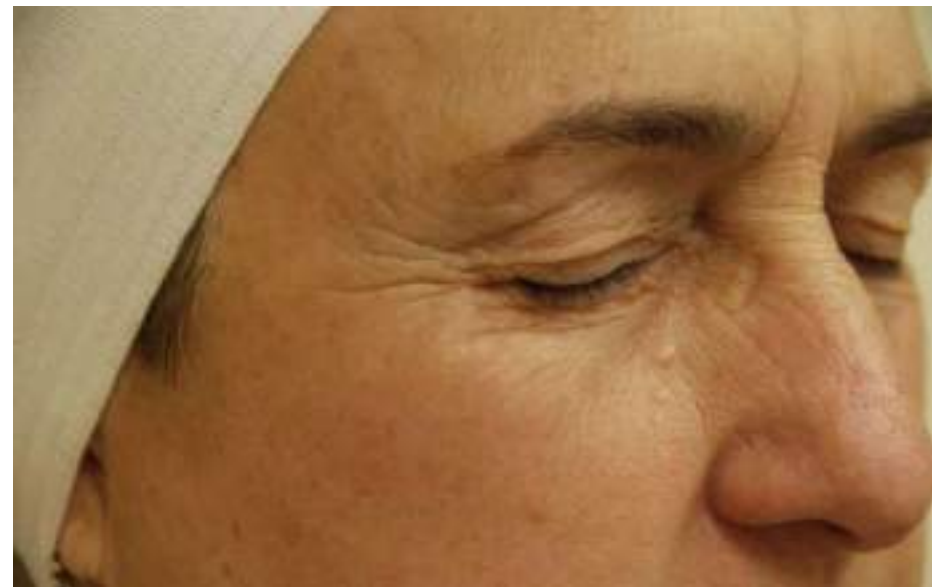Before

After



Eyes

Case Study – RE#317-A	Dr Kate Shattenkirk & Nicole Johnson, Pinehurst, NC, USA
Patient	Female
Number of Treatments	1 V-ST



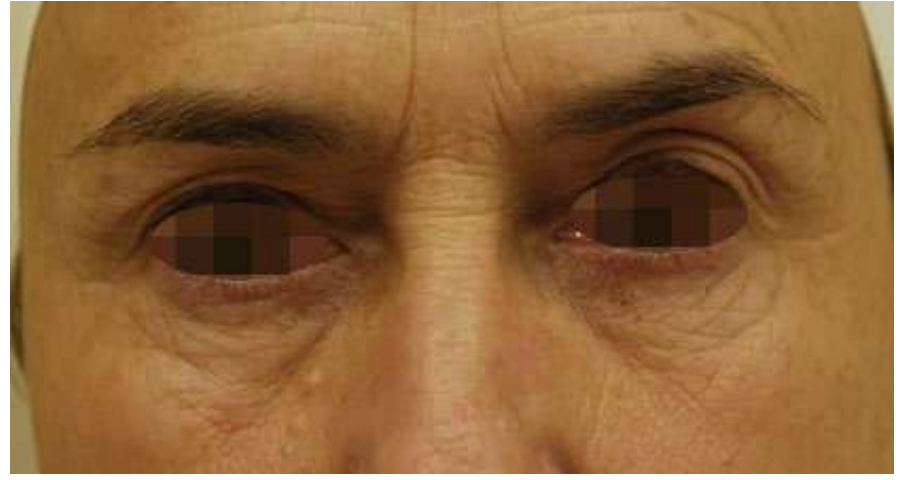
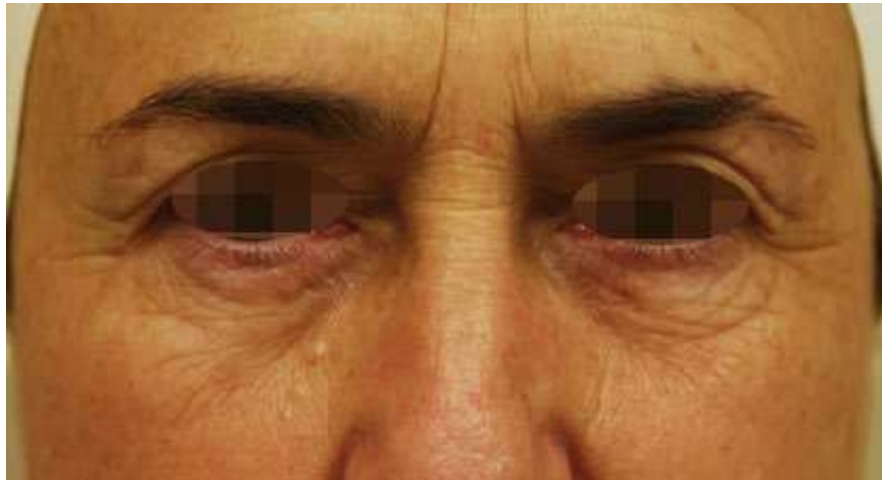Before

After



Eyes

Case Study – RE#317-B	Dr Kate Shattenkirk & Nicole Johnson, Pinehurst, NC, USA
Patient	Female
Number of Treatments	1 V-ST



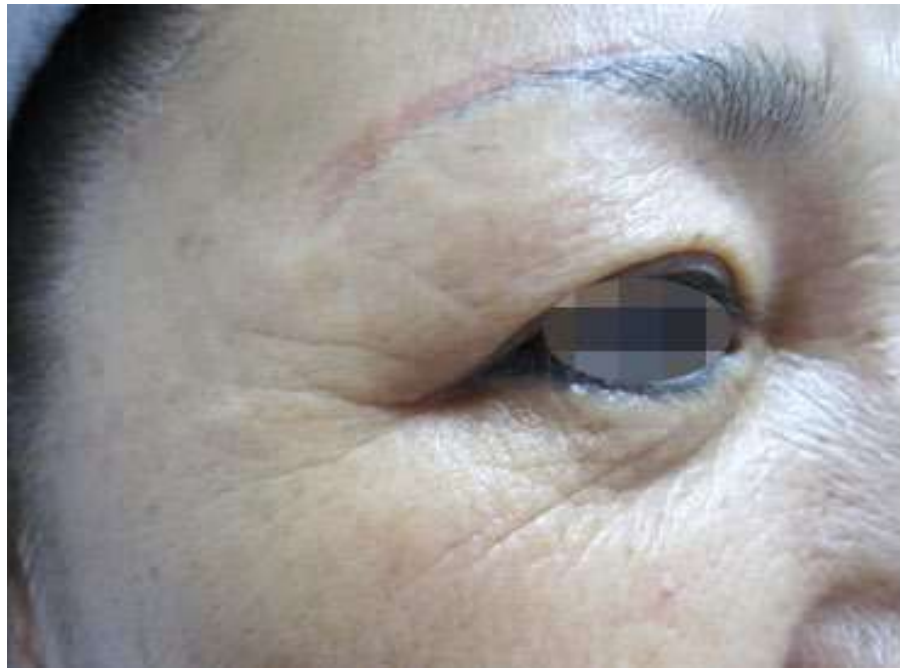Before

After

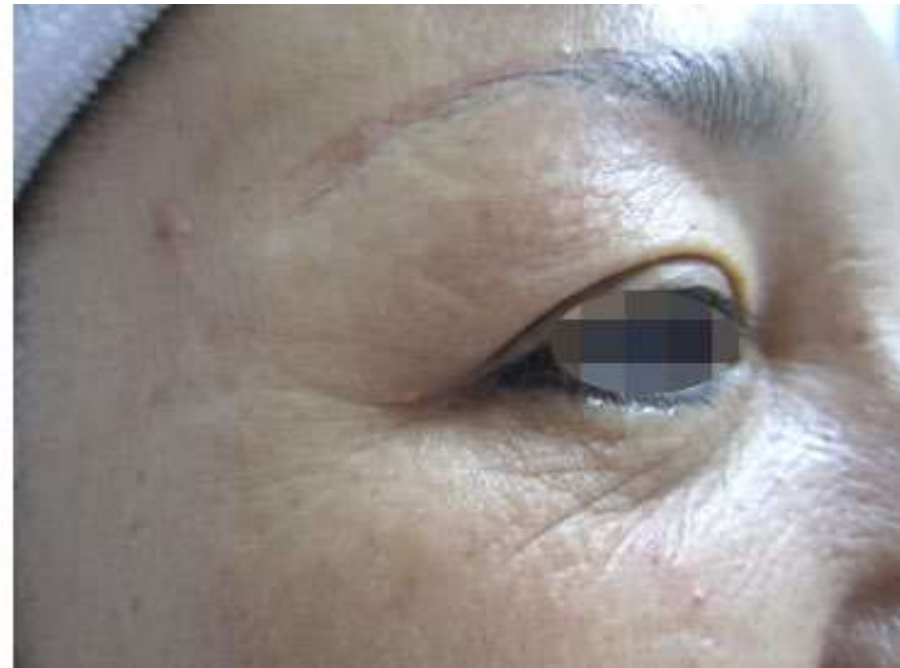

Eyes

Case Study – RE#372-A	Viora Ltd., China
Patient	Female, 48 years old
Number of Treatments	1 V-ST



Before

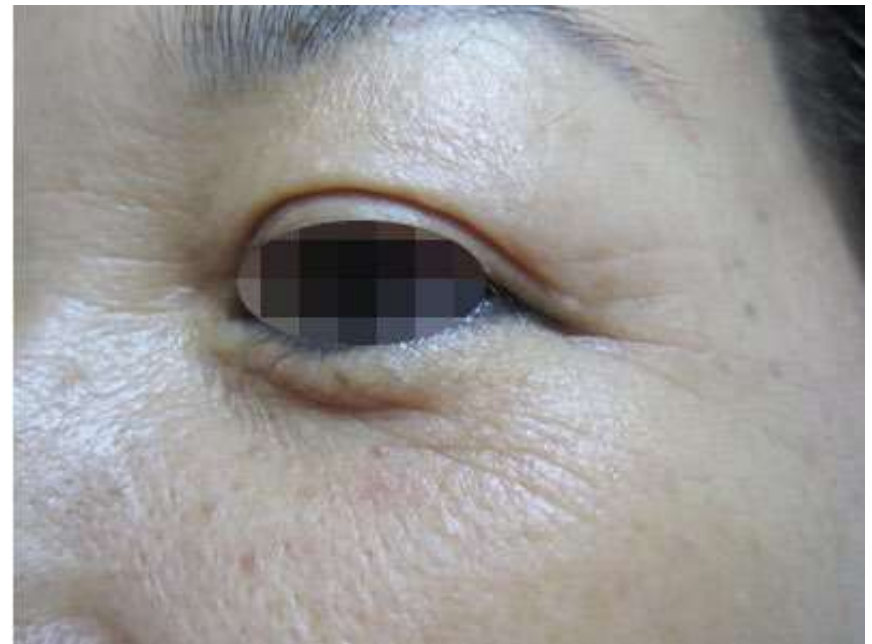
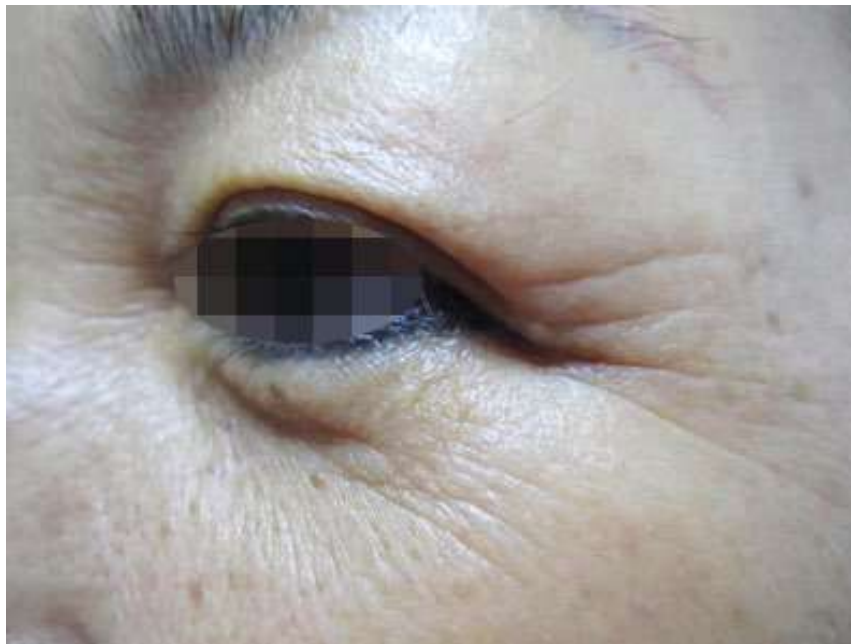
After



Eyes

Case Study – RE#372-B	Viora Ltd., China
Patient	Female, 48 years old
Number of Treatments	1 V-ST



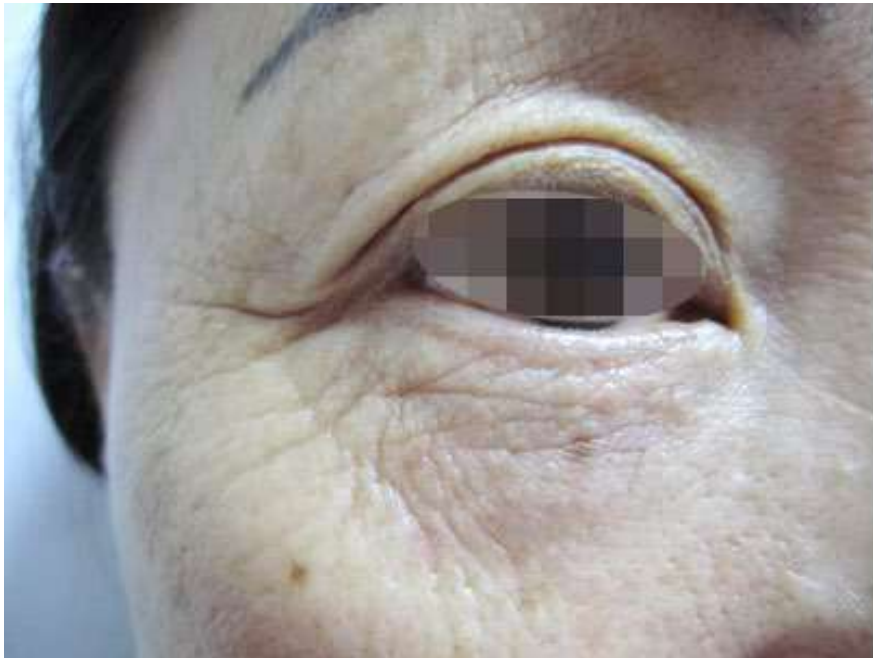Before

After

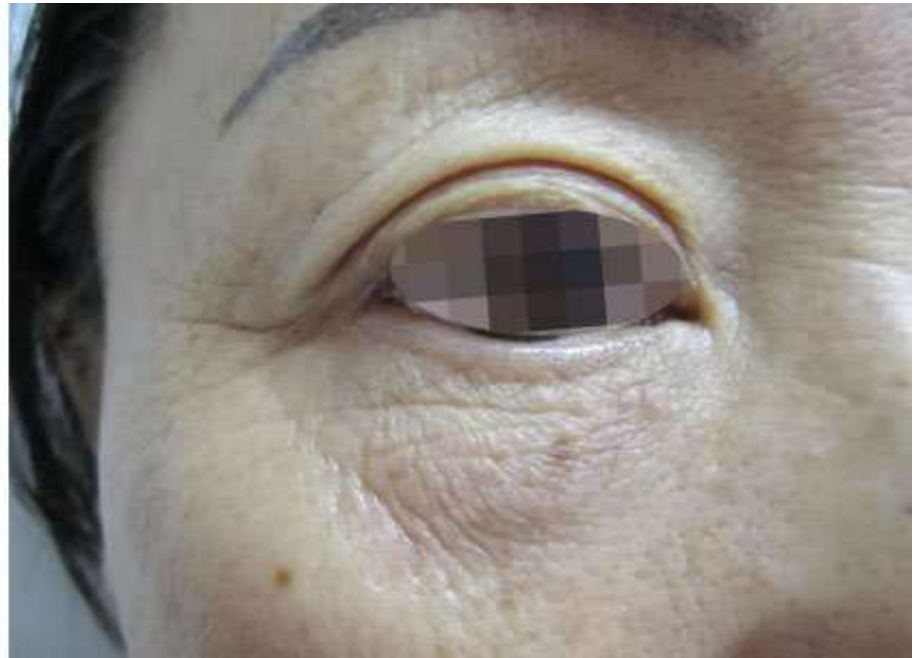

Eyes

Case Study – RE#373-A	Viora Ltd., China
Patient	Female, 55 years old
Number of Treatments	1 V-ST



Before

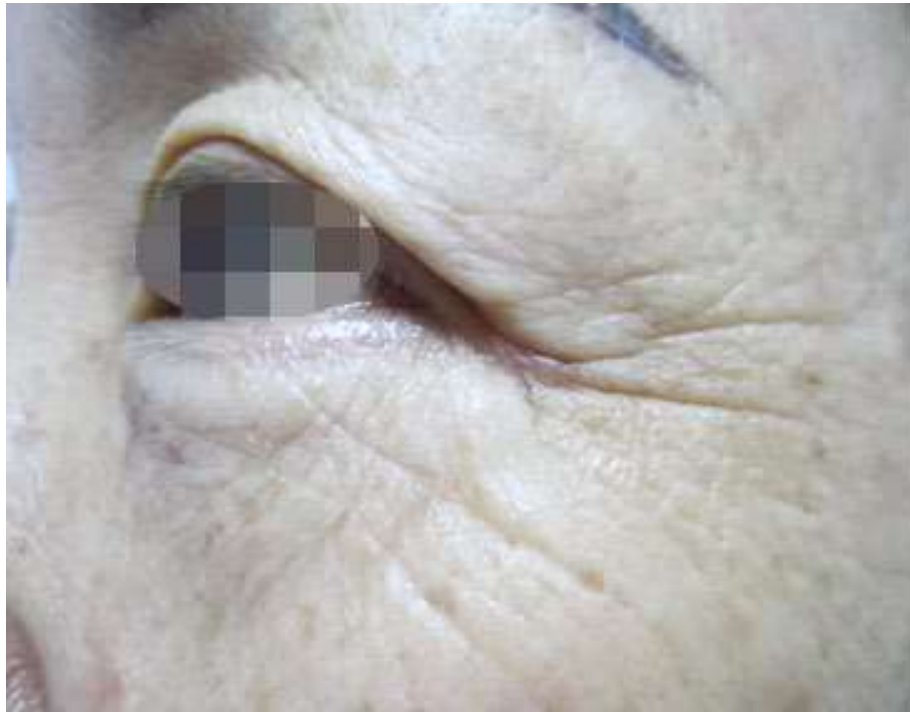

After

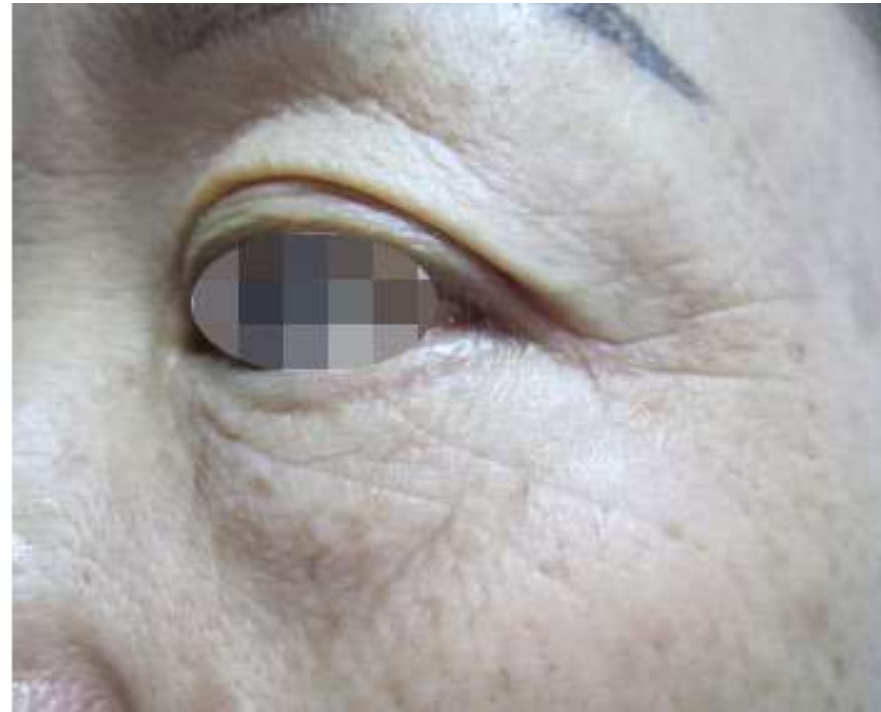

Crows feet

Case Study – RE#373-B	Viora Ltd., China
Patient	Female, 55 years old
Number of Treatments	1 V-ST



Before

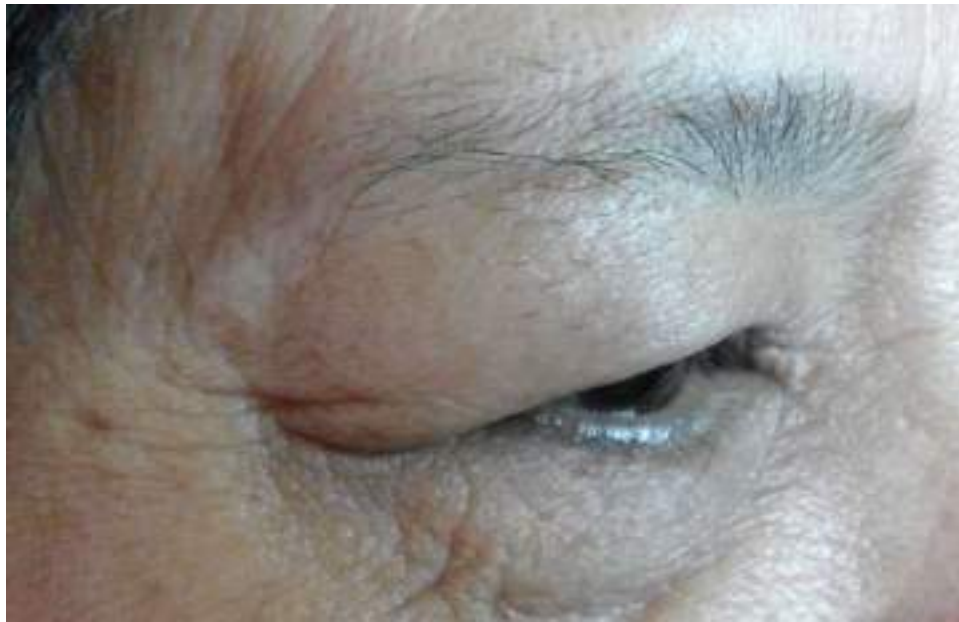

After

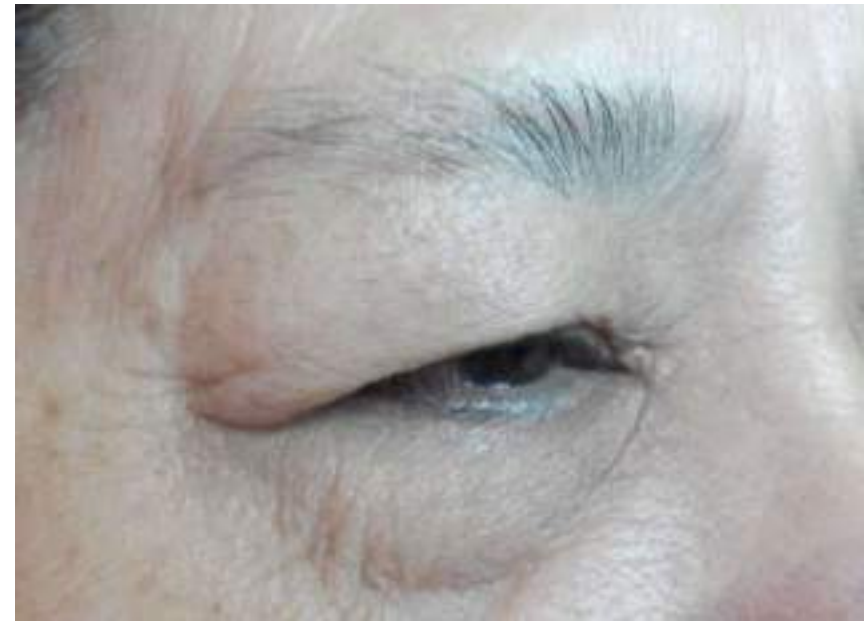

Crows feet

Case Study – RE#377	Viora Ltd., China
Patient	Female, 65 years old
Number of Treatments	1 V-ST



Before

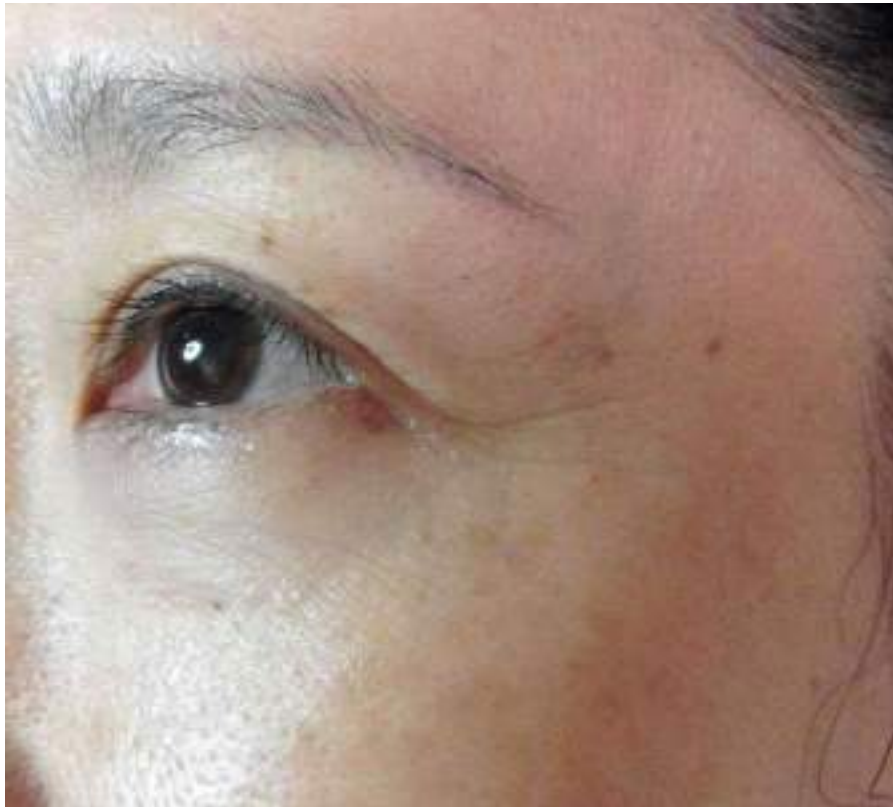


After

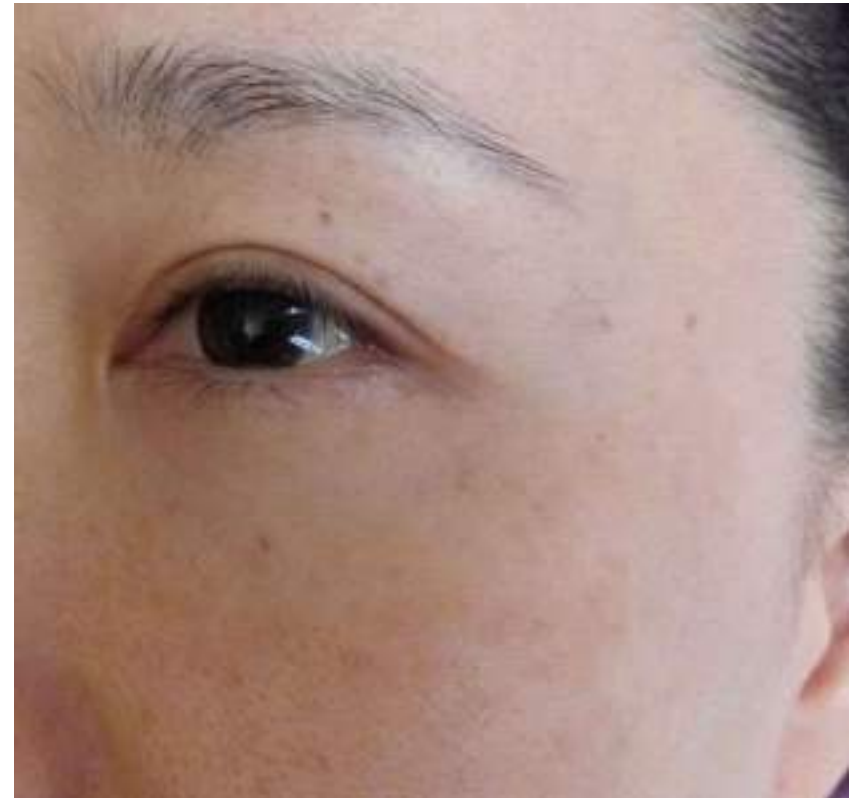

Crows feet

Case Study – RE#378	Viora Ltd., China
Patient	Female, 65 years old
Number of Treatments	1 V-ST



Before

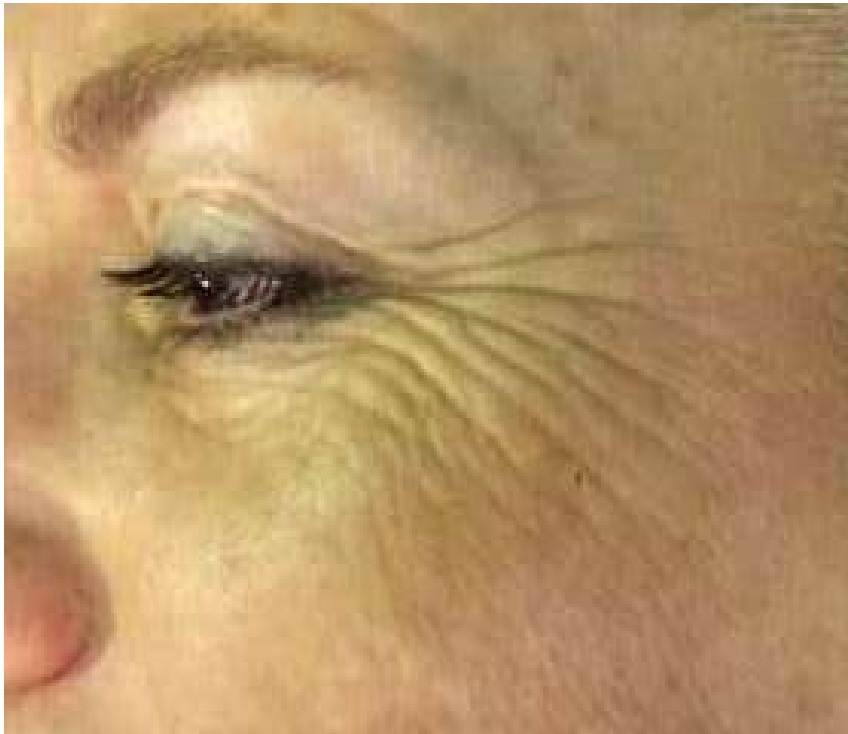

After

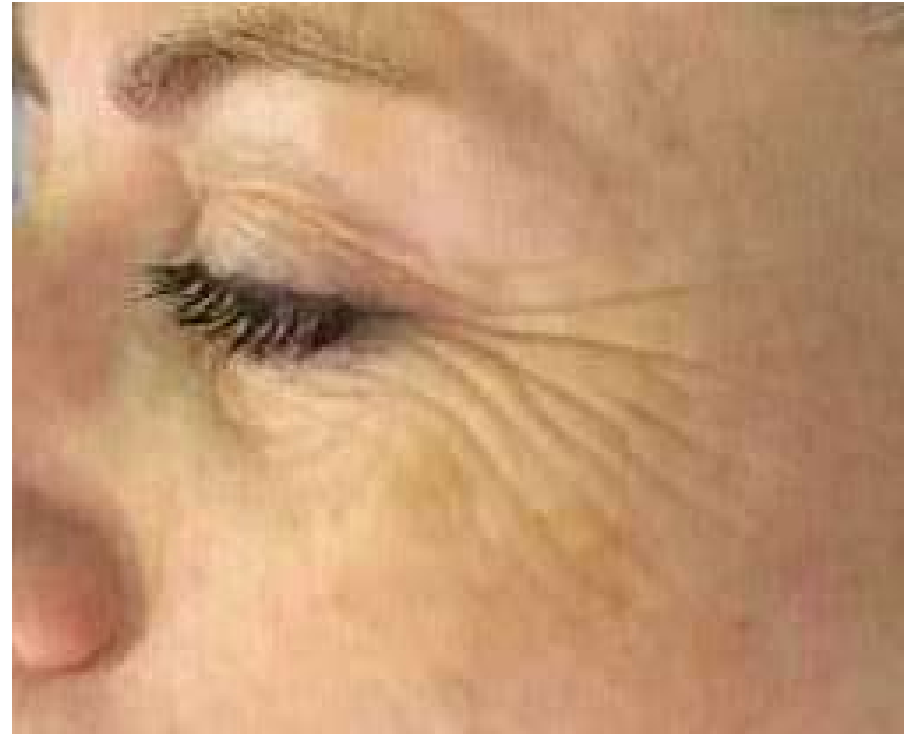

Crows feet

Case Study – VST#020	Viora Ltd., China
Patient	Female, 45 years old
Number of Treatments	1 - V-ST (58-84 J/cm ³ , Mode III)



Before

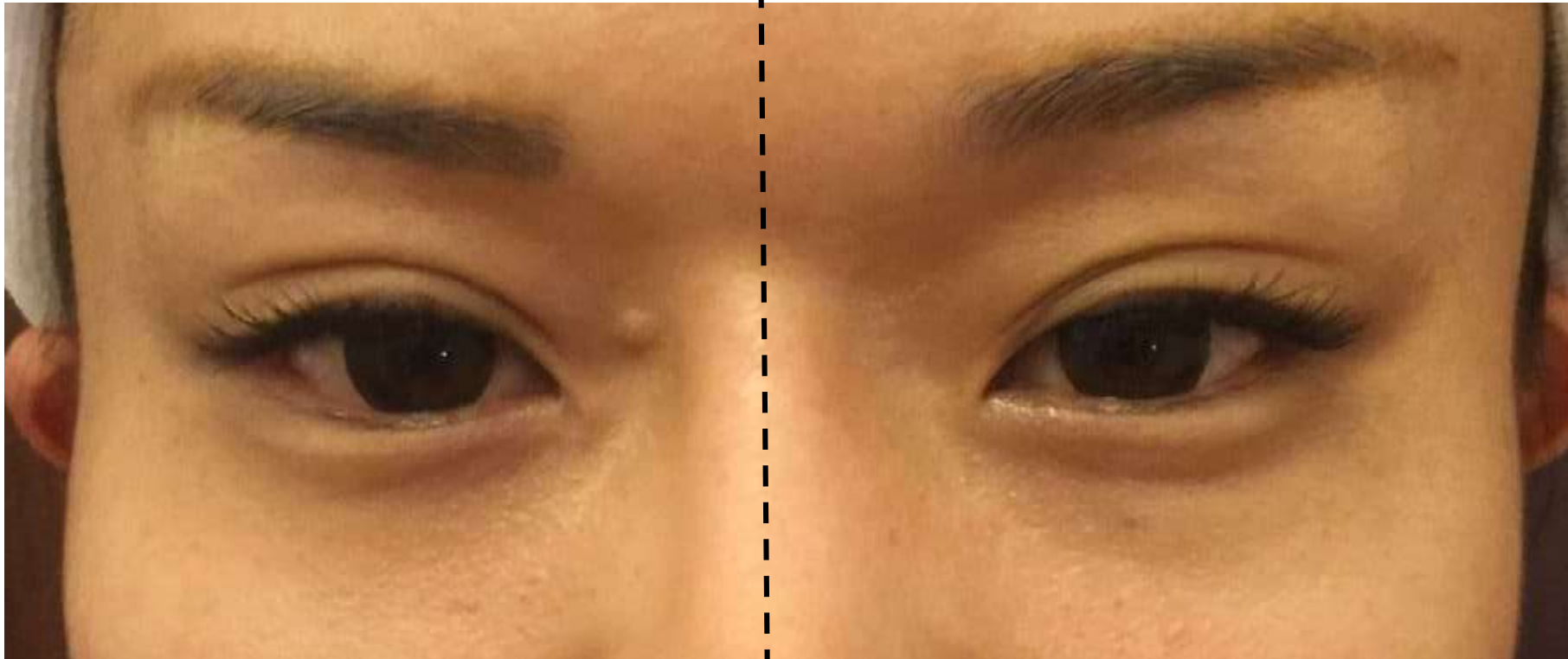


After



Eye bags

Case Study – VST#013	Viora Ltd., China
Patient	Female, 28 years old
Number of Treatments	1 V-ST (52-64 J/cm³, Mode III)



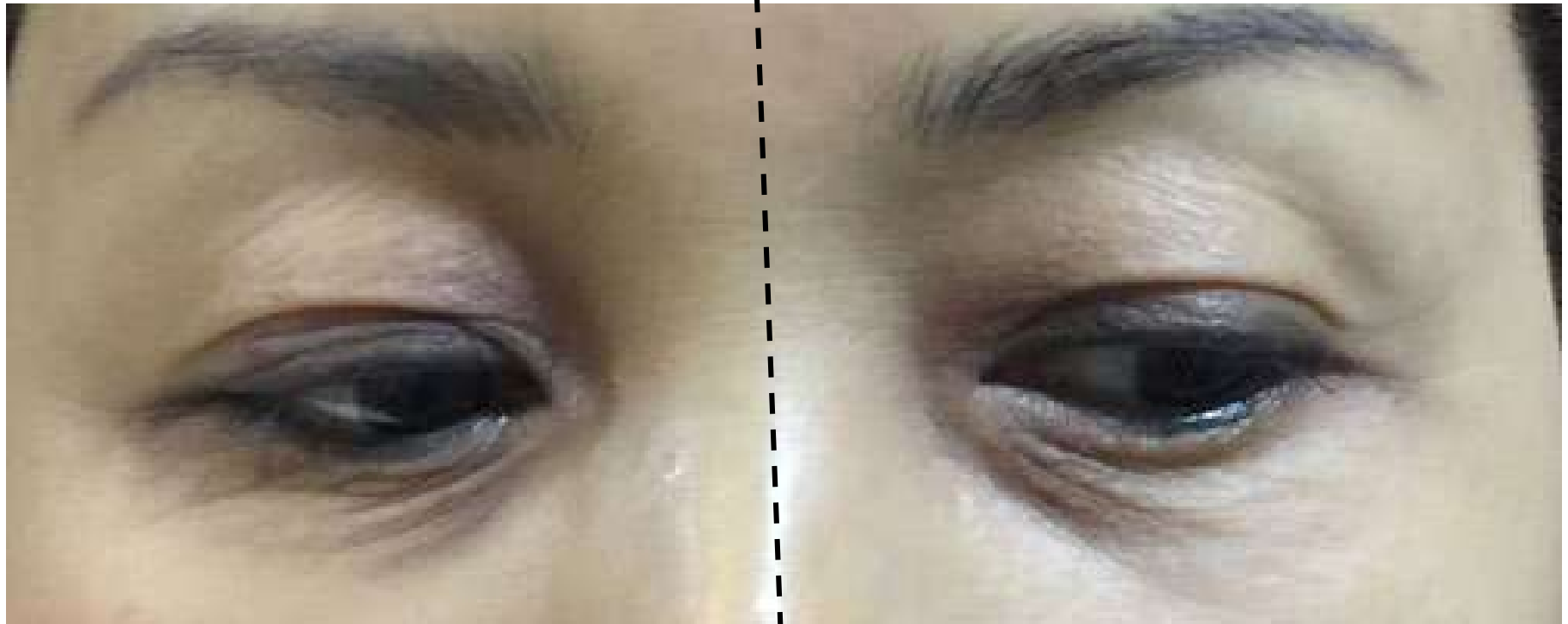Treated

Untreated



Eye bags

Case Study – VST#014	Viora Ltd., China
Patient	Female, 48 years old
Number of Treatments	1 V-ST (58-72 J/cm³, Mode III)



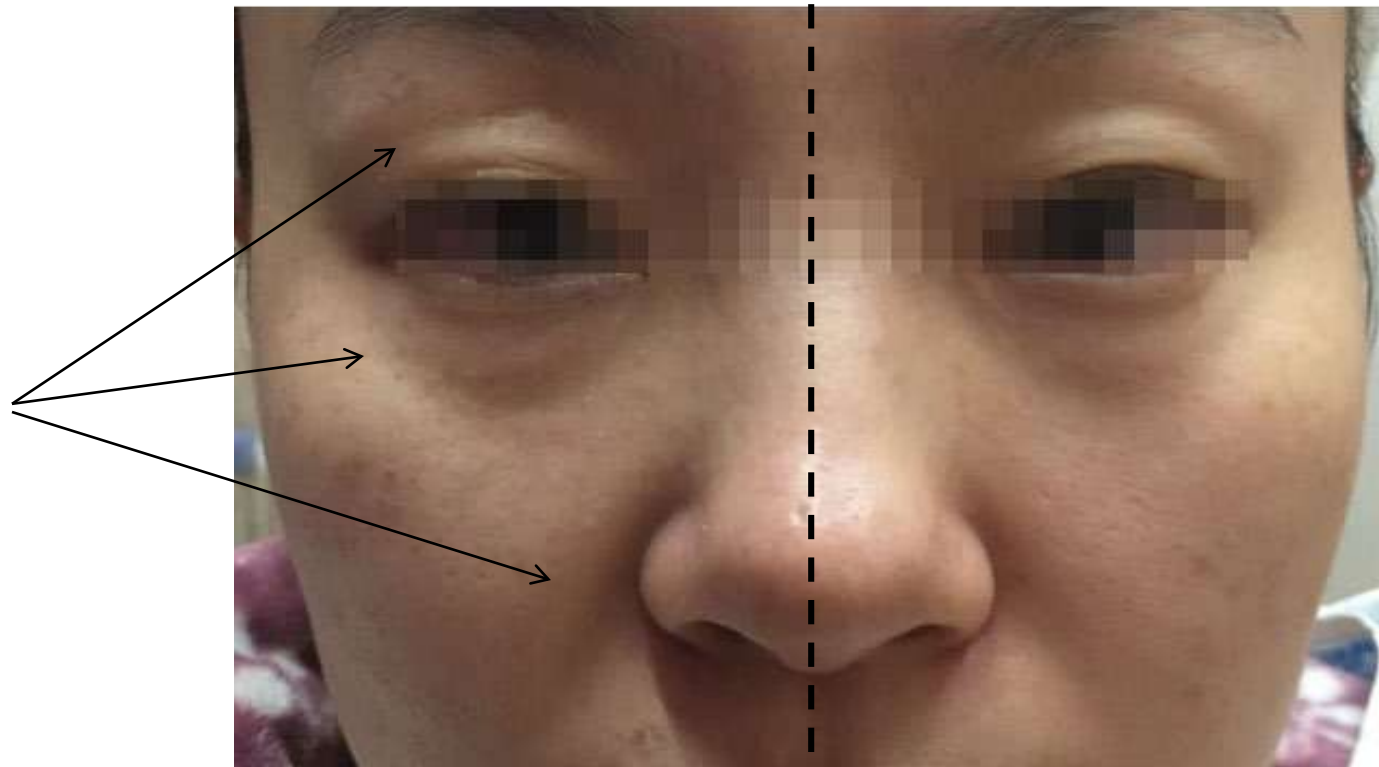
Untreated

Treated



Eye bags & nasolabial folds

Case Study – VST#015	Viora Ltd., China
Patient	Female, 41 years old
Number of Treatments	1 V-ST (60-70 J/cm³, Mode III)



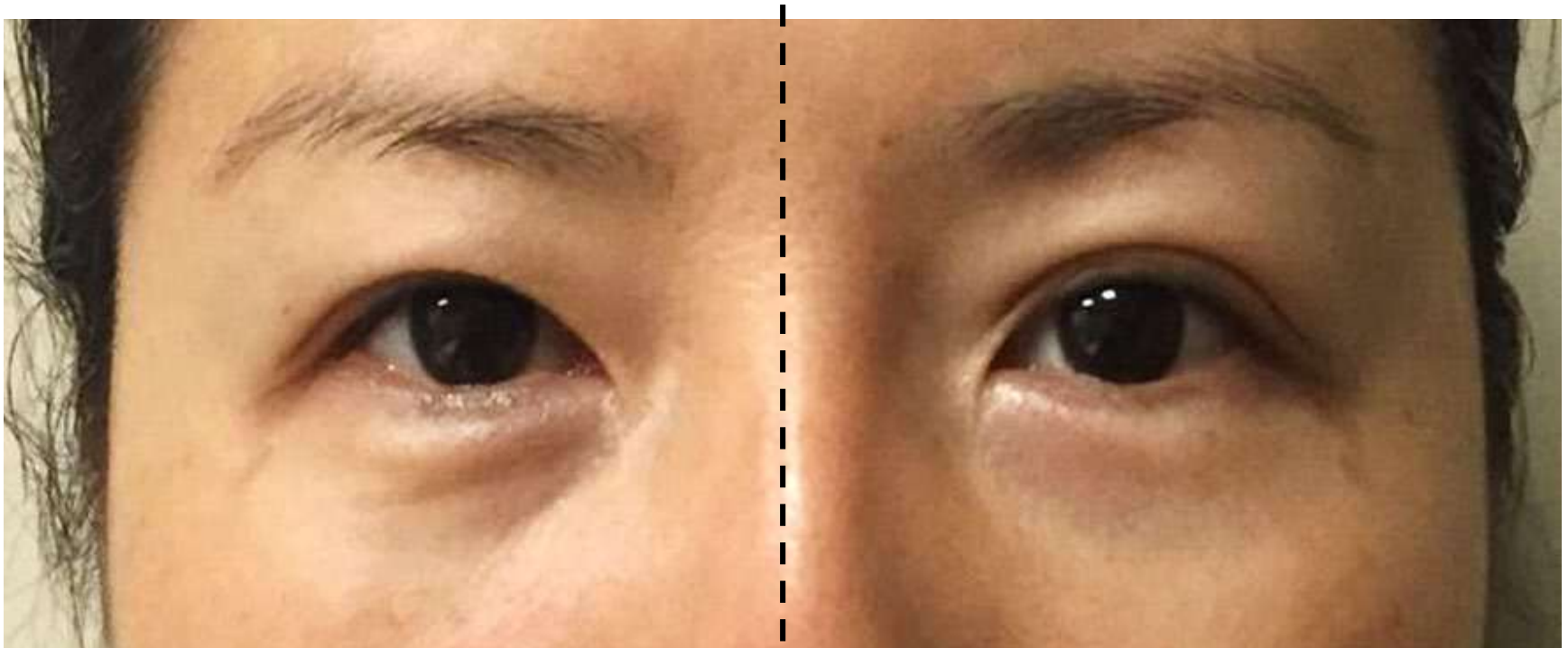Untreated

Treated



Eye bags

Case Study – VST#018	Viora Ltd., China
Patient	Female, 44 years old
Number of Treatments	1 V-ST (60-82 J/cm³, Mode III)



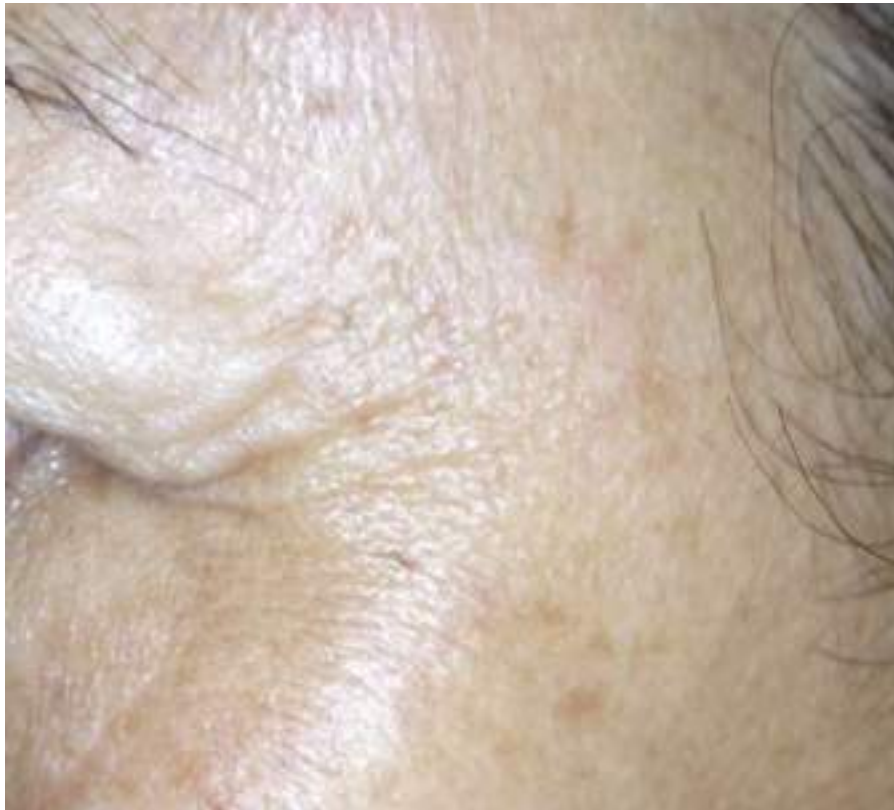Untreated

Treated

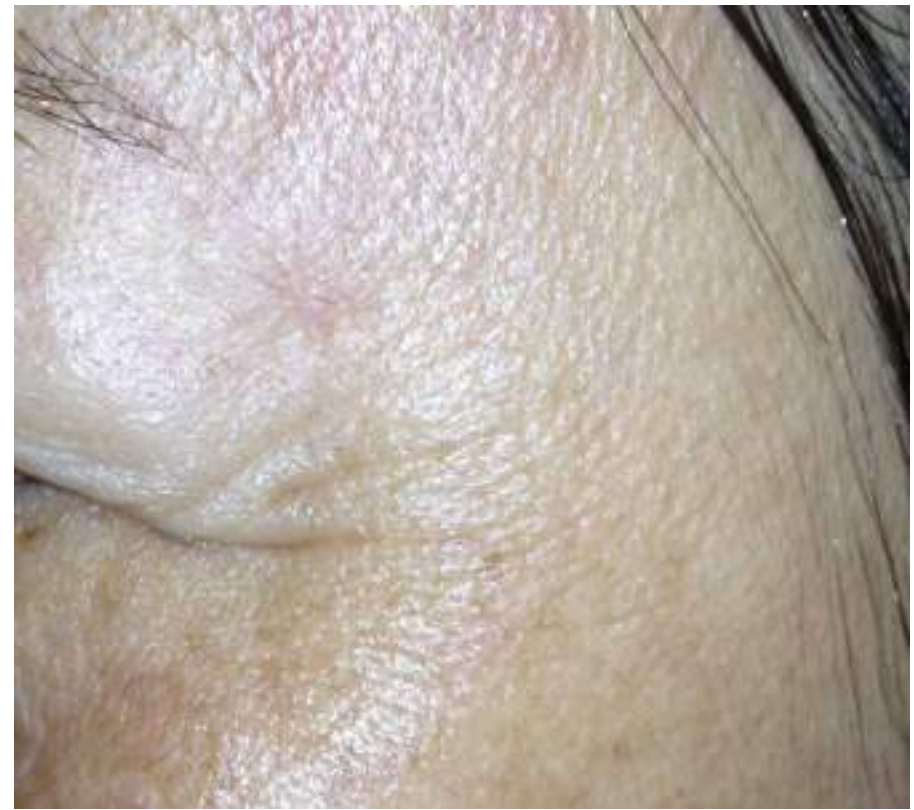

Crows feet

Case Study – VST#006	Dr Kristine Cabel-Castaneda, Quezon City, Philippines
Patient	Female, 67 years old
Number of Treatments	1 V-ST



Before

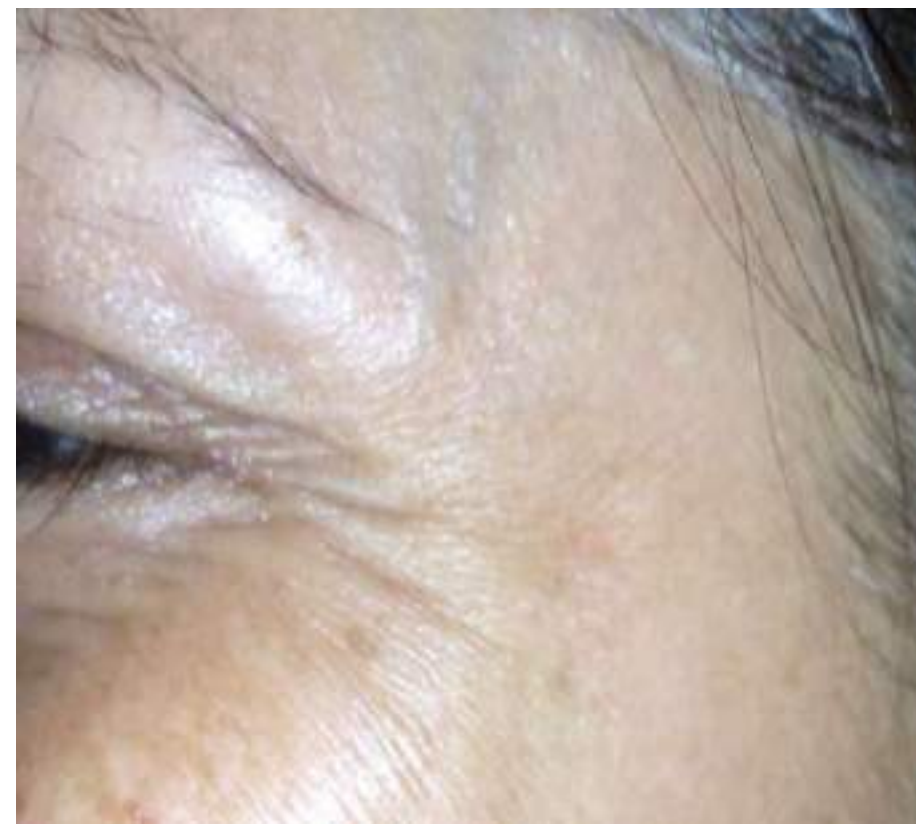

After

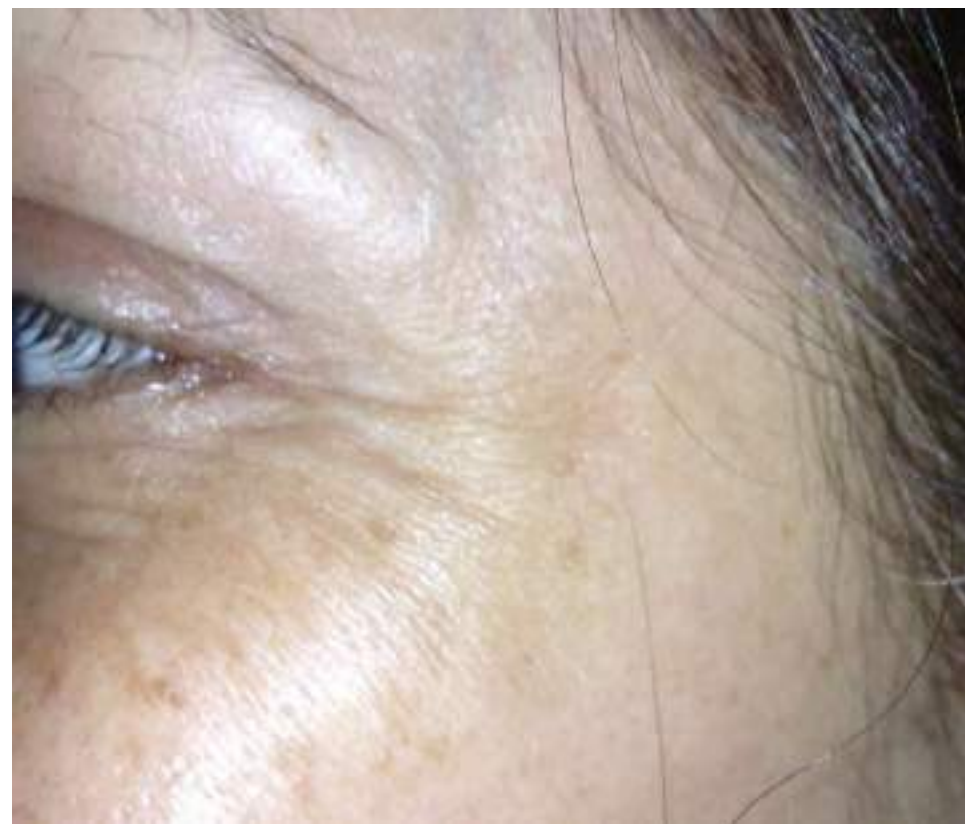

Eyelids

Case Study – VST#010	Dr Kristine Cabel-Castaneda, Quezon City, Philippines
Patient	Female, 67 years old
Number of Treatments	1 V-ST



Before

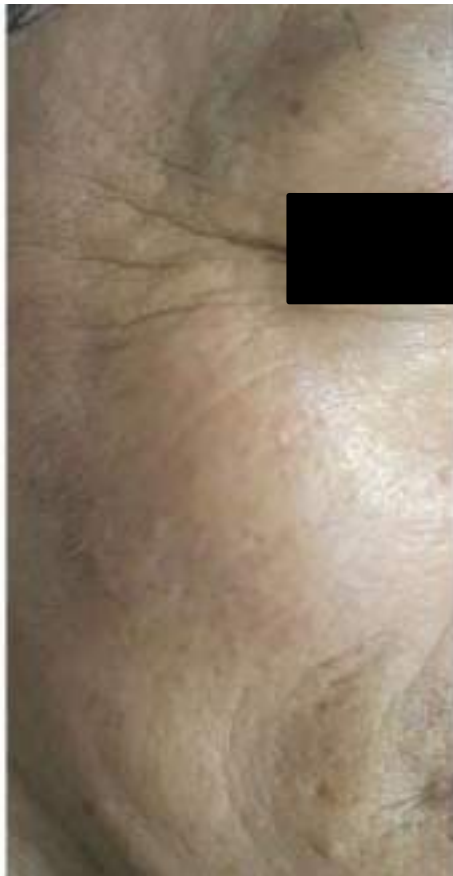

After

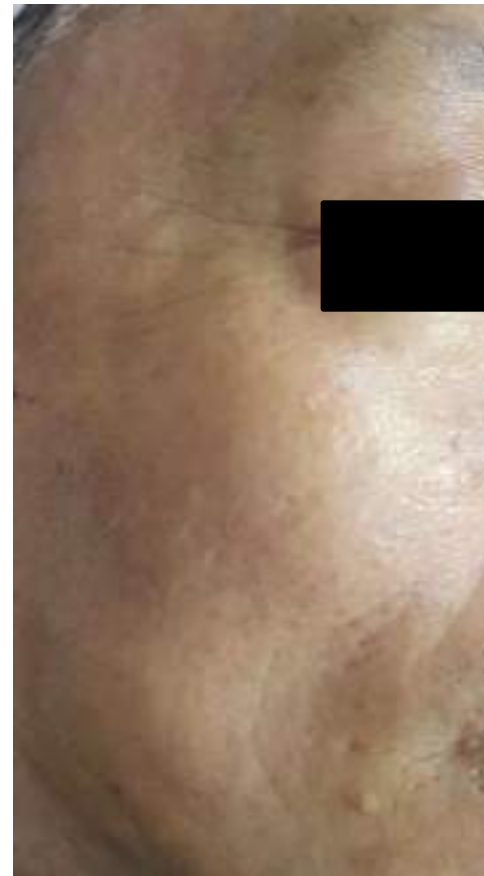

Crows feet

Case Study – VST#033-A	Dr. Theint Han Htwe, Yangon, Myanmar
Patient	Male, 58 years old
Number of Treatments	1 V-ST (Mode III, 64 – 76 J/cm³)



Before

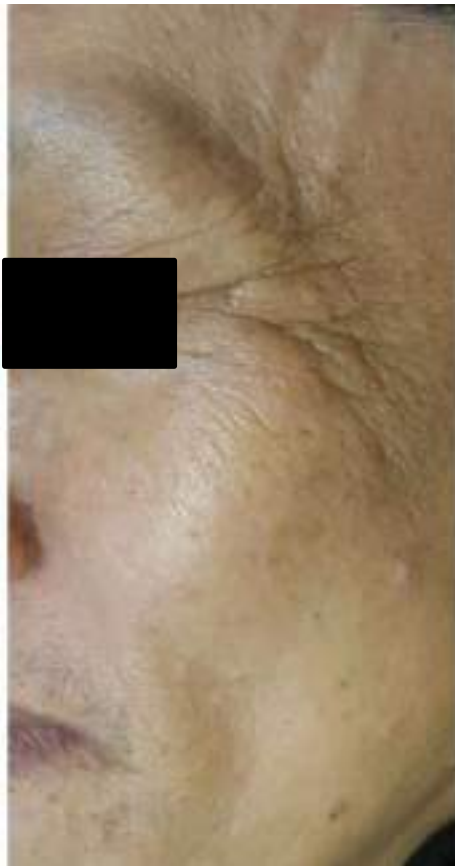

After

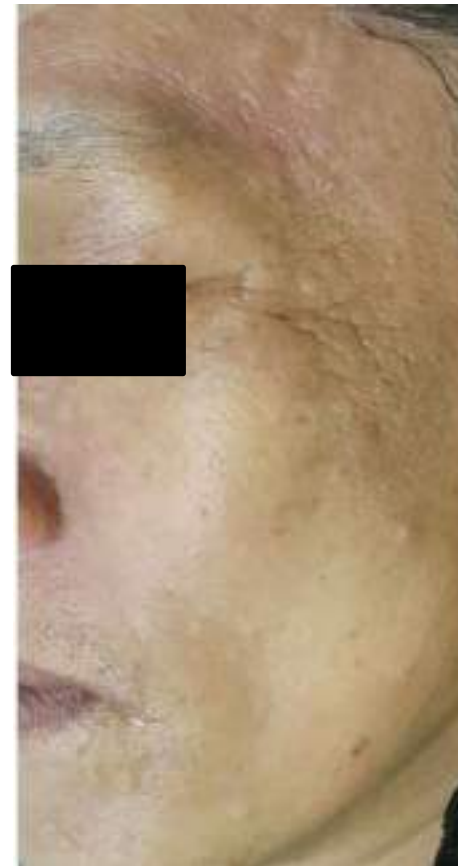

Crows feet

Case Study – VST#033-B	Dr. Theint Han Htwe, Yangon, Myanmar
Patient	Male, 58 years old
Number of Treatments	1 V-ST (Mode III, 64 – 76 J/cm³)



Before



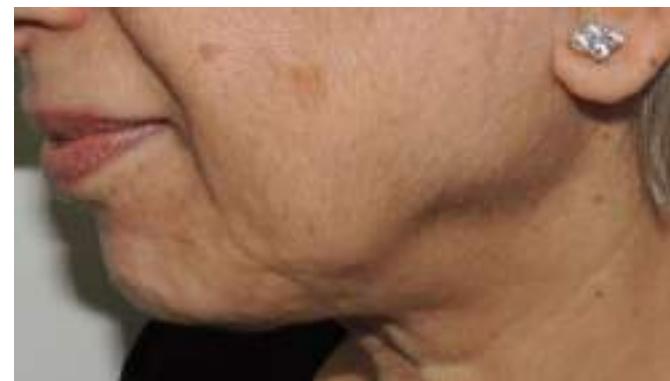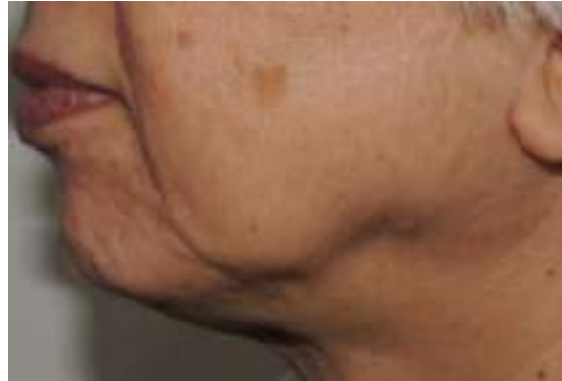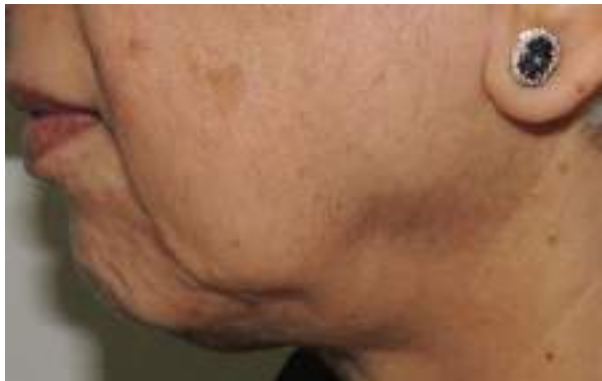After



Neck and chin

Sagging skin and wrinkles

Case Study – RE#370	Dr. Sajal Halder, Delhi, India
Patient	Female
Number of Treatments	5 V-ST



Before

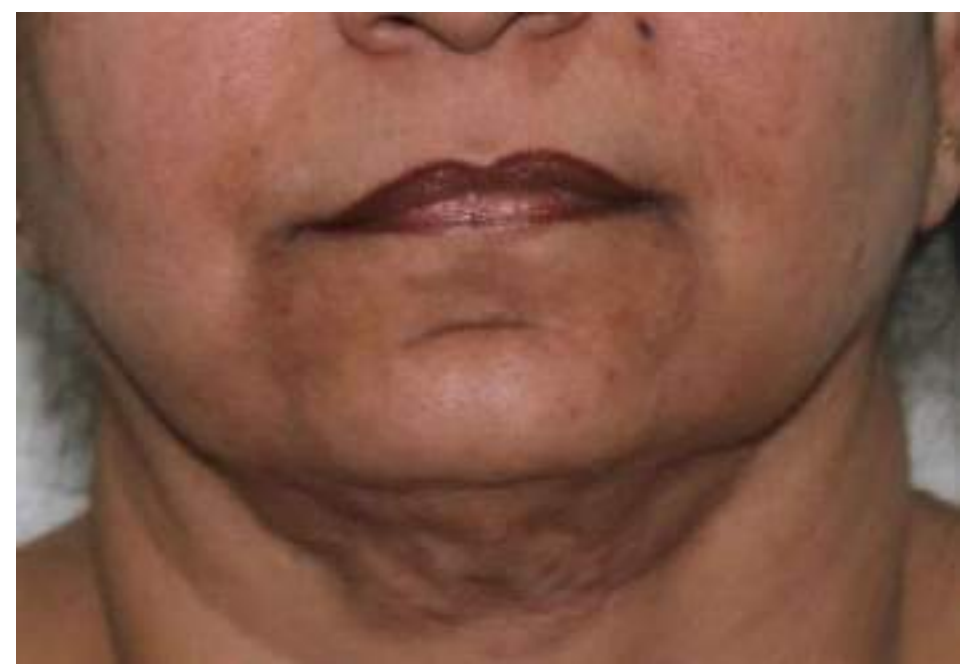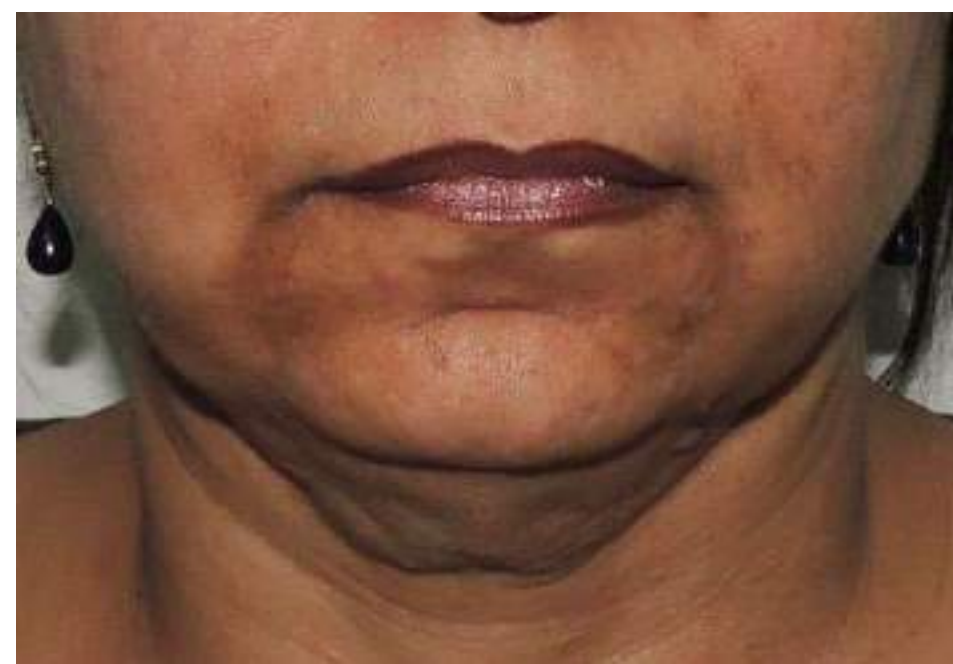After 2 Treatments

After 5 Treatments



Sagging skin

Case Study – RE#371	Dr. Sajal Halder, Delhi, India
Patient	Female
Number of Treatments	2 V-ST



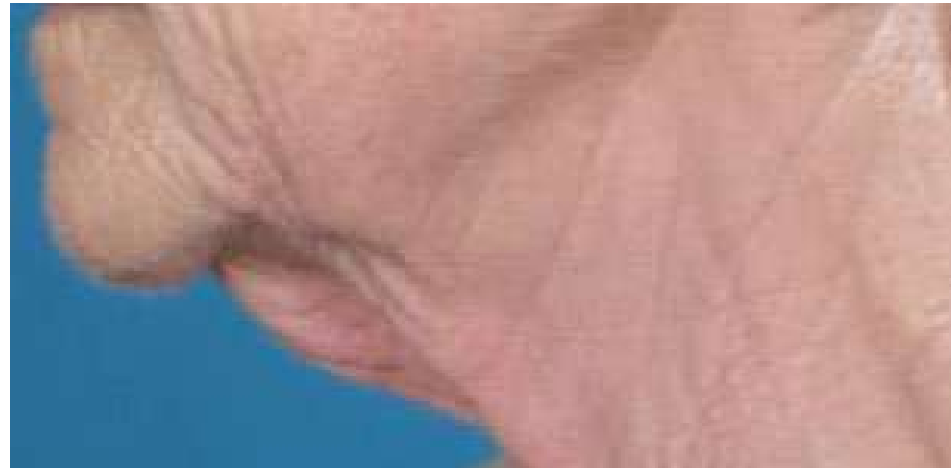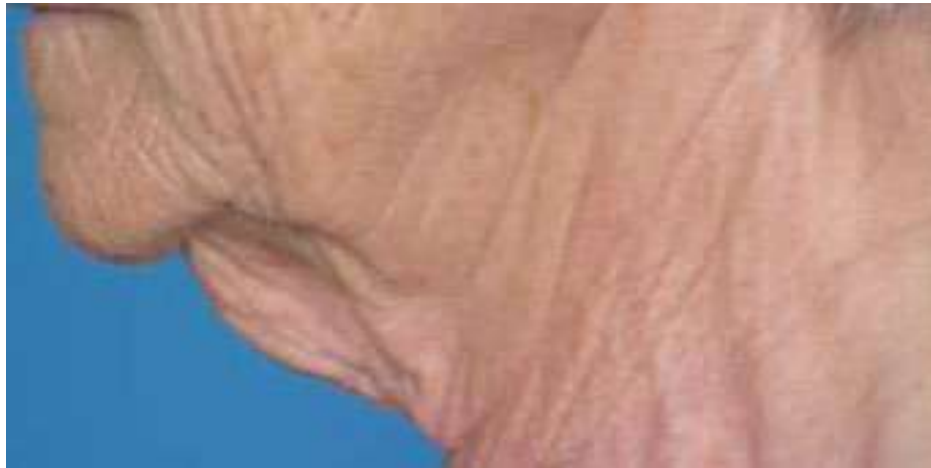Before

After



Sagging skin and wrinkles

Case Study – RE#355-A	Dr. Daniel Man, Boca Raton, Florida, USA
Patient	Female, 72 years old
Number of Treatments	9 V-ST



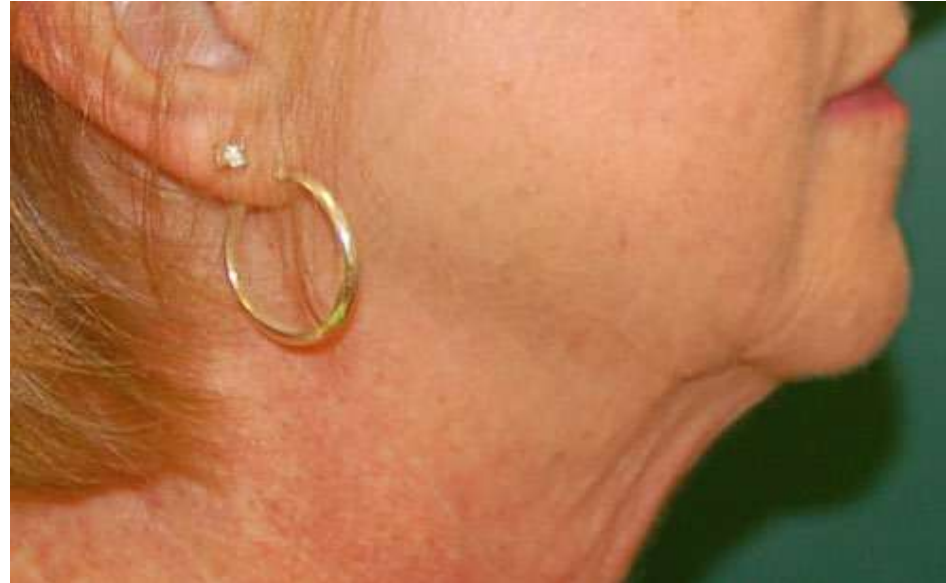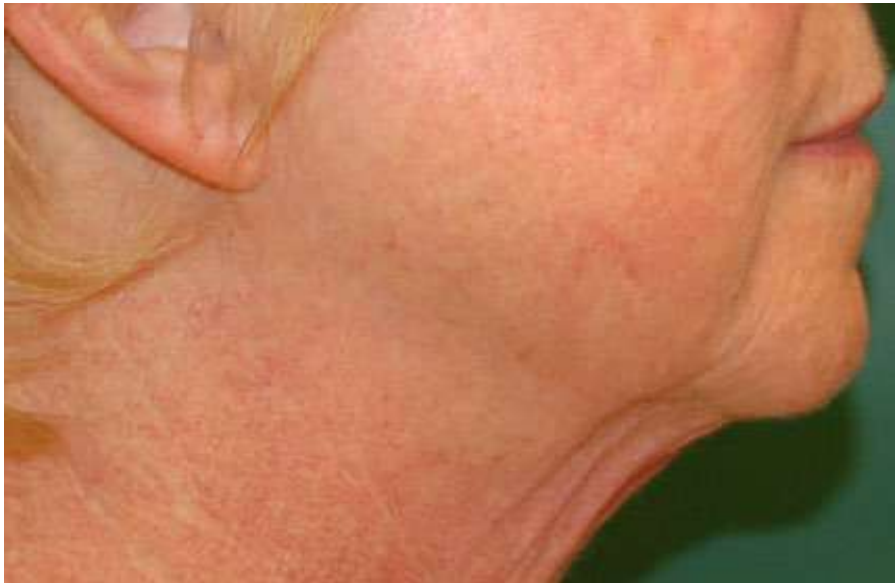Before

After



Neck and Jowl

Case Study – RE#271	Dr. Roger Emory, Abingdon, VA, U.S.A
Patient	Female
Number of Treatments	5 V-ST



Before

After



Neck

Case Study – RE#250

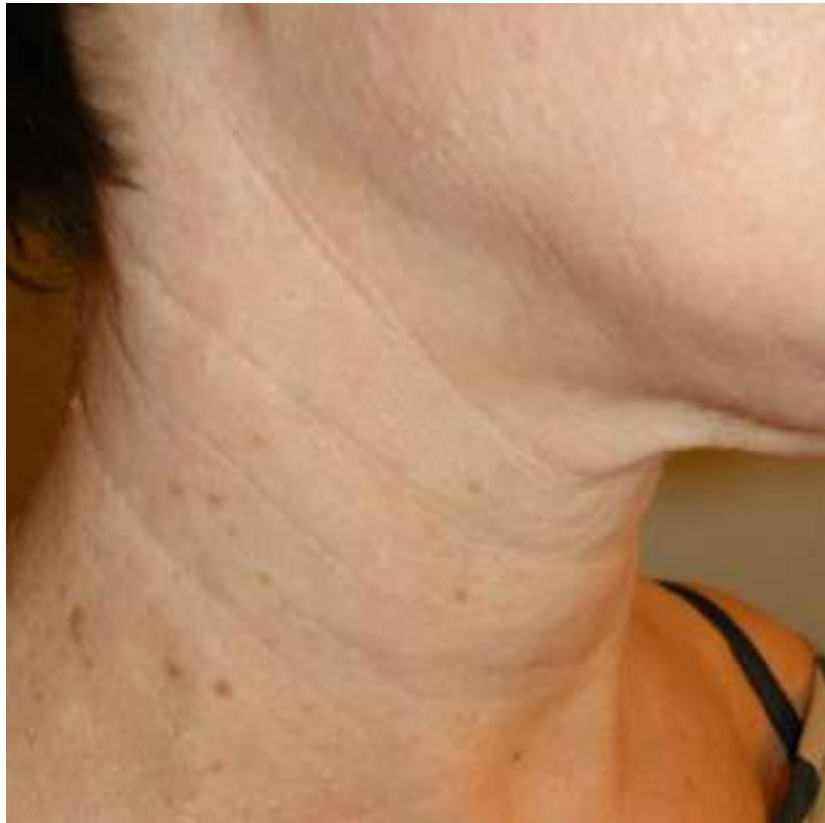Dr Marina Landau, Israel

Patient

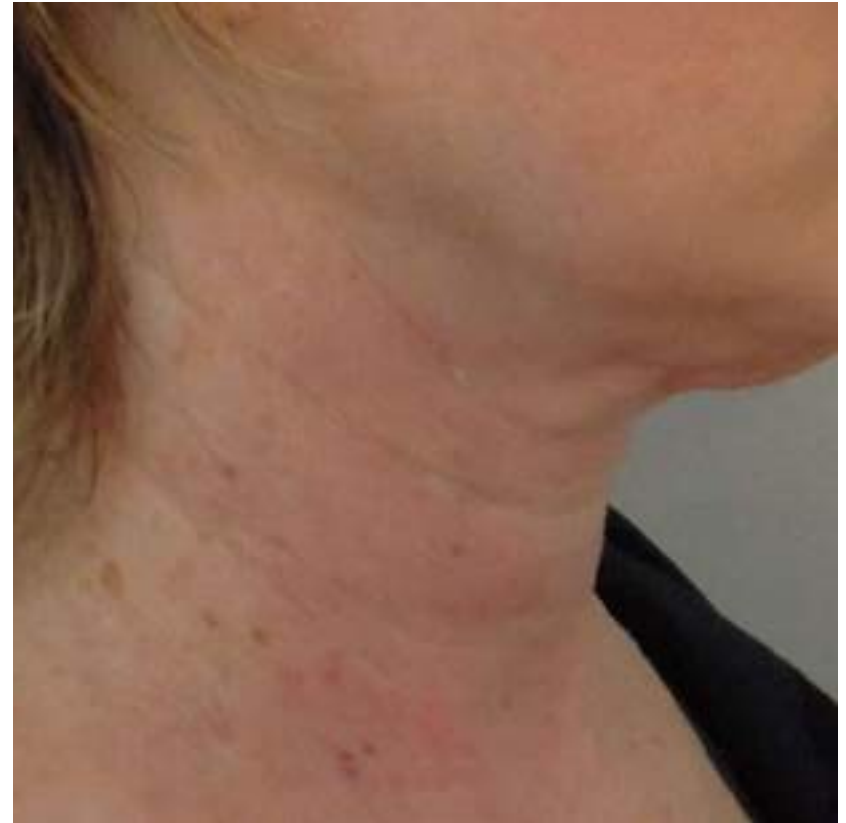Female

Number of Treatments

2 V-ST



Before

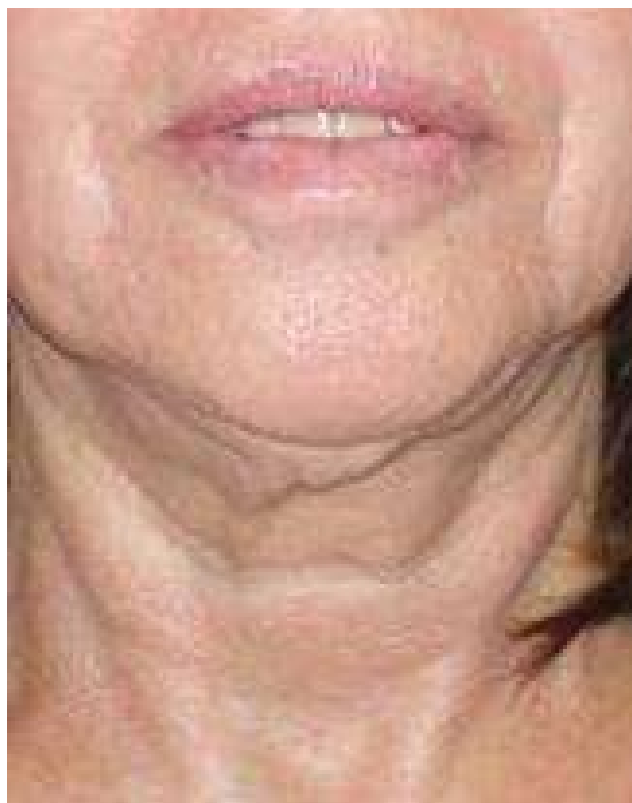

After

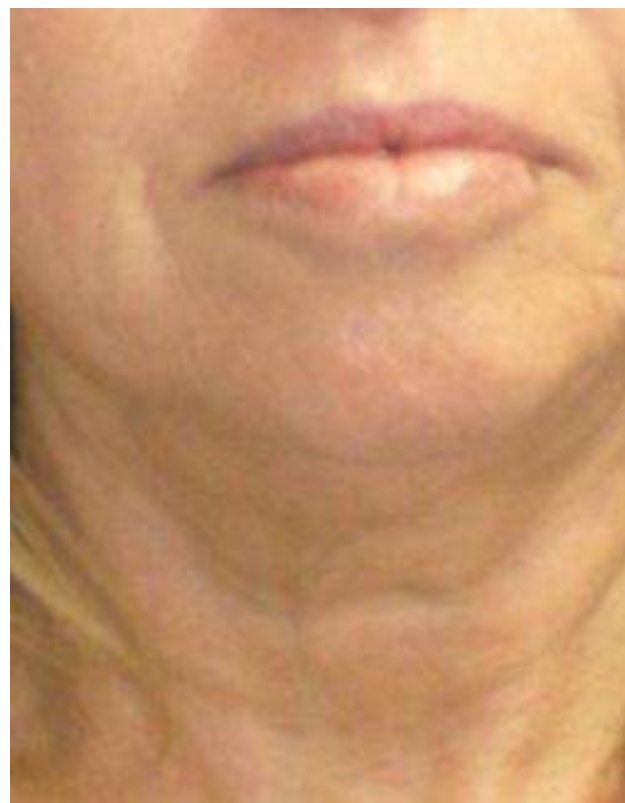

Sagging skin on the jowl and neck

Case Study – RE #124	Ronit Sade, Israel
Patient	Female, 59 years old
Number of Treatments	3 V-ST



Before



After



Neck

Case Study – RE#336

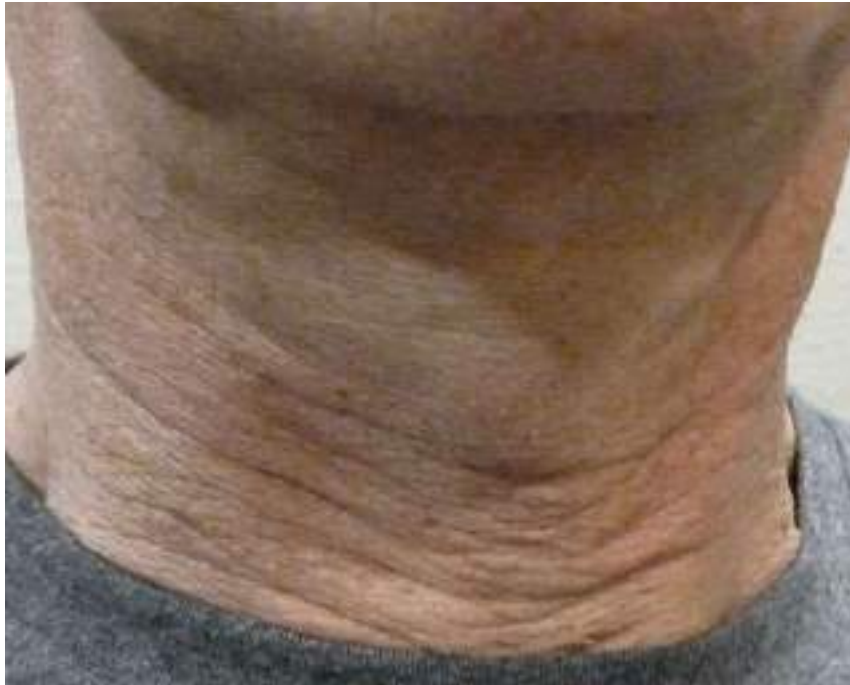Kucumber Skin Lounge, Seattle, WA, USA

Patient

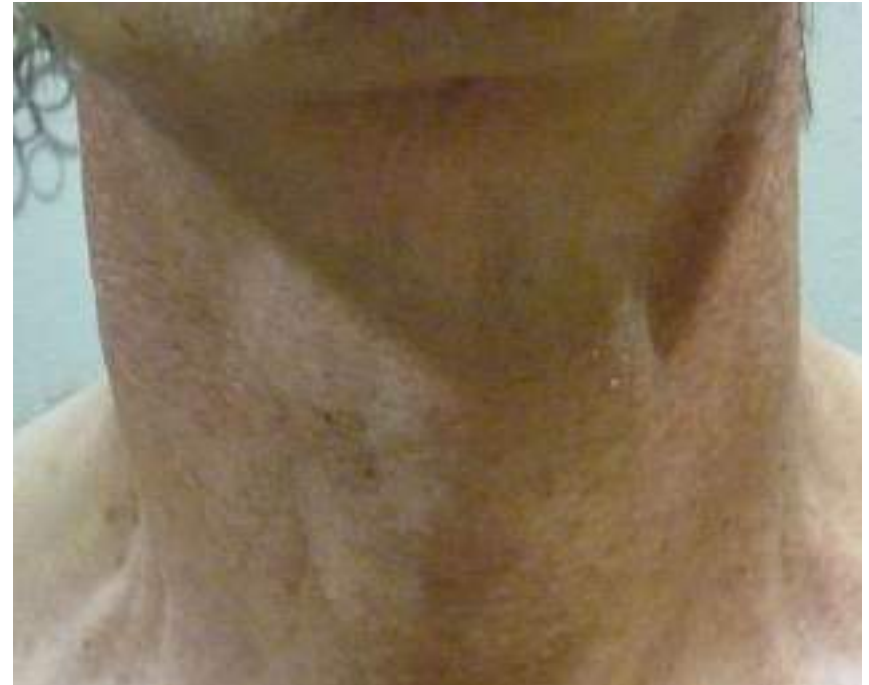Male, 50 years old

Number of Treatments

3 V-ST (84-90 J/cm³, Mode III, 6 passes)



Before

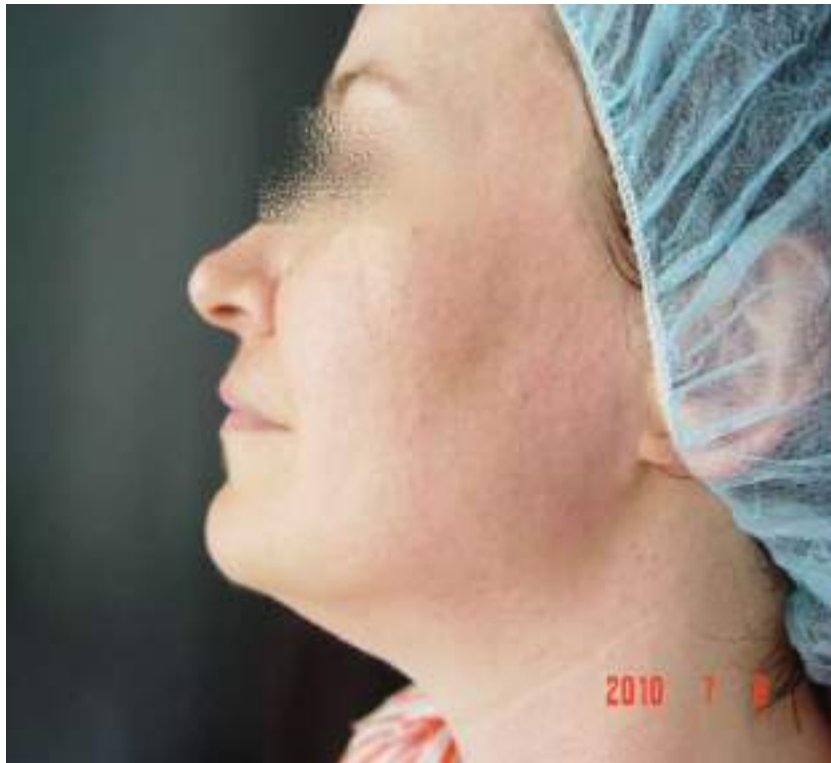

After

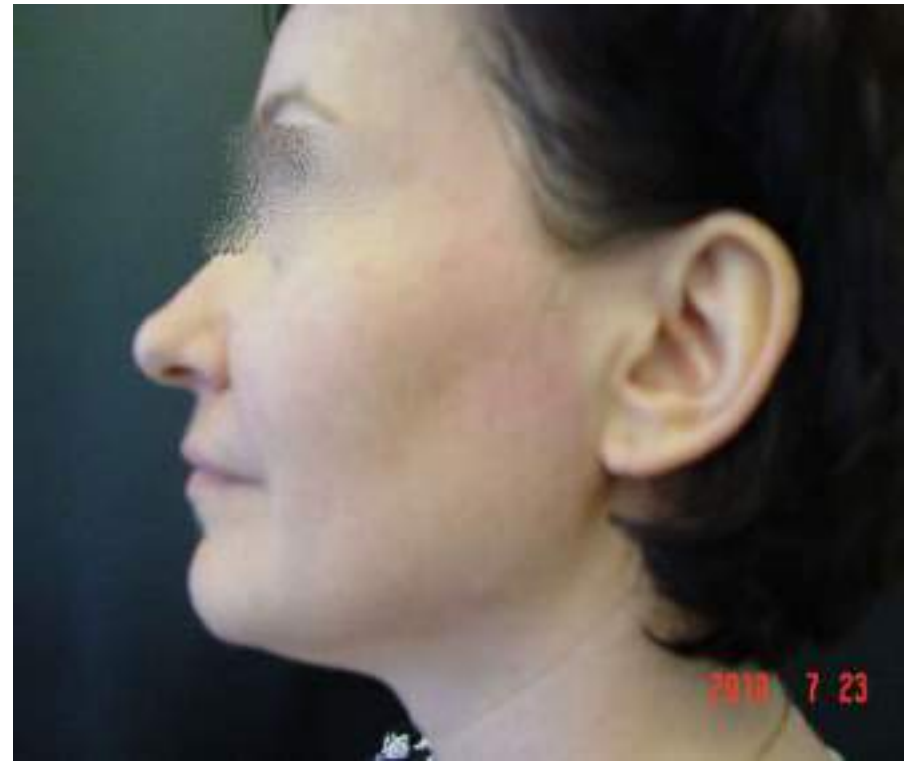

Face and Neck

Case Study – RE #161	Clinic KLASKO, Dr. N. Markina, Moscow, Russia
Patient	Female, 42 years old
Number of Treatments	2 V-ST



Before



After



Neck & Chin

Case Study – VST#028-A

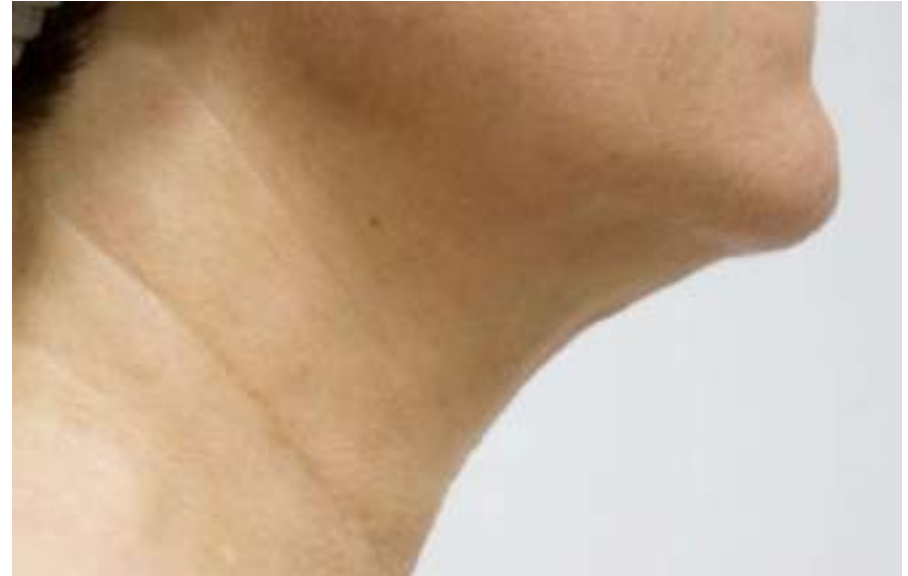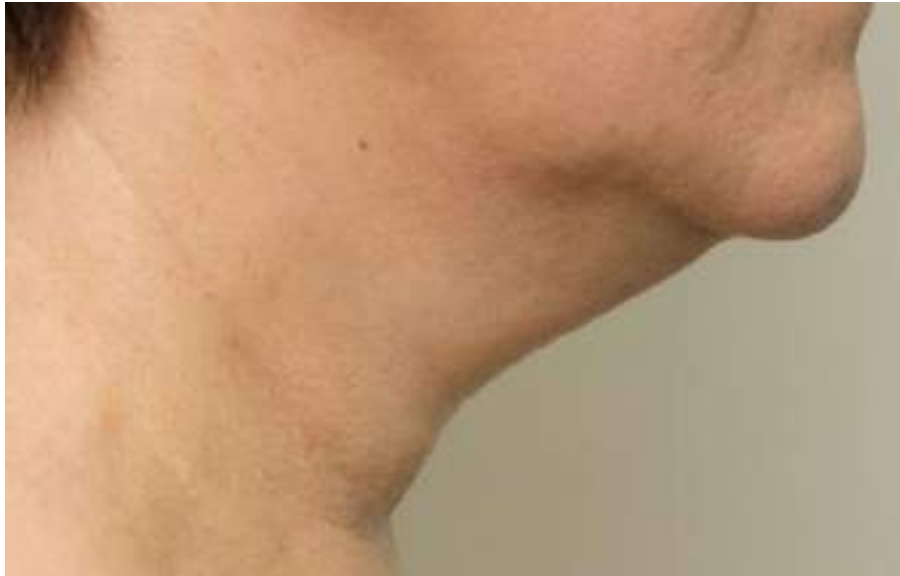Dr Elena Razumovskaya, Samara, Russia

Patient

Female, 59 years old

Number of Treatments

3 V-ST (Mode II and III, 60-85 J/cm³)



Before

After



Neck & Chin

Case Study – VST#028-B

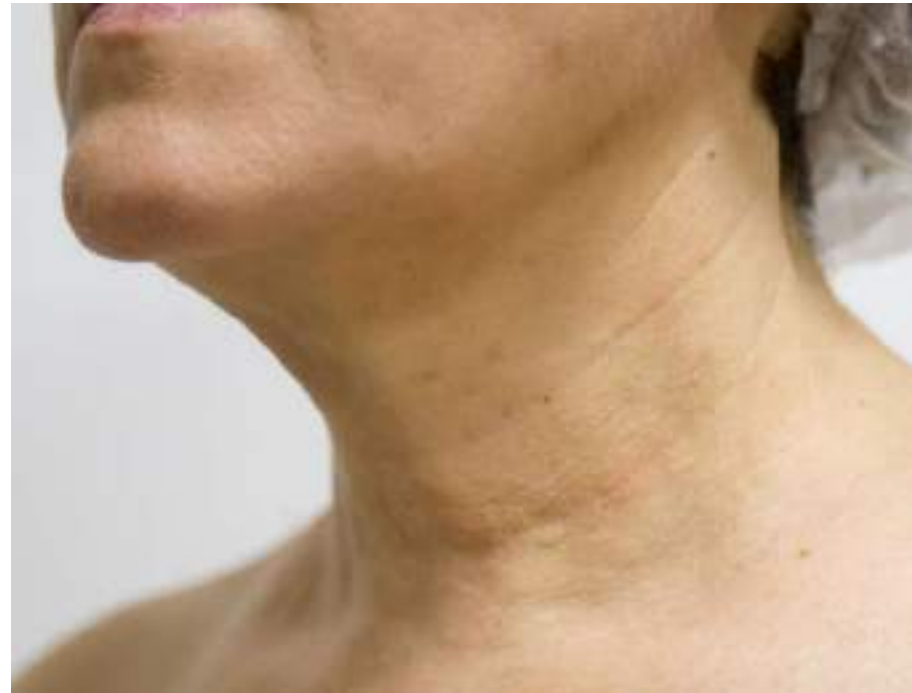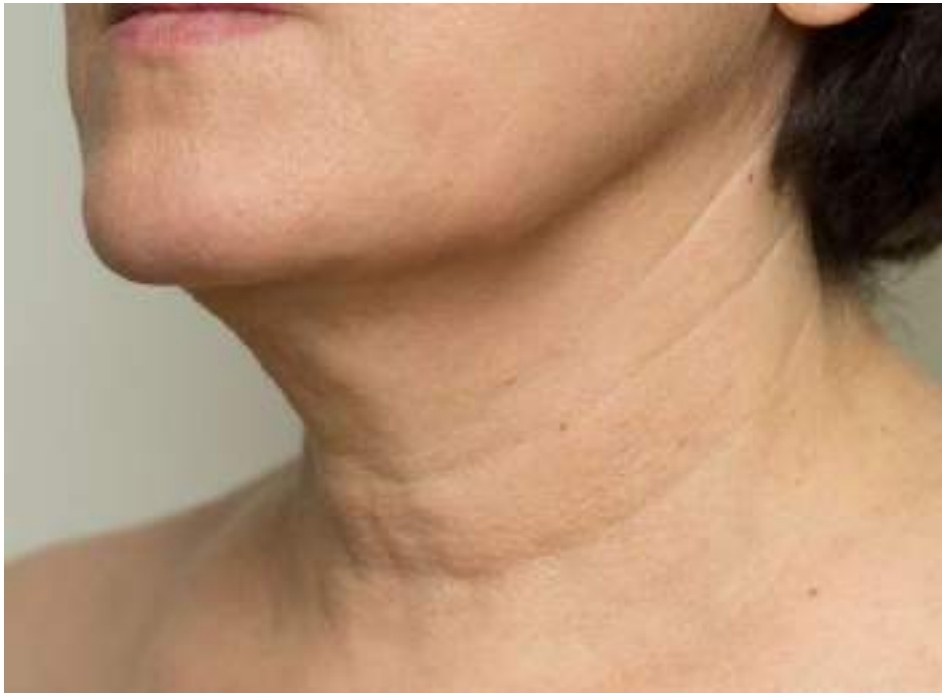Dr Elena Razumovskaya, Samara, Russia

Patient

Female, 59 years old

Number of Treatments

3 V-ST (Mode II and III, 60-85 J/cm³)



Before

After



Neck

Case Study – VST#028-C

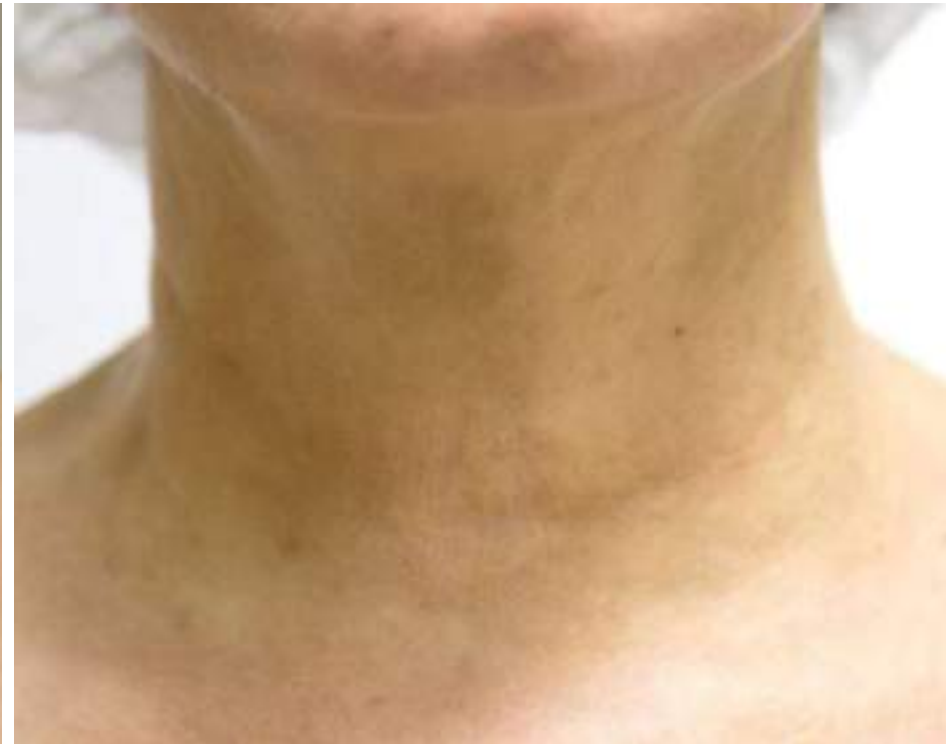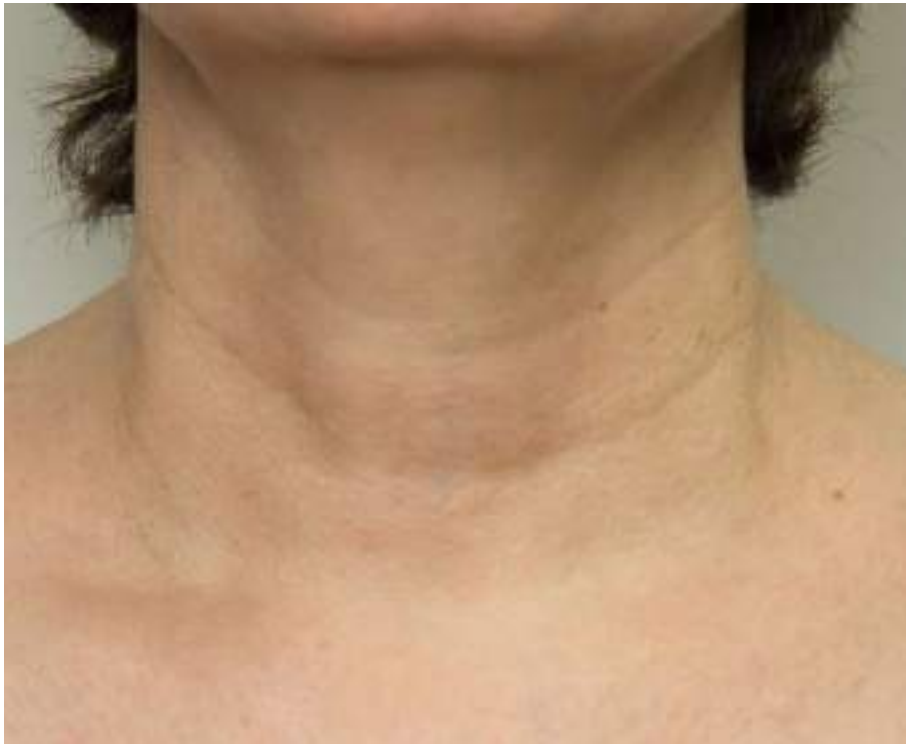Dr Elena Razumovskaya, Samara, Russia

Patient

Female, 59 years old

Number of Treatments

3 V-ST (Mode II and III, 60-85 J/cm³)



Before

After



Neck & Chin

Case Study – VST#029-A

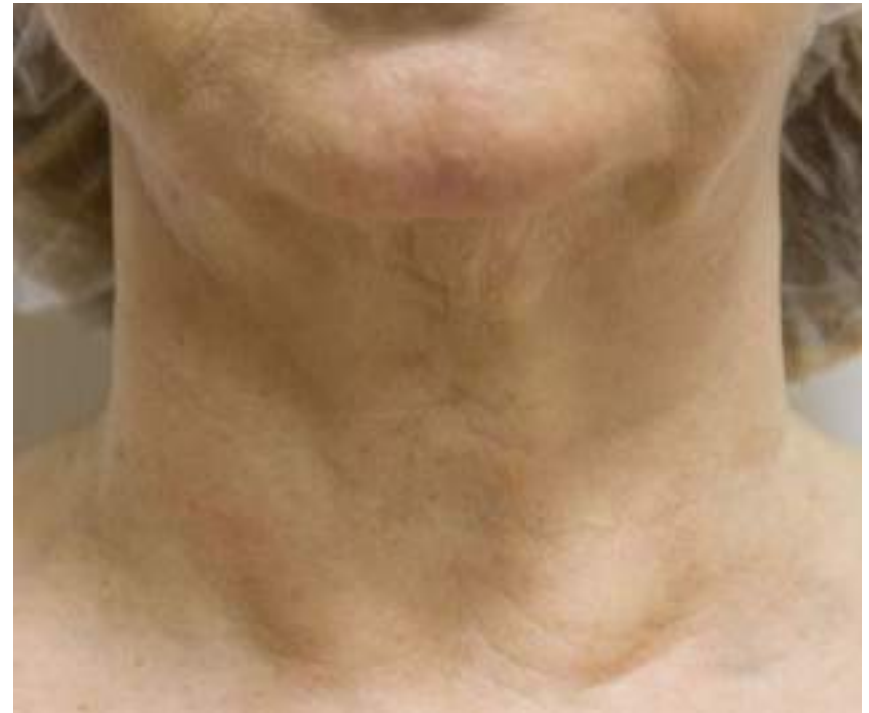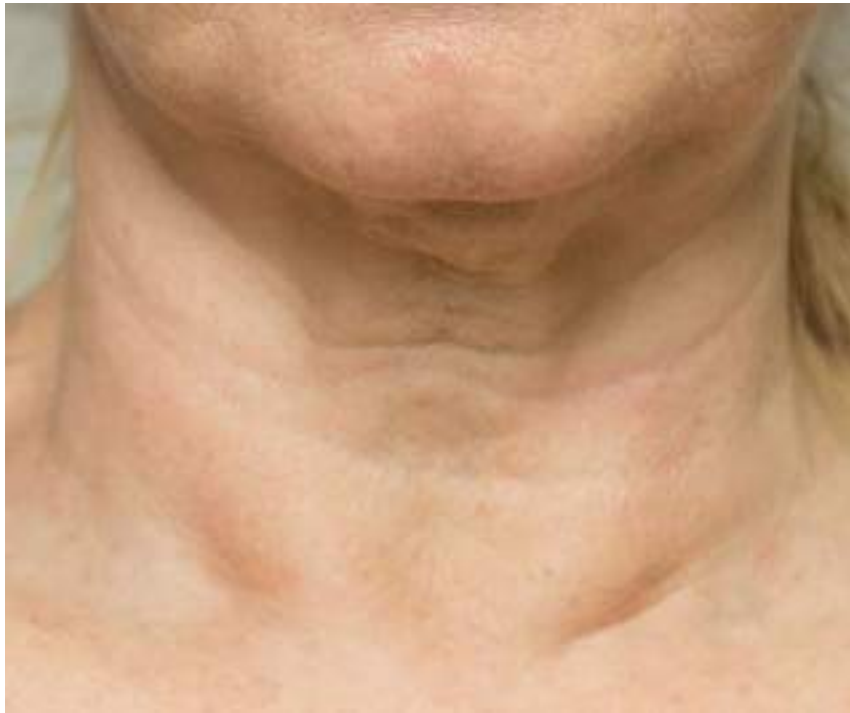Dr Elena Razumovskaya, Samara, Russia

Patient

Female, 60 years old

Number of Treatments

4 V-ST (Mode II and III, 60-85 J/cm³)



Before

After



Neck

Case Study – VST#029-B

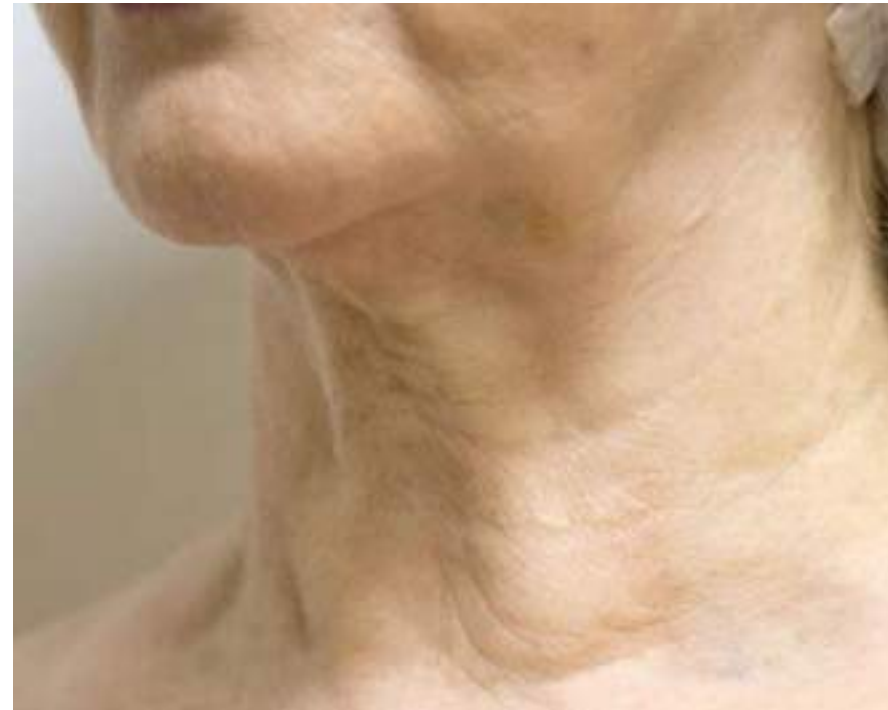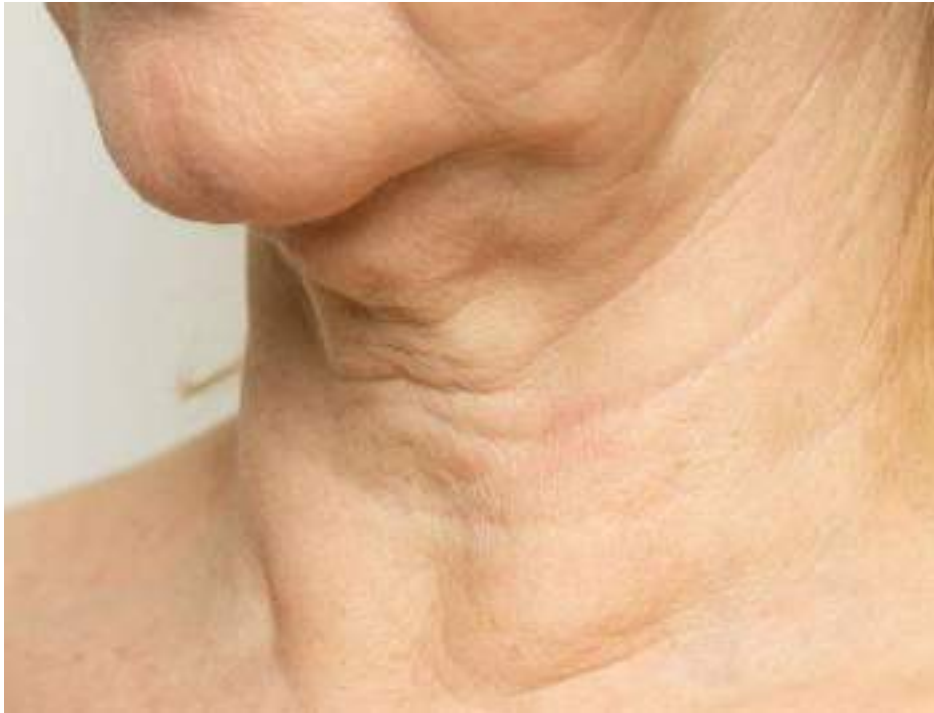Dr Elena Razumovskaya, Samara, Russia

Patient

Female, 60 years old

Number of Treatments

4 V-ST (Mode II and III, 60-85 J/cm³)



Before

After



Neck & Chin

Case Study – VST#029-C

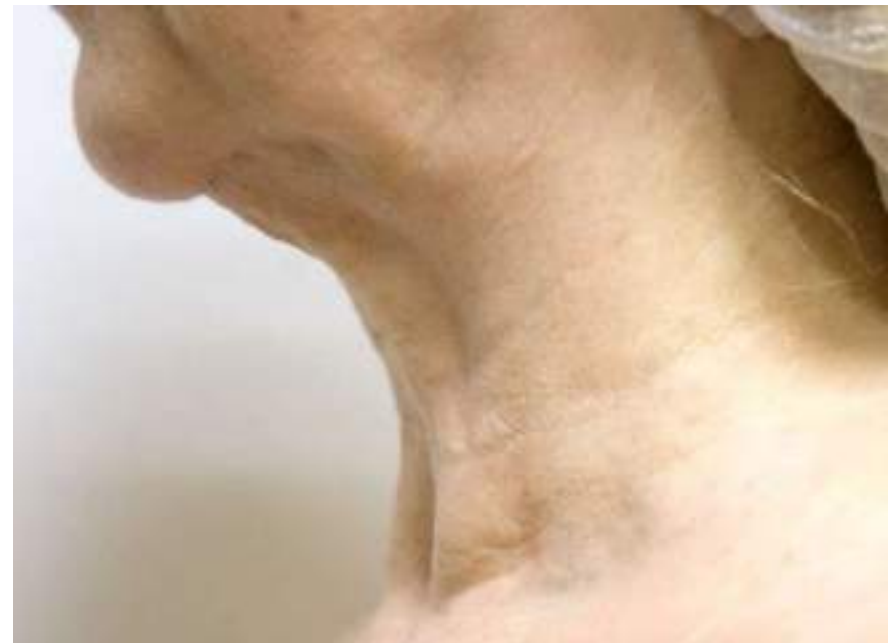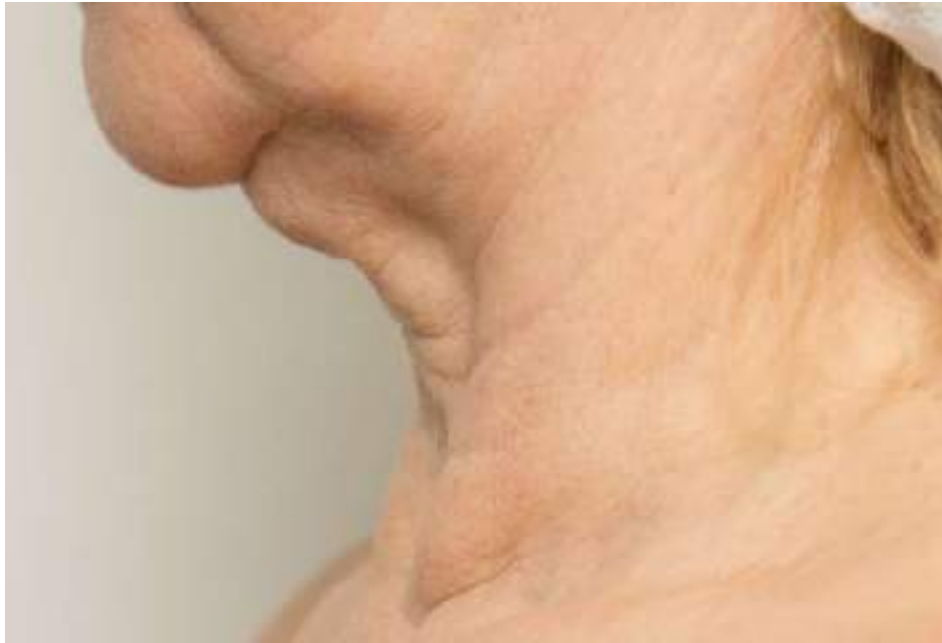Dr Elena Razumovskaya, Samara, Russia

Patient

Female, 60 years old

Number of Treatments

4 V-ST (Mode II and III, 60-85 J/cm³)



Before

After



Neck & Chin

Case Study – VST#031

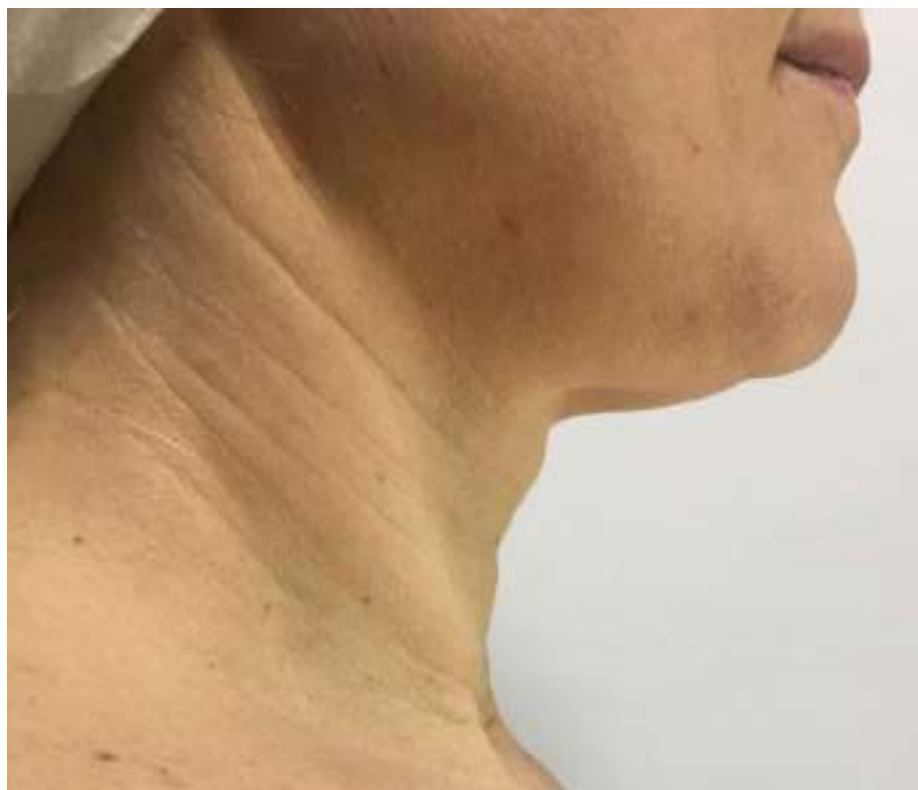Dr Elena Razumovskaya, Samara, Russia

Patient

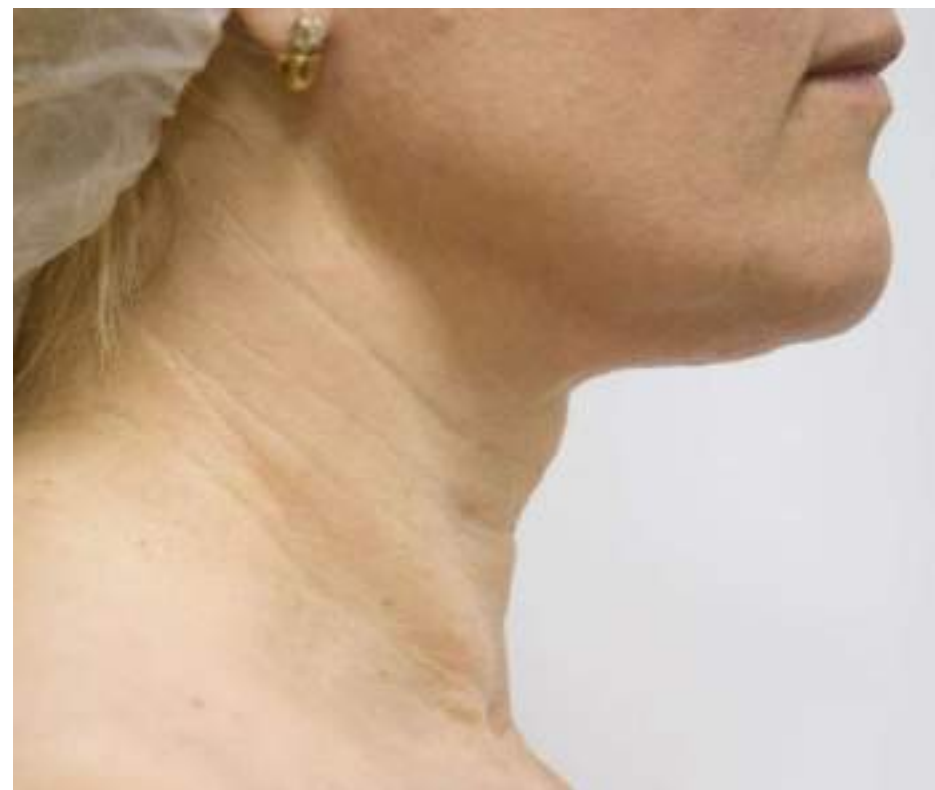Female, 50 years old

Number of Treatments

3 V-ST



Before



After



Neck & Chin

Case Study – VST#031

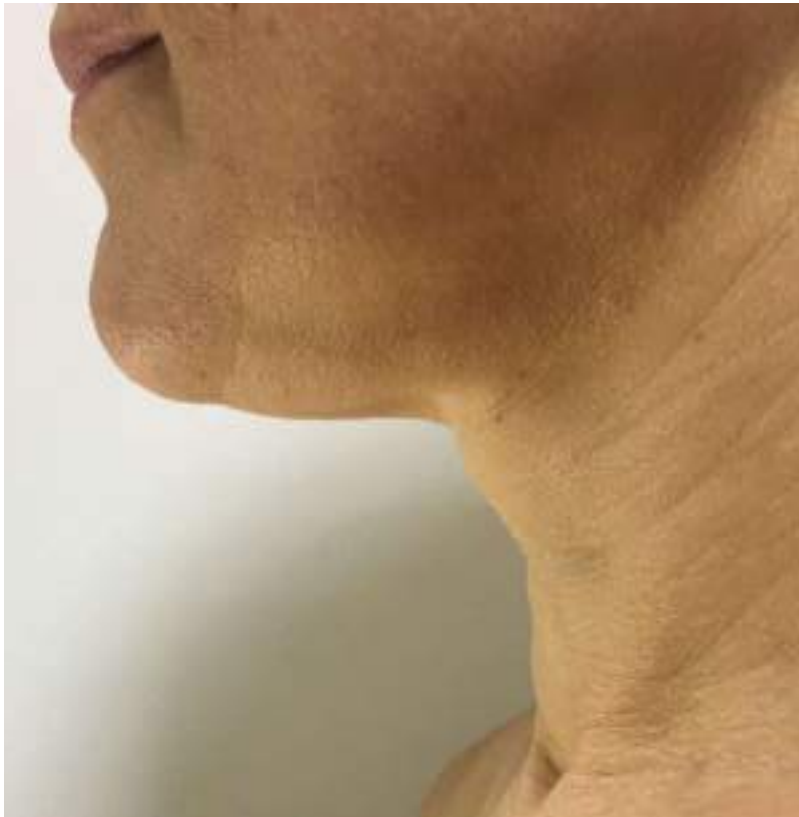Dr Elena Razumovskaya, Samara, Russia

Patient

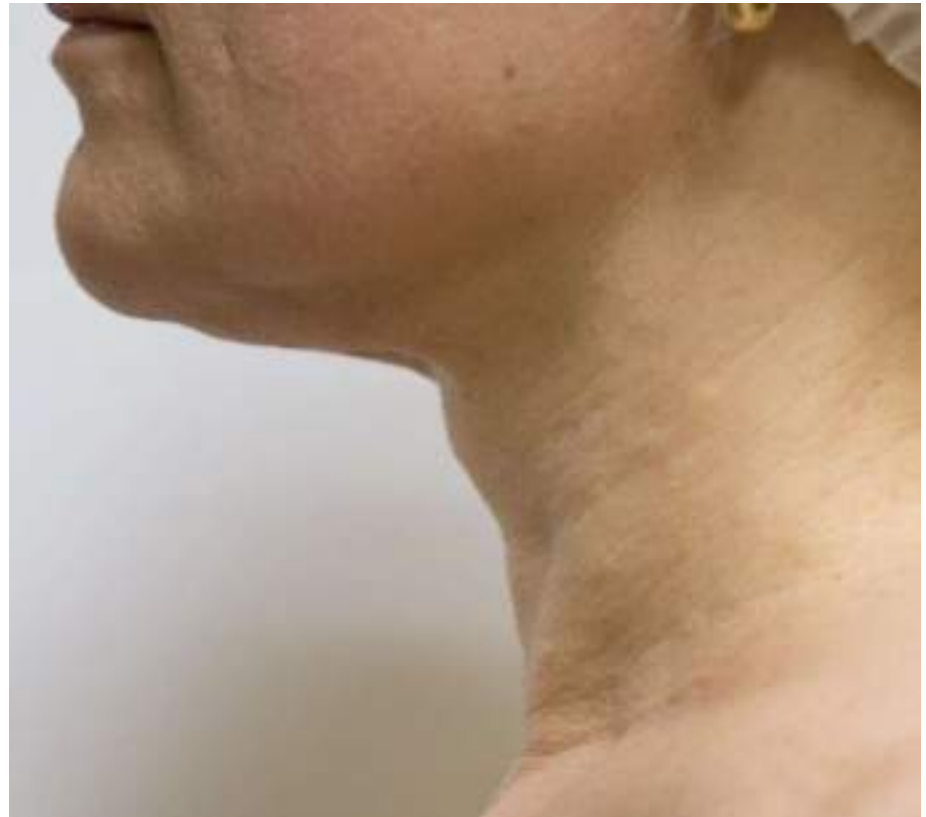Female, 50 years old

Number of Treatments

3 V-ST



Before



After



Lips


VIORA



Lips Rejuvenation

Case Study – VST#034

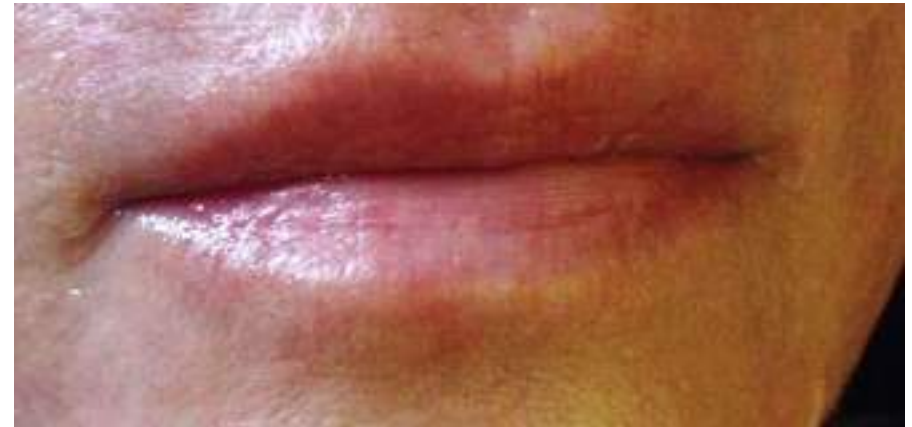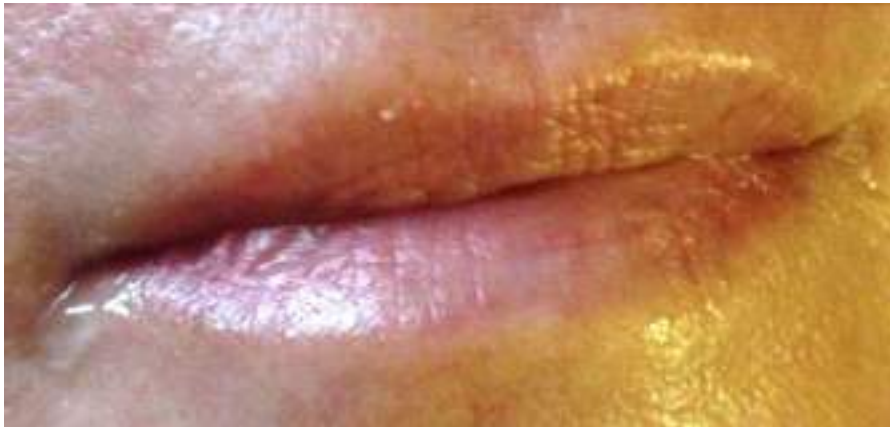Viora Inc., USA

Patient

Female, 50 years old

Number of Treatments

1 V-ST (Mode III, 70 J/cm³, 6 passes)



Before

Immediatly After



Lips Rejuvenation

Case Study – VST#035

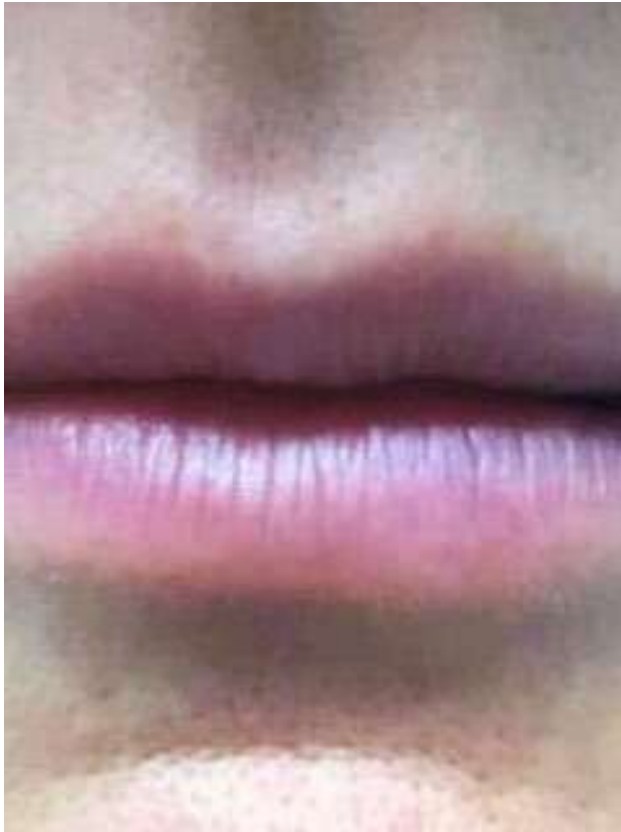Body Brite in Bayside, NY., NY, USA

Patient

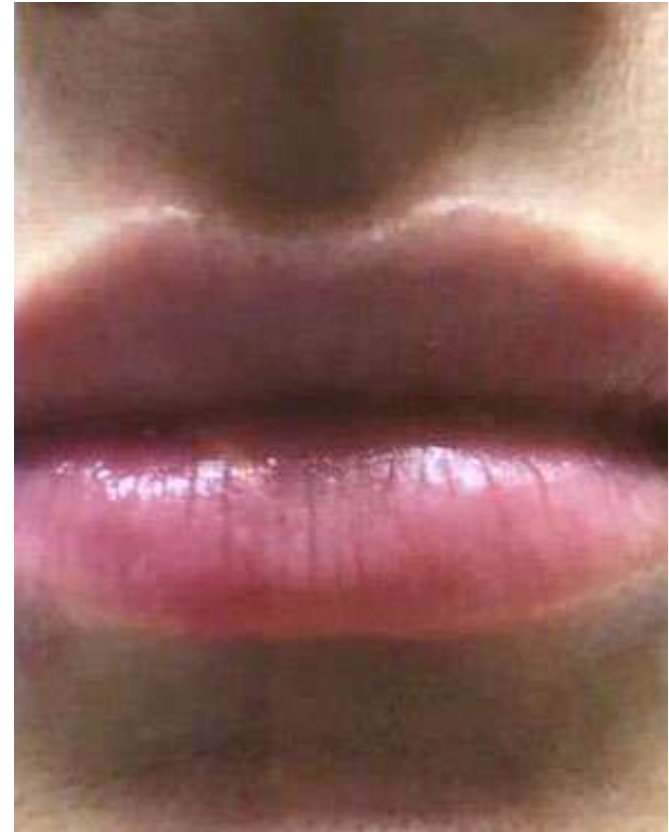
Female, 40 years old

Number of Treatments

1 V-ST (Mode III, 6 passes)



Before



30 min After



Lips Rejuvenation

Case Study – VST#039

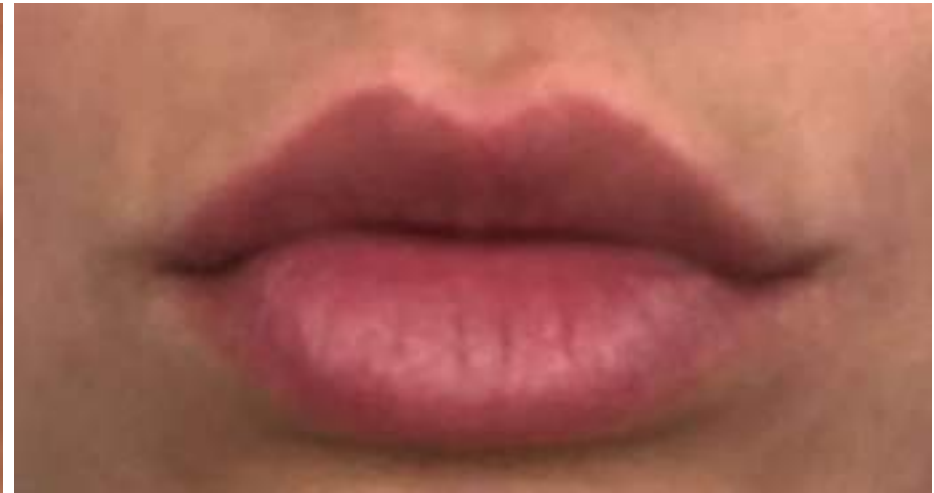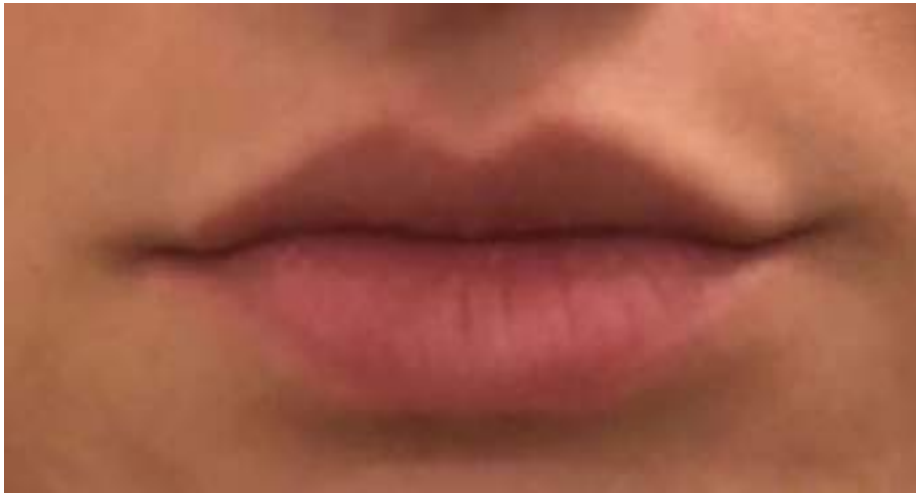Viora Inc., USA

Patient

Female, 34 years old

Number of Treatments

1 V-ST (Mode III, 6 passes)



Before

After



Lips Rejuvenation

Case Study – VST#039

Viora Inc., USA

Patient

Female, 34 years old

Number of Treatments

1 V-ST (Mode III, 6 passes)

Before

After



Neck and chin

Décolleté

Case Study – RE#208

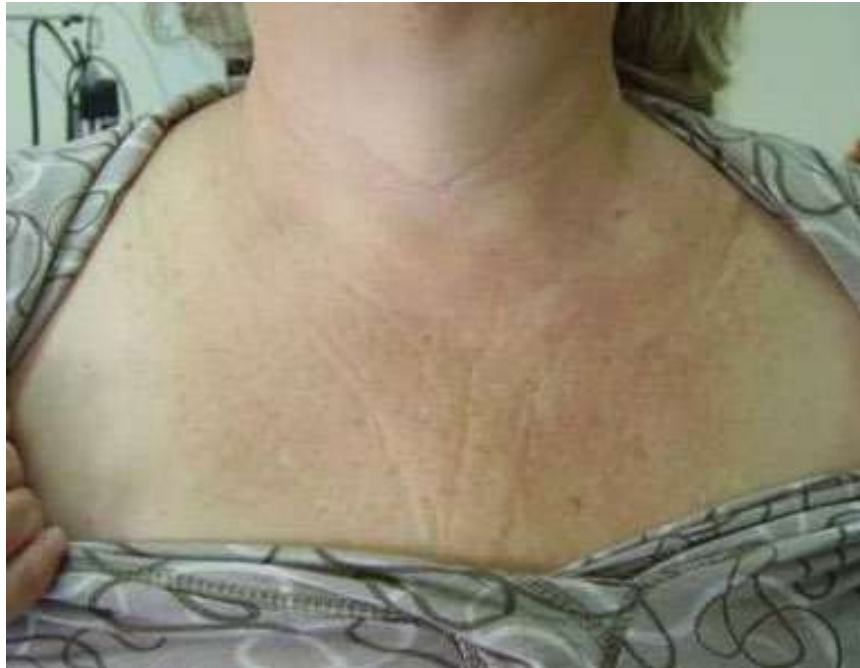Keren Or Medical Aesthetic Center

Patient

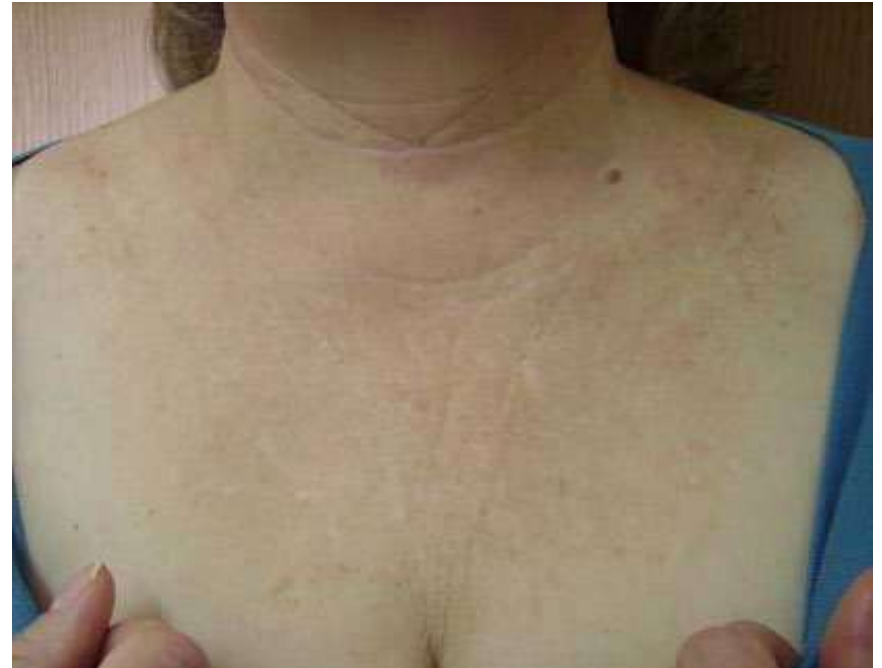Female

Number of Treatments

7 V-ST



Before



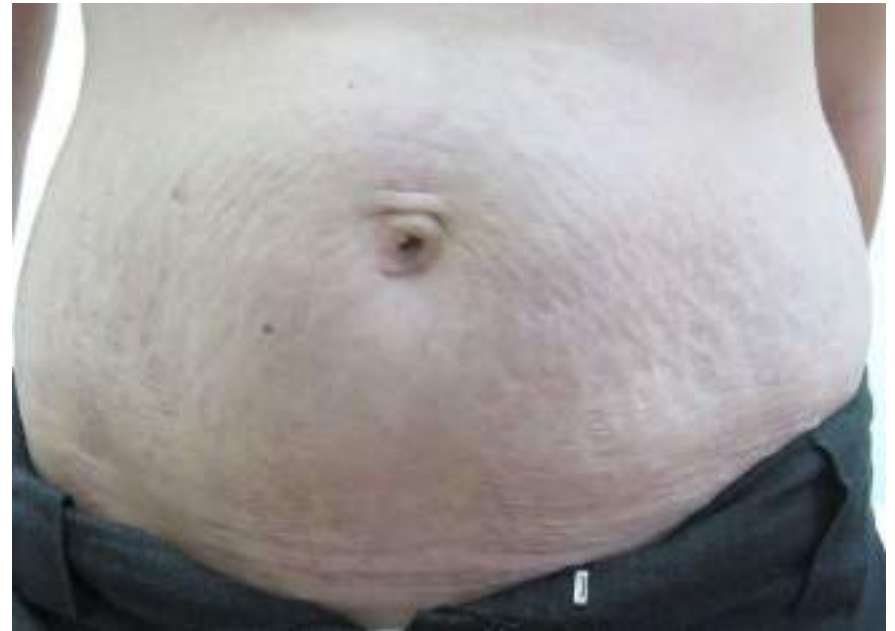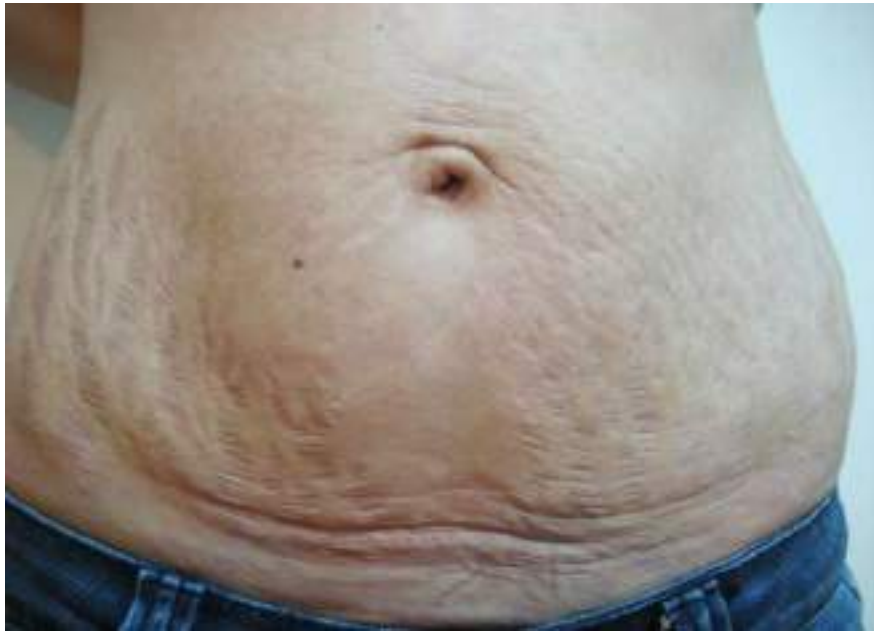After

Stretch Marks and Scars



Stretch Marks & Sagging skin

Case Study – RE#215	Viora Ltd.
Patient	Female
Number of Treatments	5 V-ST



Before

After





Stretch Marks

Case Study – RE#118

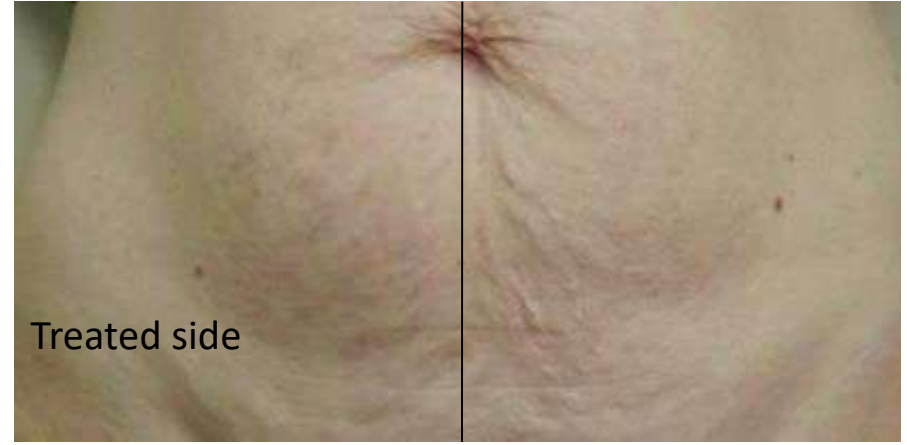
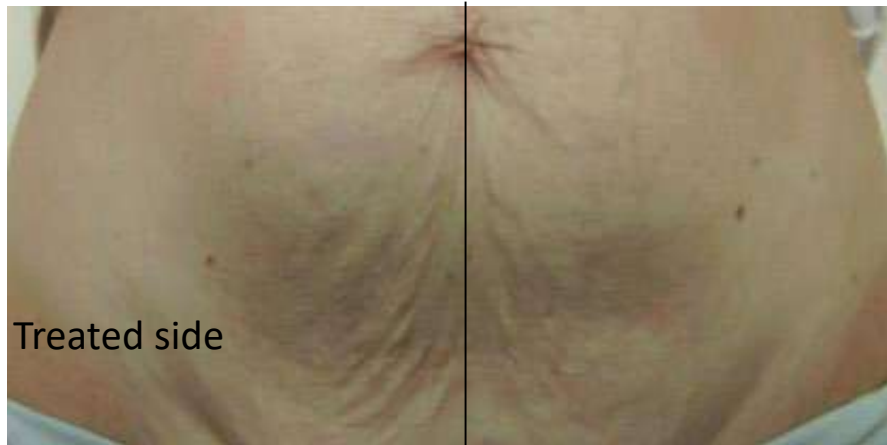Keren Or Medical Aesthetic Center

Patient

Female, 40 years old

Number of Treatments

3 V-ST (Mode IV, 6 passes)



Before

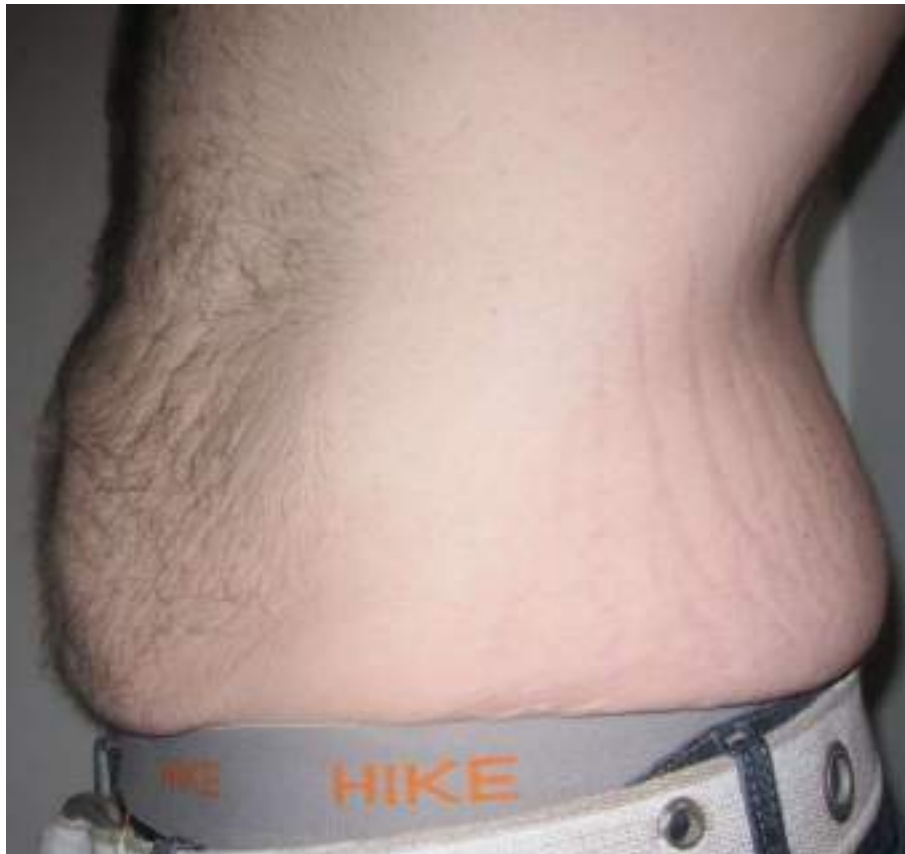1 month After



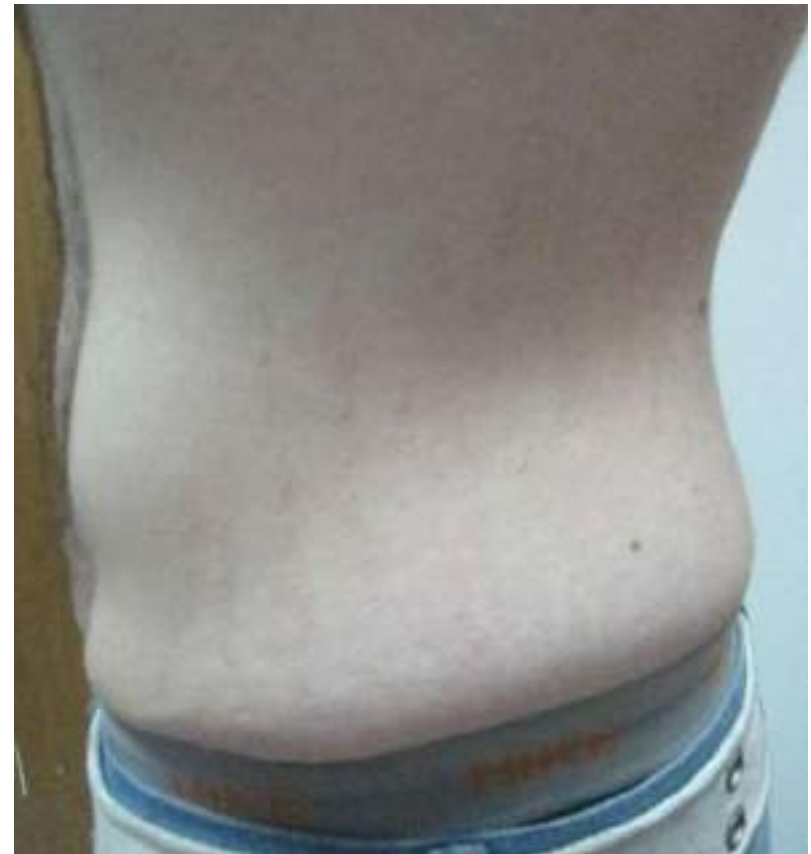

Stretch Marks

Case Study – RE #167	Viora Ltd.
Patient	Male, 28 years old
Number of Treatments	8 V-ST (After ReFit)



Before

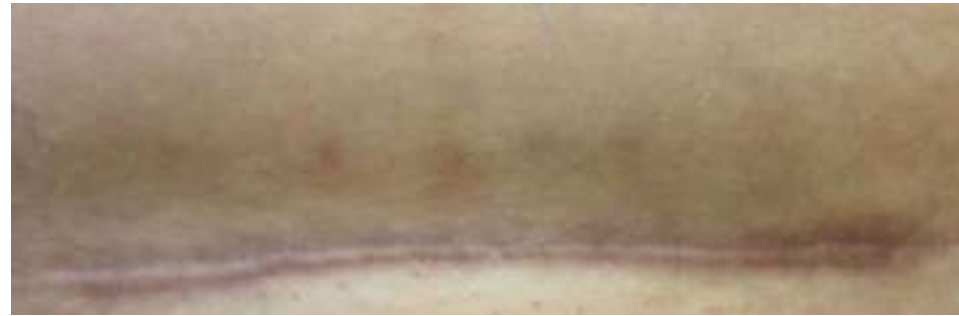
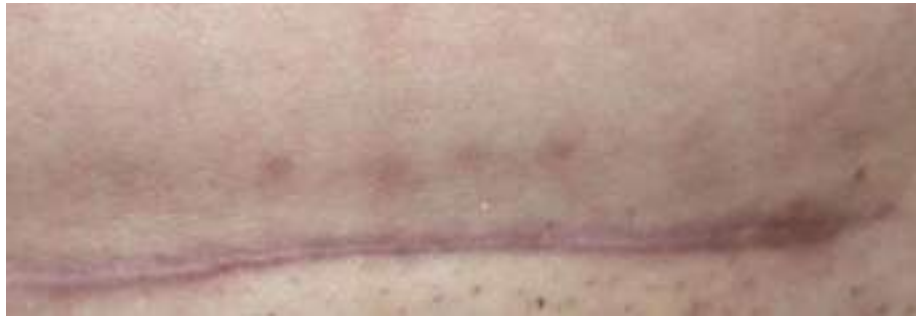

After



Post Cesarean Scar

Case Study – RE#302	Dr. Inna Belenky, Viora Ltd.
Patient	Female, 33 years old
Number of Treatments	4 V-ST



Before

After

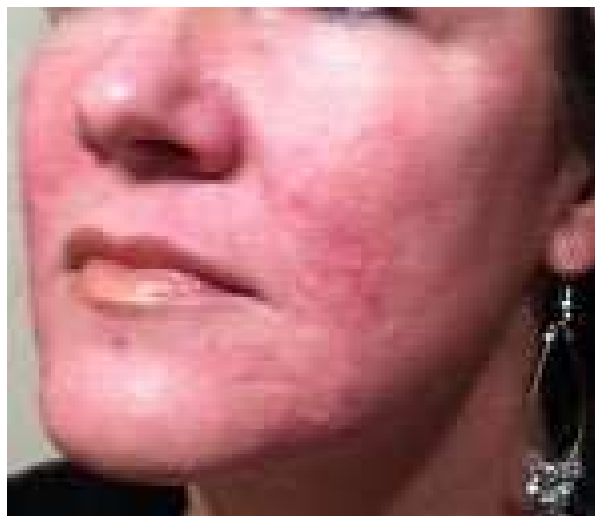

P. Acne

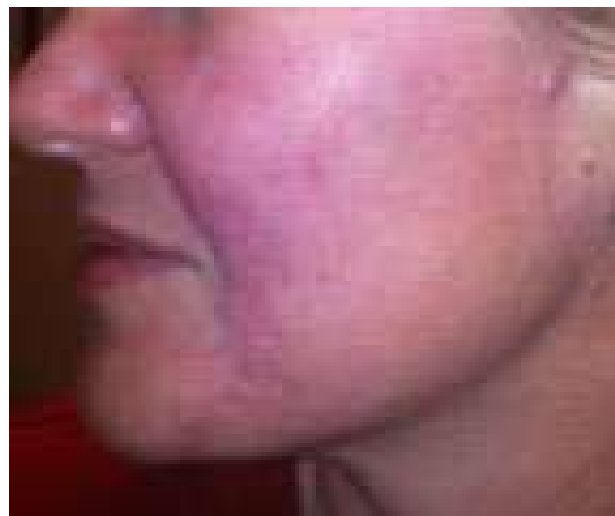
VIORA

P. Acne

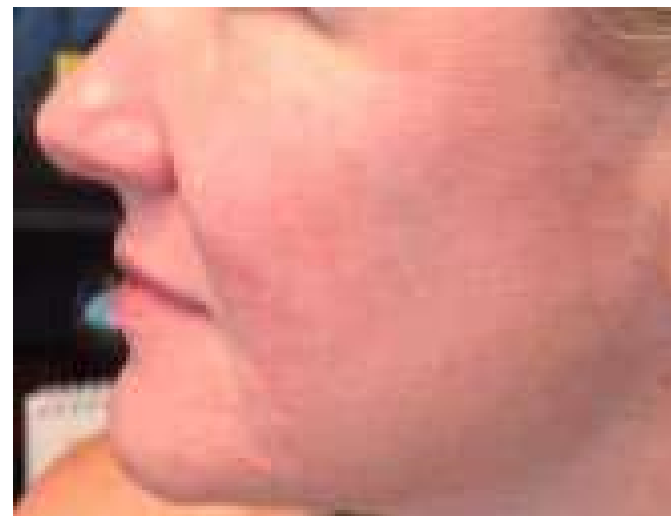
Case Study – RE#323-A	Lorri Thurmond, Viora Inc. USA
Patient	Female, 42 years old
Number of Treatments	5 V-ST



Before



After 3 Tx

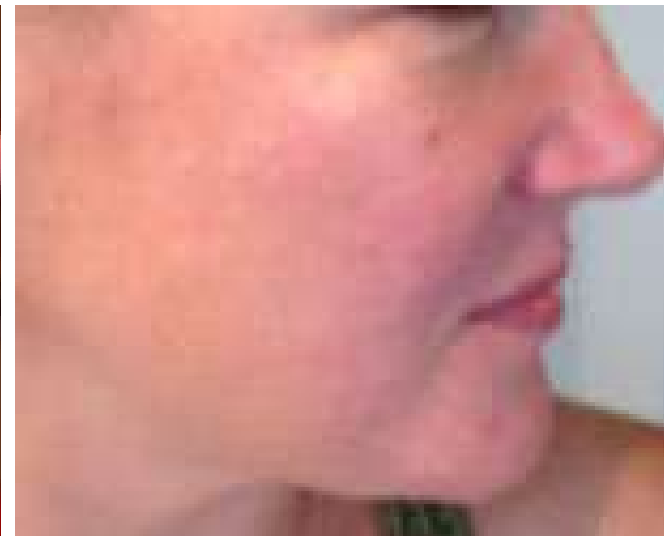
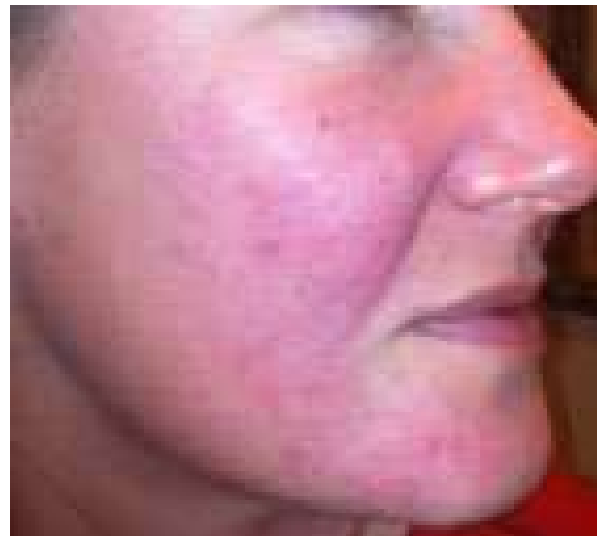
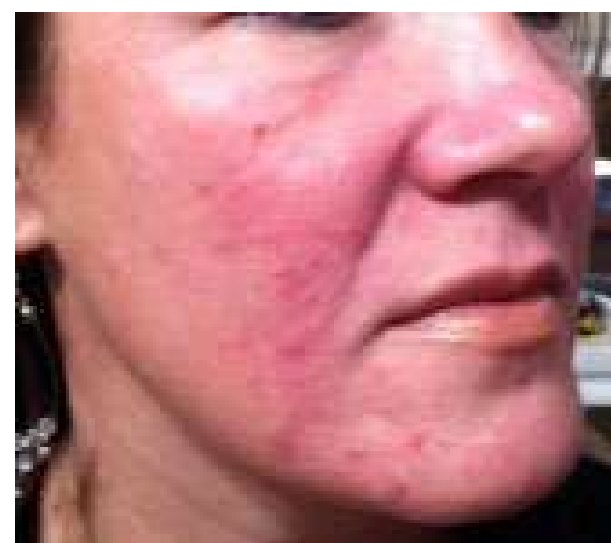After 5 Tx



P. Acne

Case Study – RE#323-B	Lorri Thurmond, Viora Inc. USA
Patient	Female, 42 years old
Number of Treatments	5 V-ST



Before

After 3 Tx

After 5 Tx



**In combination with other
Technologies**



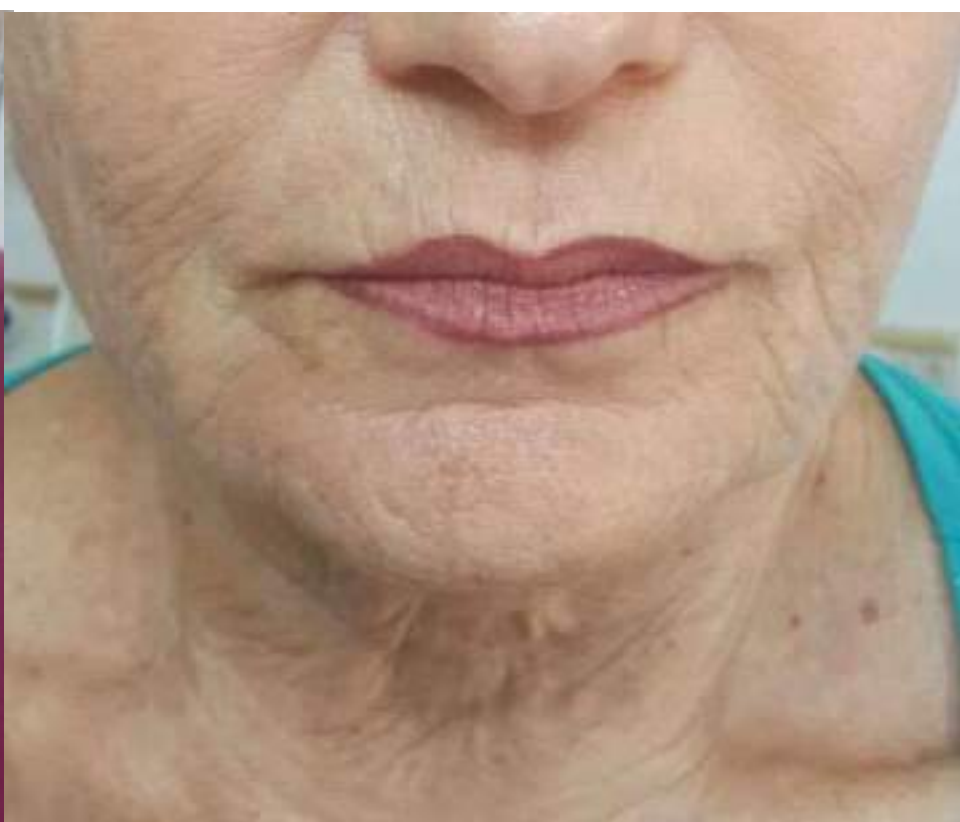
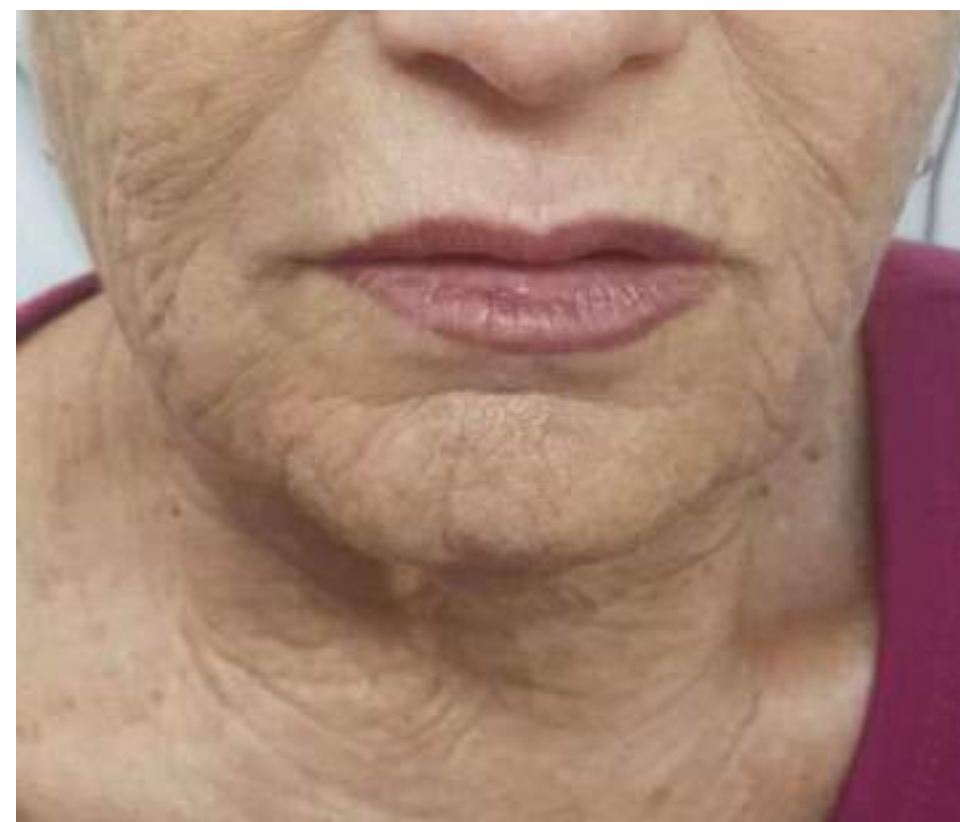
**V-ST &
IPL, Microdermabrasion,
Peelings**



Photoaging

Case Study – CO#007-A	Rachel Ben Eyar, Israel
Patient	Female, 67 years old
Number of Treatments	6 V-ST + 3 V-IPL + 2 medium peelings



Before

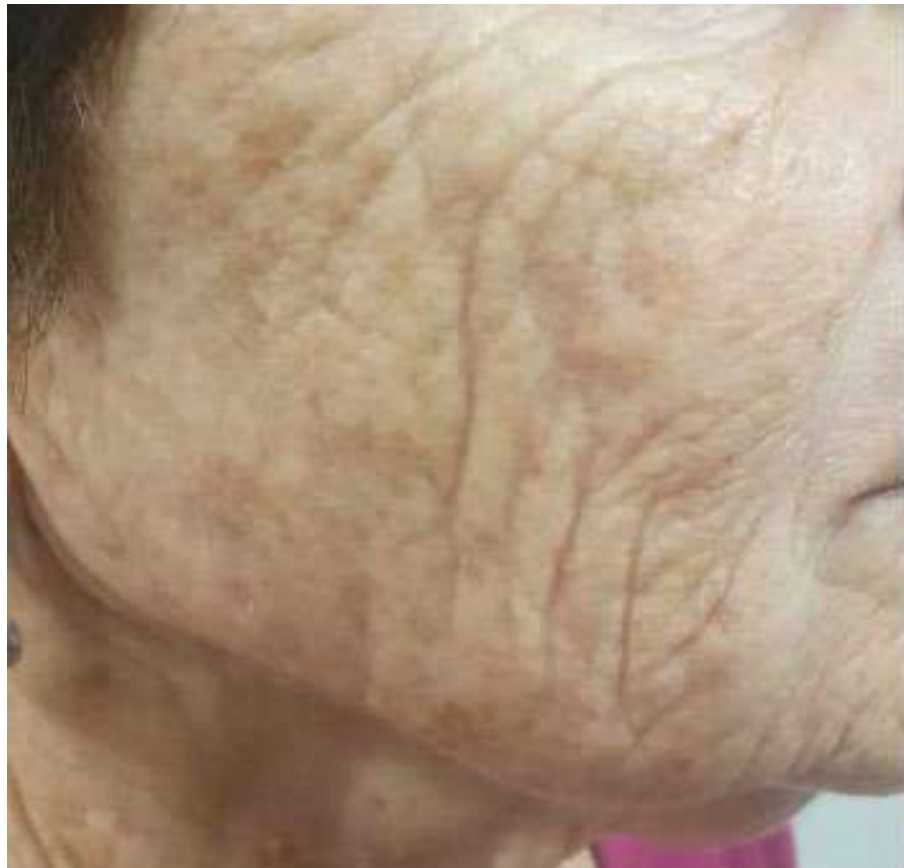After



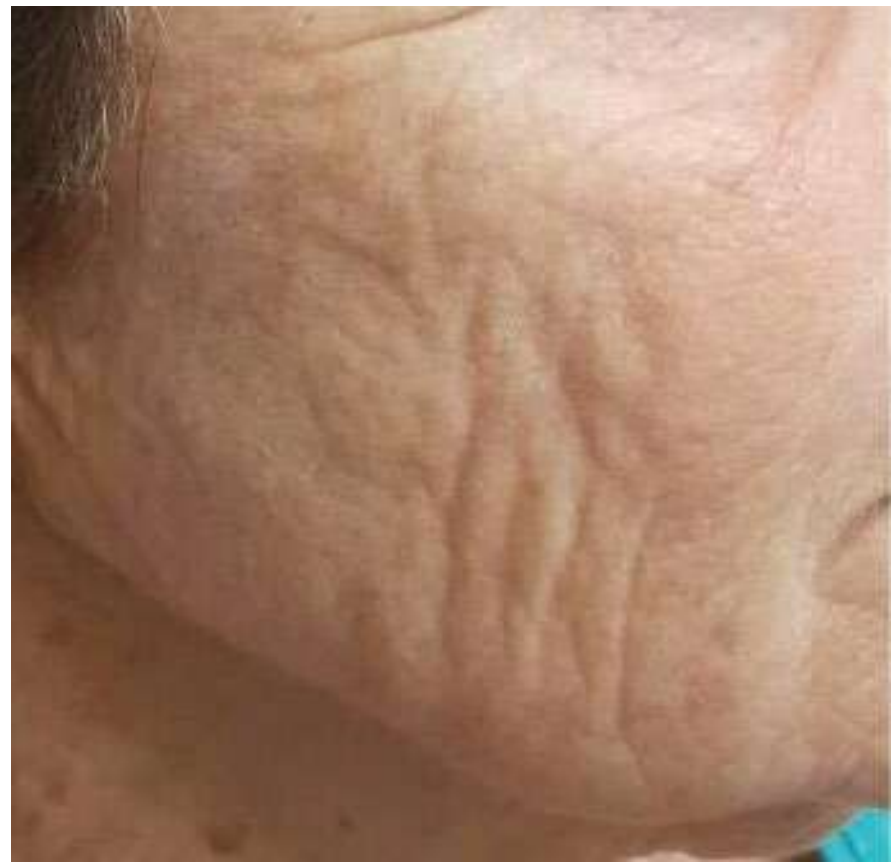

Photoaging

Case Study – CO#007-B	Rachel Ben Eyar, Israel
Patient	Female, 67 years old
Number of Treatments	6 V-ST + 3 V-IPL + 2 medium peelings



Before



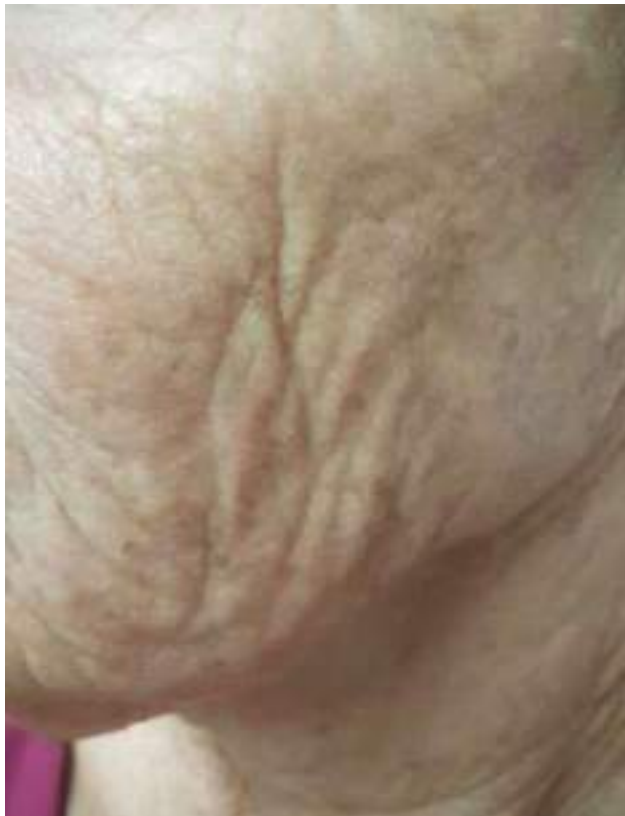After



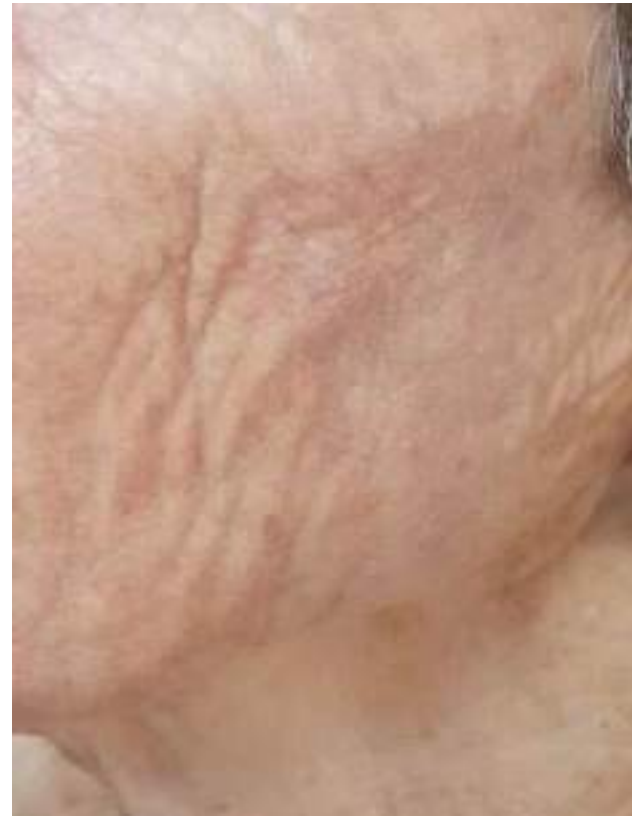

Photoaging

Case Study – CO#007-C	Rachel Ben Eyar, Israel
Patient	Female, 67 years old
Number of Treatments	6 V-ST + 3 V-IPL + 2 medium peelings



Before



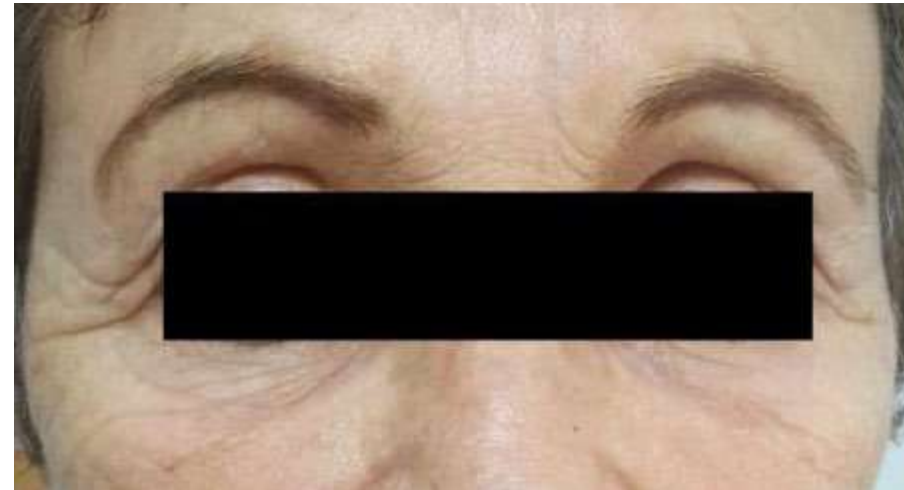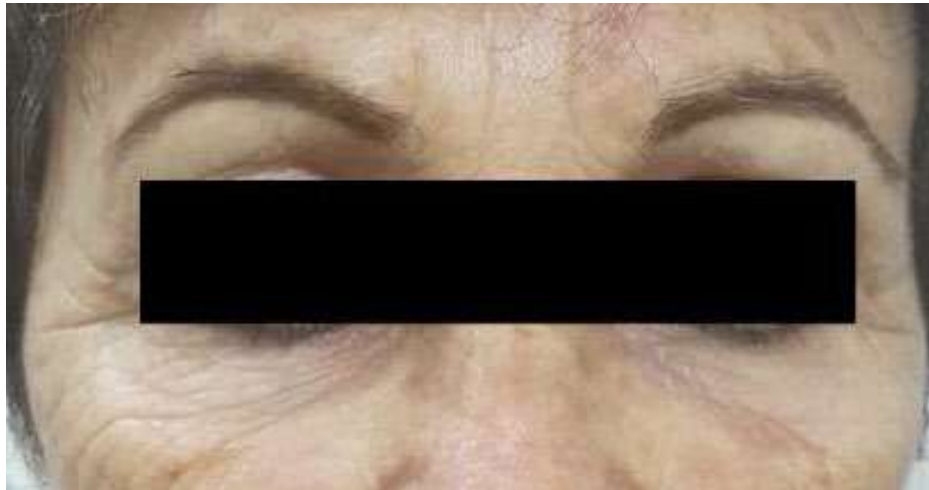After





Photoaging

Case Study – CO#007-D	Rachel Ben Eyar, Israel
Patient	Female, 67 years old
Number of Treatments	6 V-ST + 3 V-IPL + 2 medium peelings



Before

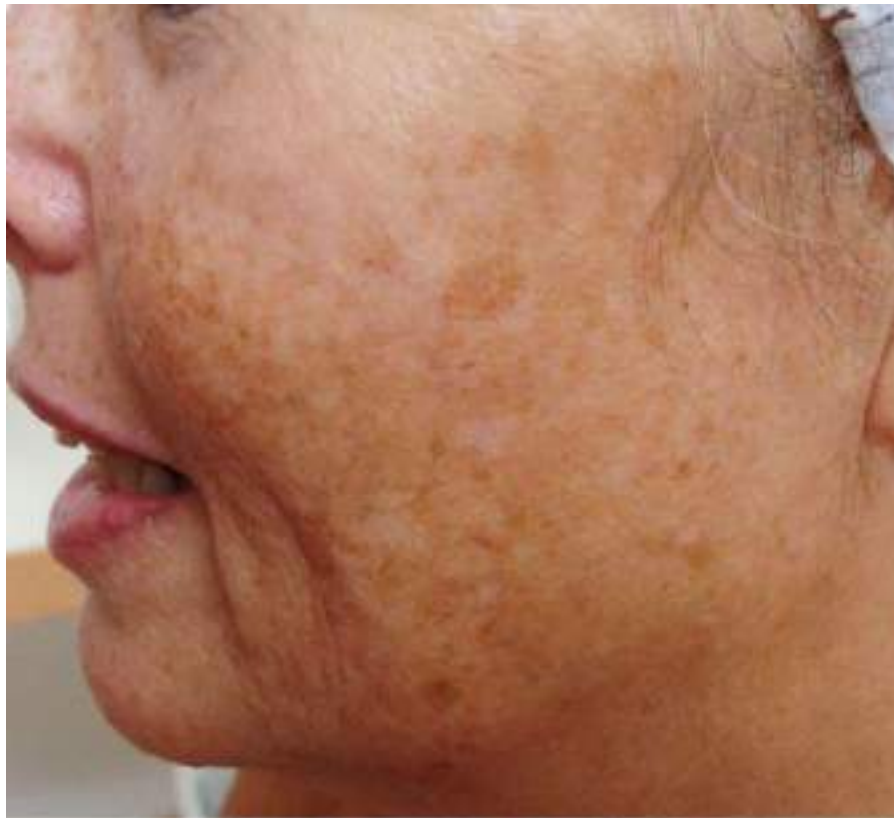After



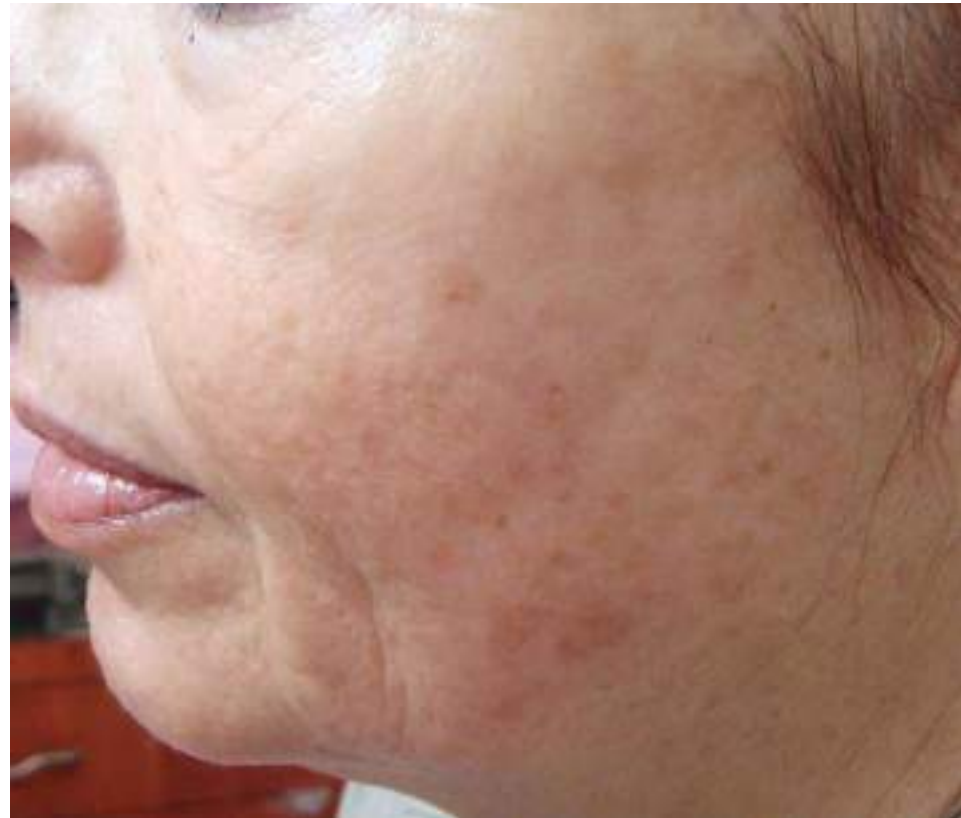

Photoaging

Case Study – CO#008-A	Rachel Ben Eyar, Israel
Patient	Female, 63 years old
Number of Treatments	5 V-ST + 4 V-IPL + 3 medium peelings



Before

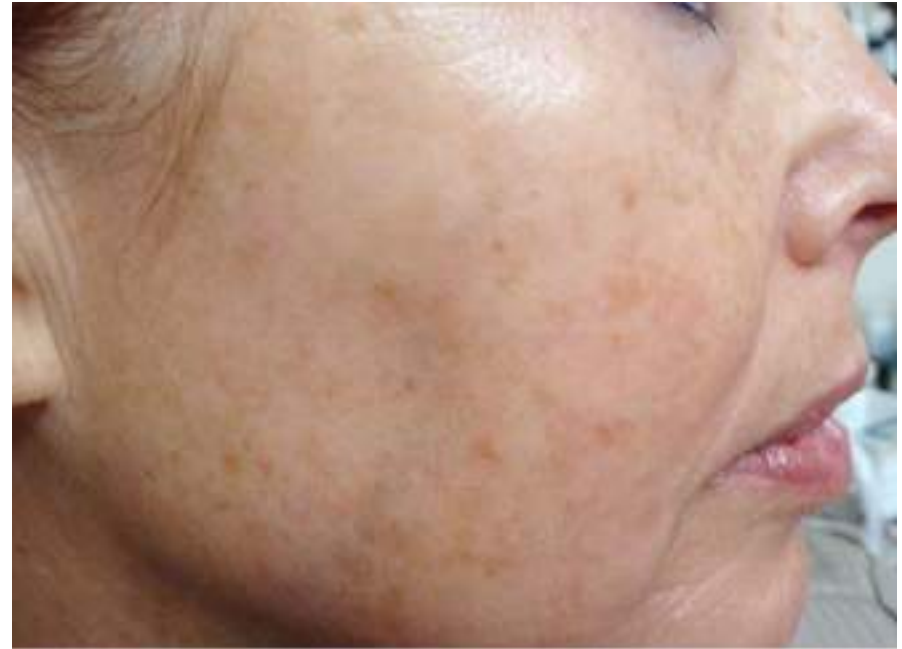
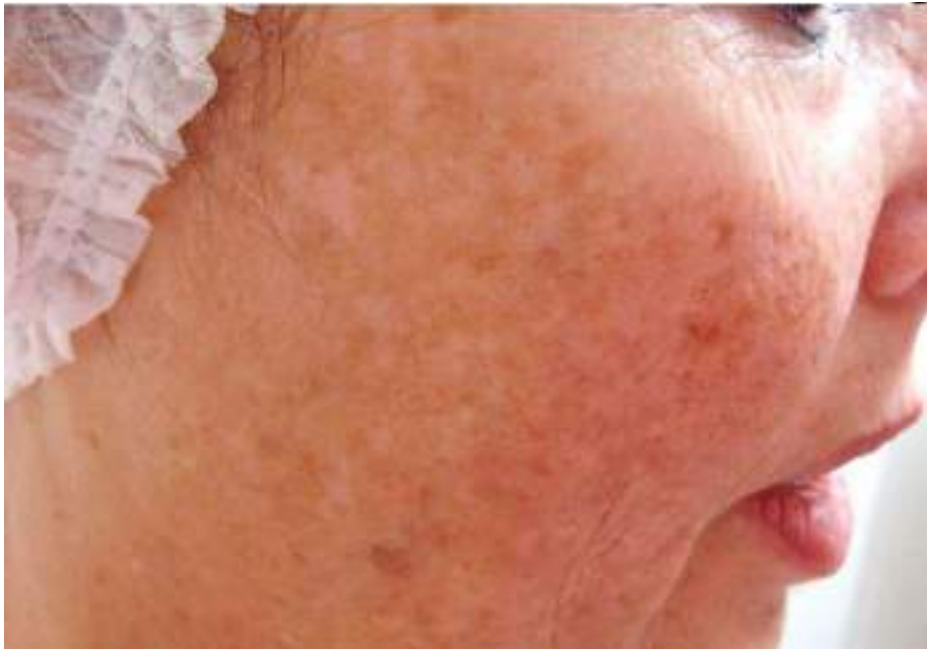
After



Photoaging

Case Study – CO#008-B	Rachel Ben Eyar, Israel
Patient	Female, 63 years old
Number of Treatments	5 V-ST + 4 V-IPL + 3 medium peelings



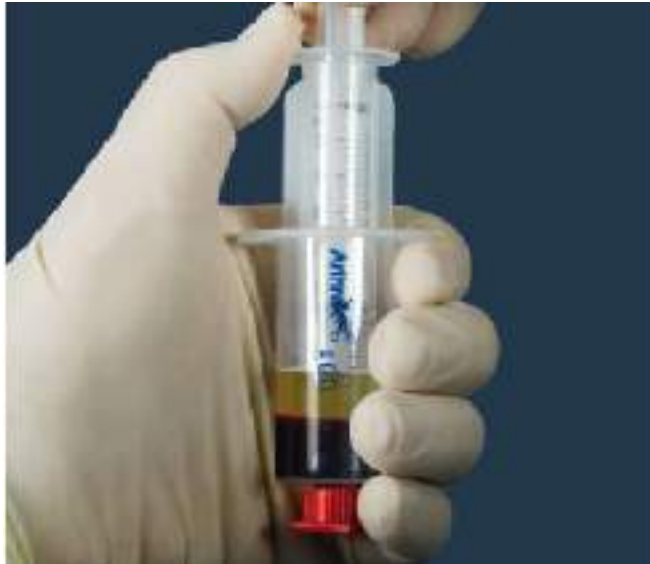Before

After



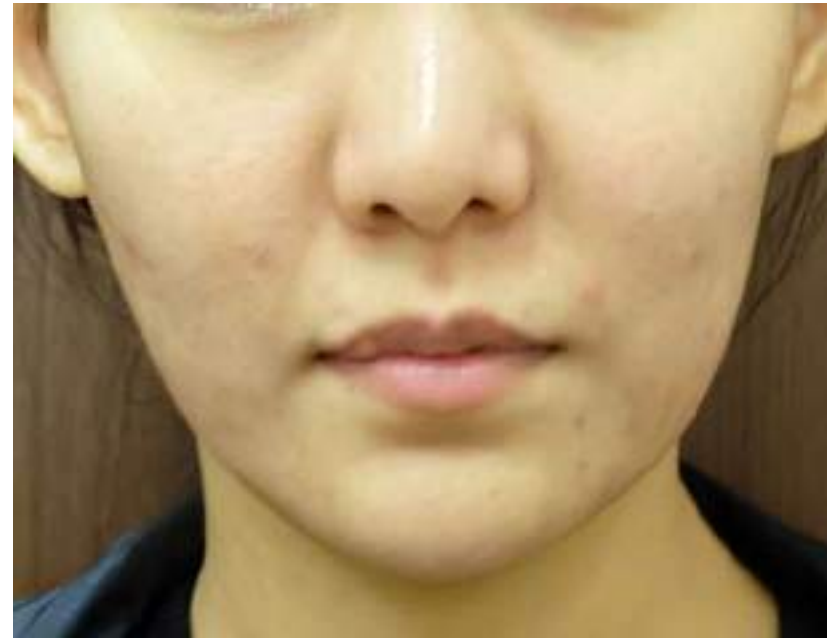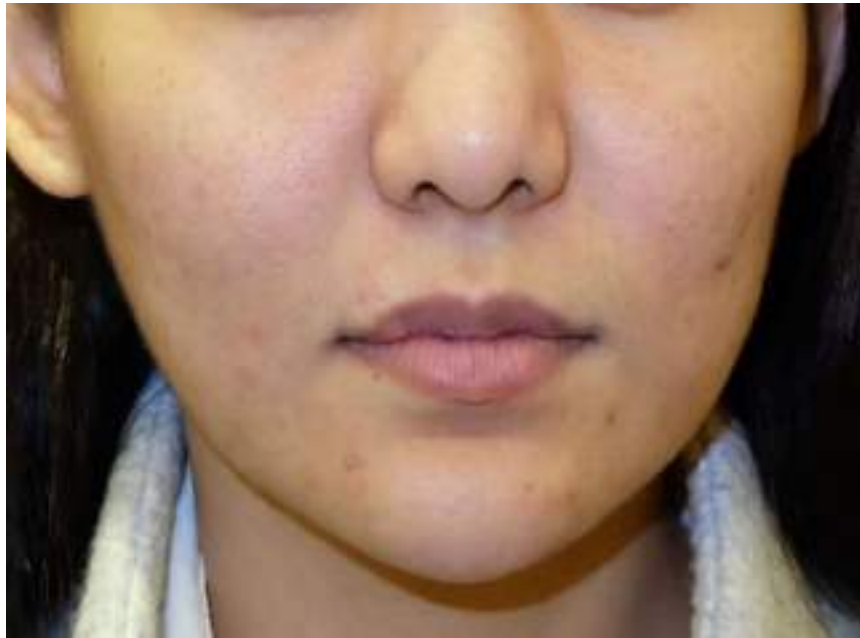- Mesotherapy
- Carboxytherapy
- Platelet Rich Plasma (PRP)
- Fillers
- Meso-threads

V-ST (CORE) & Injections



V-ST and Lipo-Injection

Case Study – VST#012	Viora Ltd., China
Patient	Female, 26 years old
Number of Treatments	2 V-ST and 10 ml lipo-injection on each side



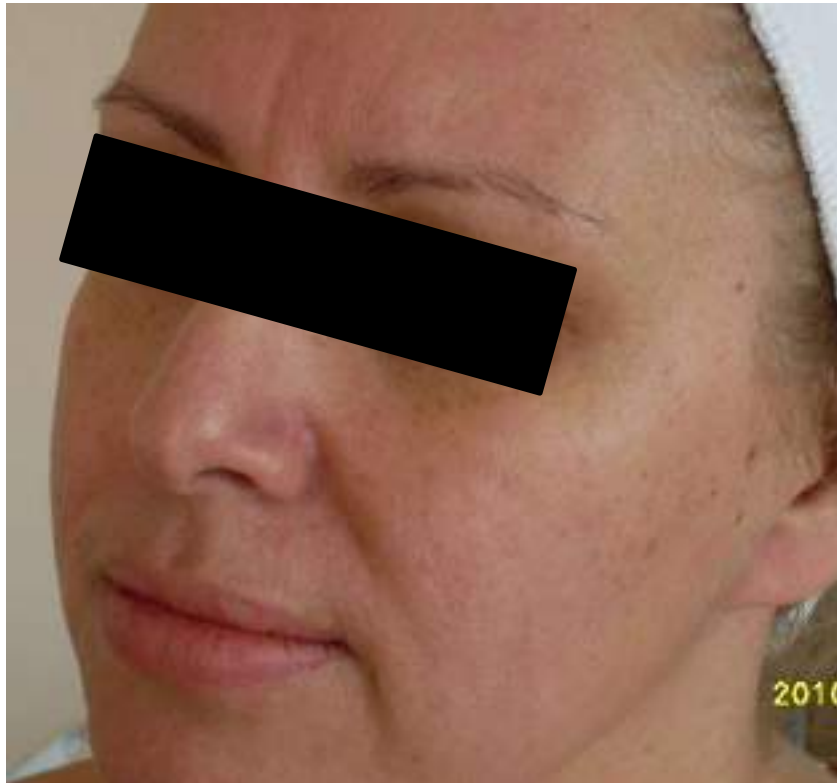Before

After

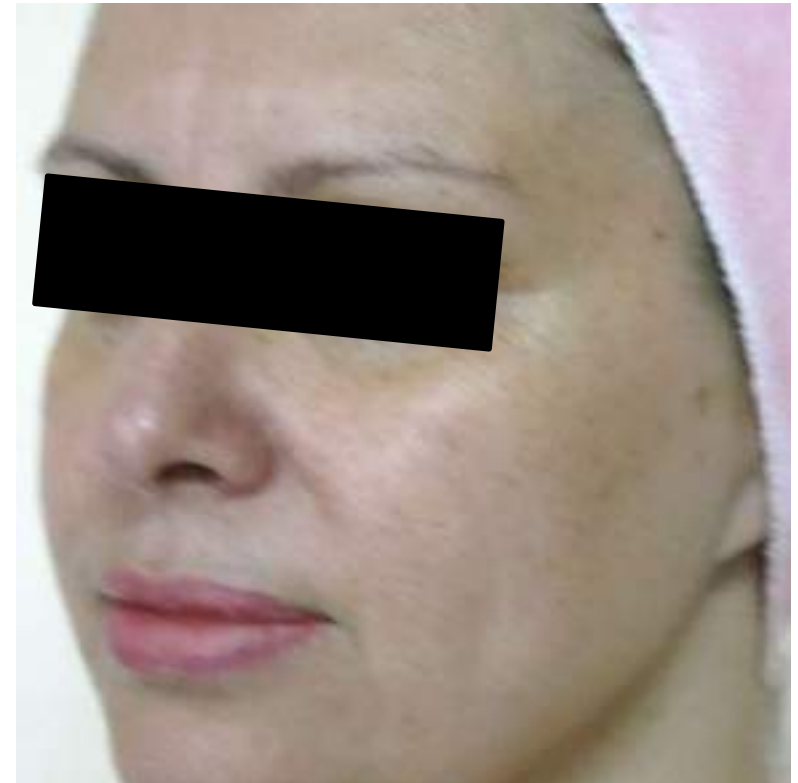

V-ST and Mesotherapy (Aesthetic Dermal)

Case Study – VST#022	Dr Marina Vaskevich, Toronto, Canada
Patient	Female, 42 years old
Number of Treatments	4 V-ST , one mesotherapy before V-ST



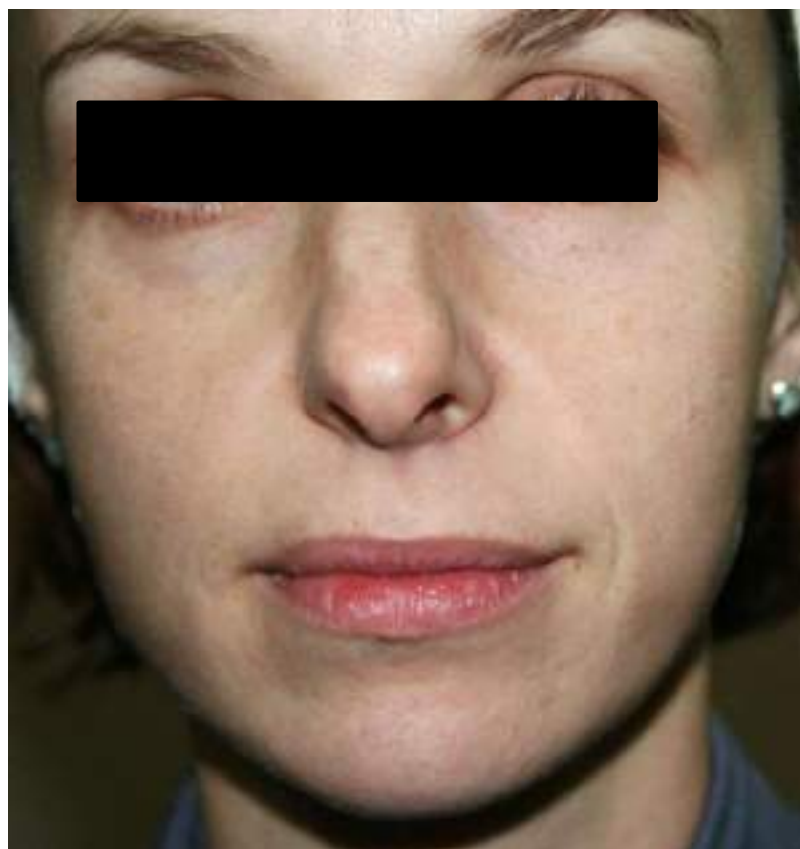Before



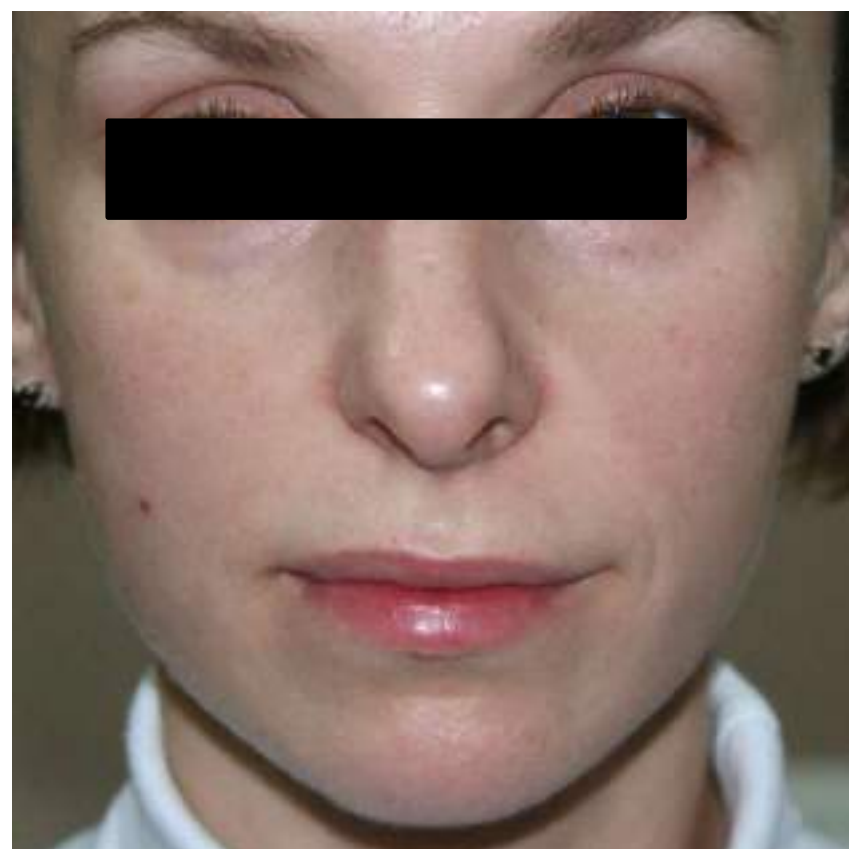
After

V-ST and Mesotherapy (Aesthetic Dermal)

Case Study – VST#024	Dr Marina Vaskevich, Toronto, Canada
Patient	Female, 36 years old
Number of Treatments	6 V-ST, 4 mesotherapy between V-ST



Before



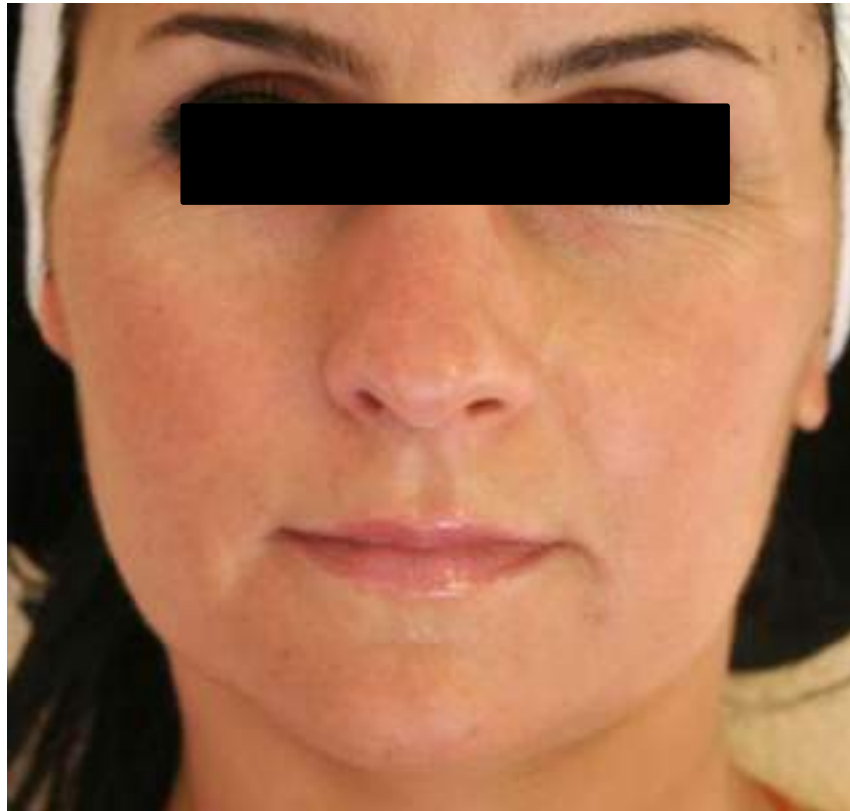After



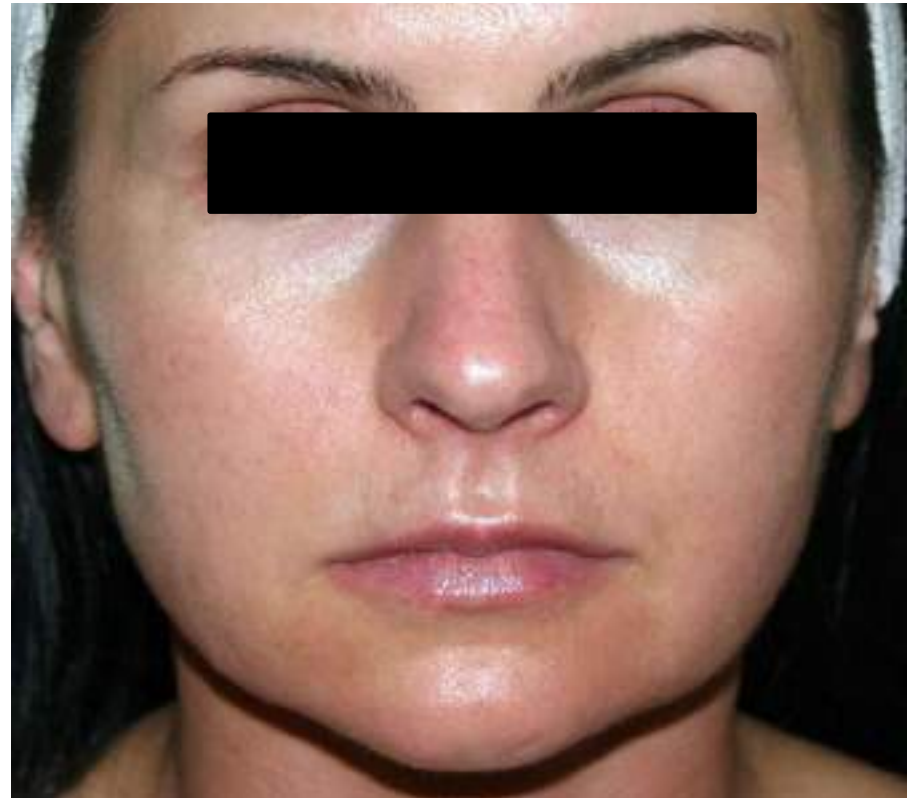

V-ST and Filler

Case Study – VST#023	Dr Marina Vaskevich, Toronto, Canada
Patient	Female, 42 years old
Number of Treatments	6 V-ST , 1 months post V-ST one lips injection



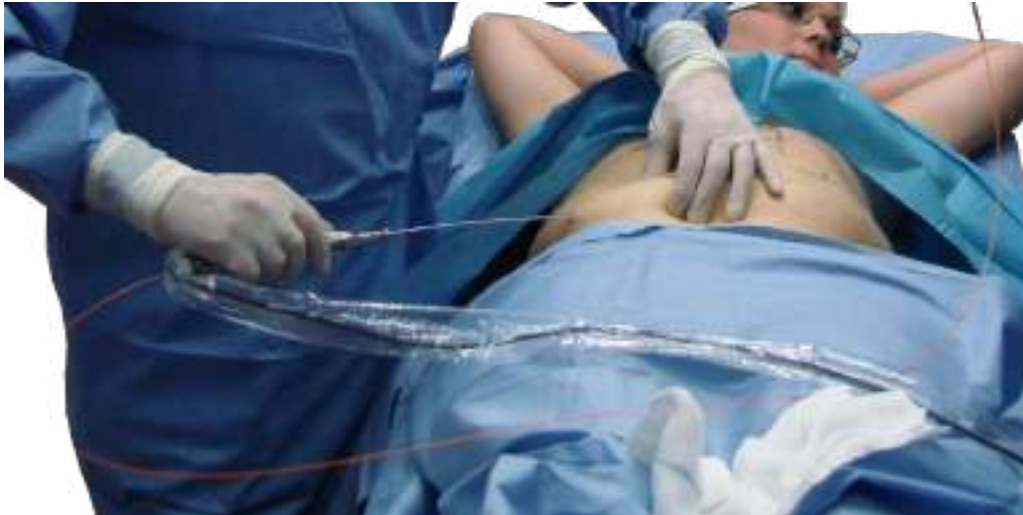Before



2 Months follow-up



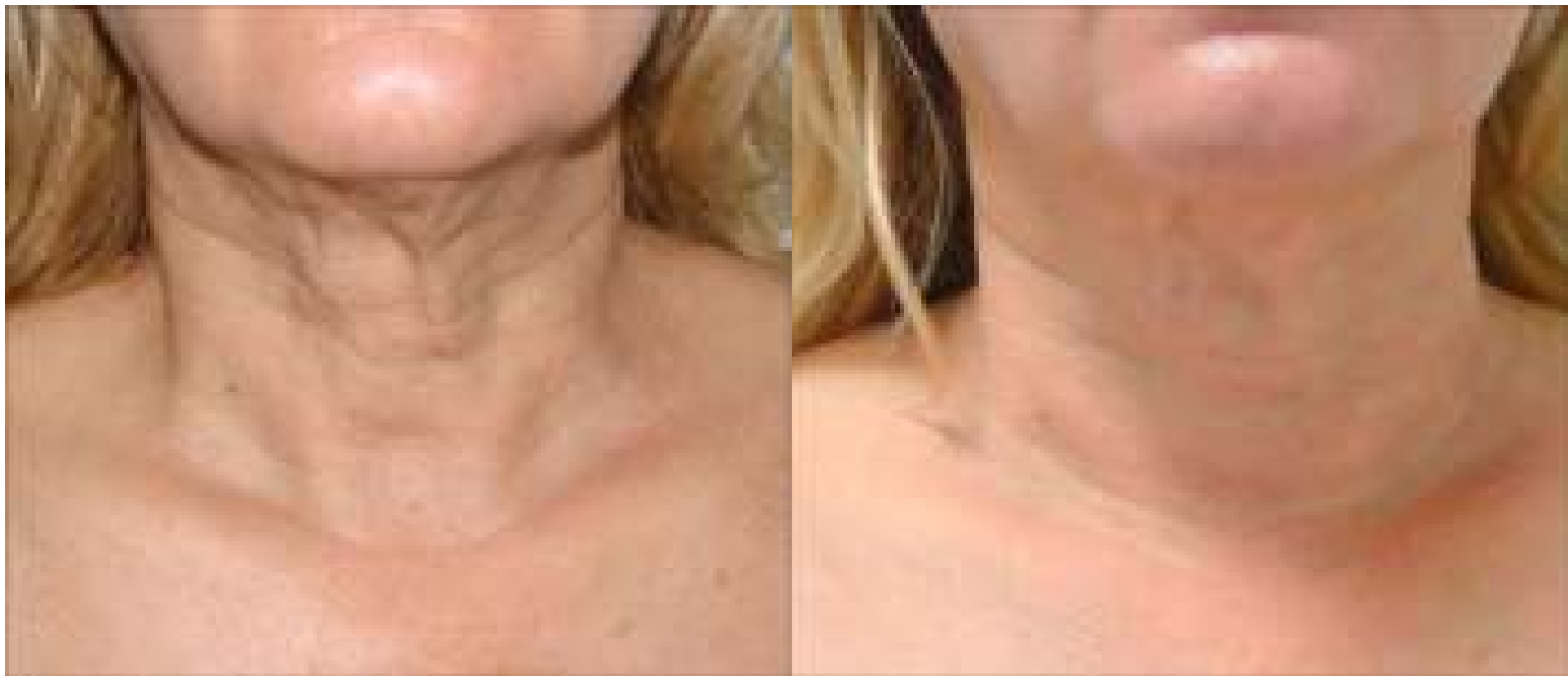V-ST (CORE) & Laser-Lipolysis





Post Laser-Lipolysis

Case Study – REL#101-A	Dr. Eduardo Krulig, Spain
Patient	Female
Process	3 V-ST



Before

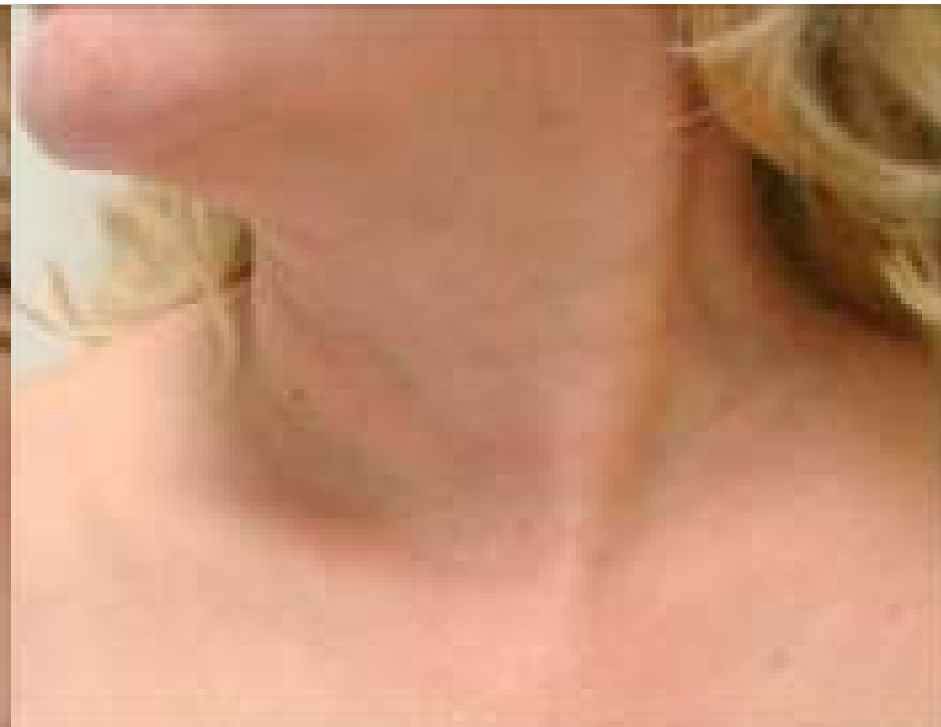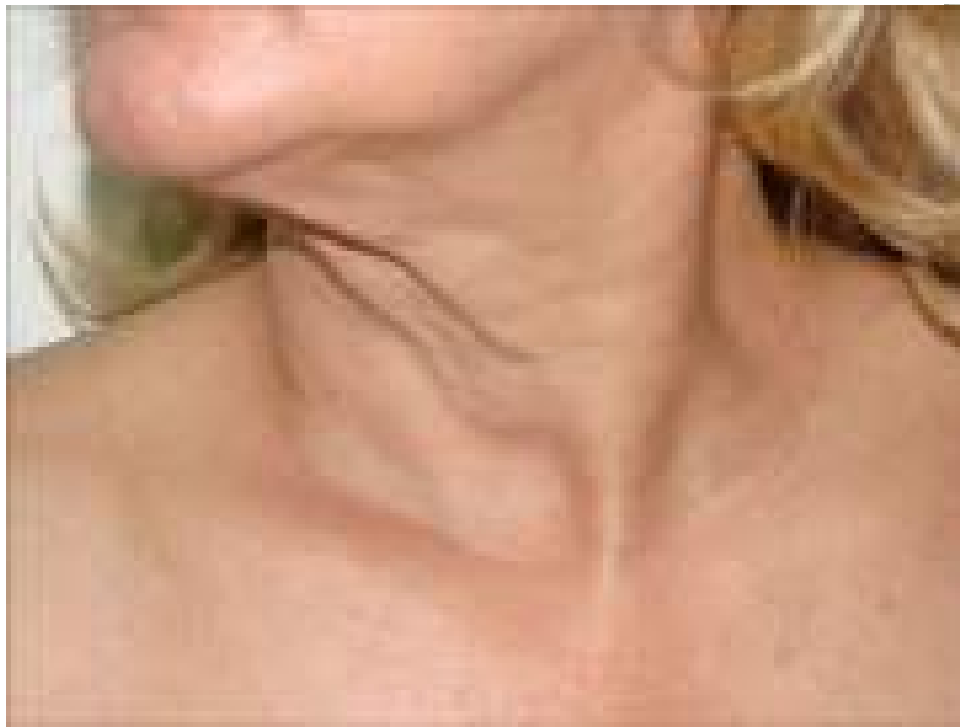After





Post Laser-Lipolysis

Case Study – REL#101-B	Dr. Eduardo Krulig, Spain
Patient	Female
Process	3 V-ST



Before

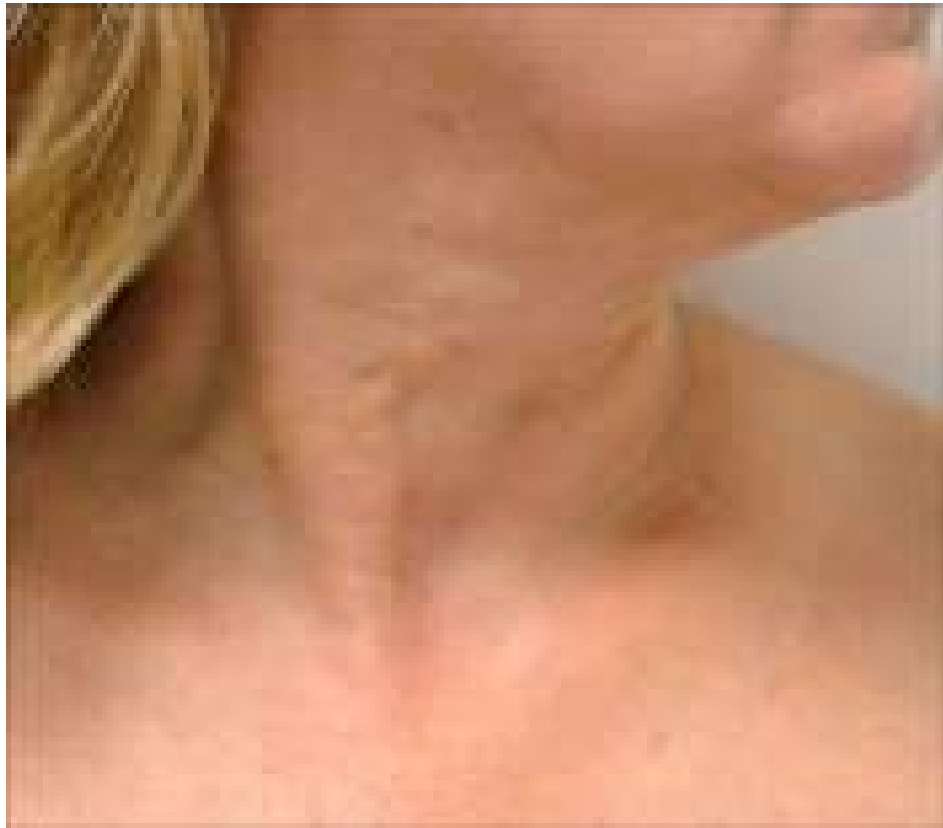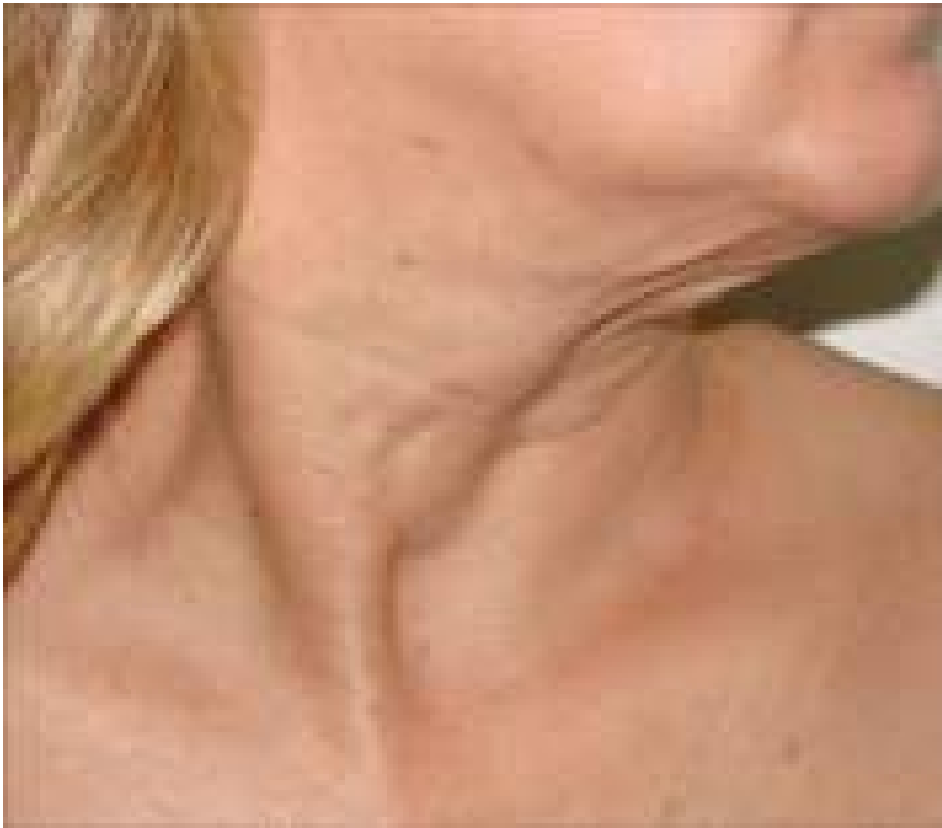After





Post Laser-Lipolysis

Case Study – REL#101-C	Dr. Eduardo Krulig, Spain
Patient	Female
Process	3 V-ST



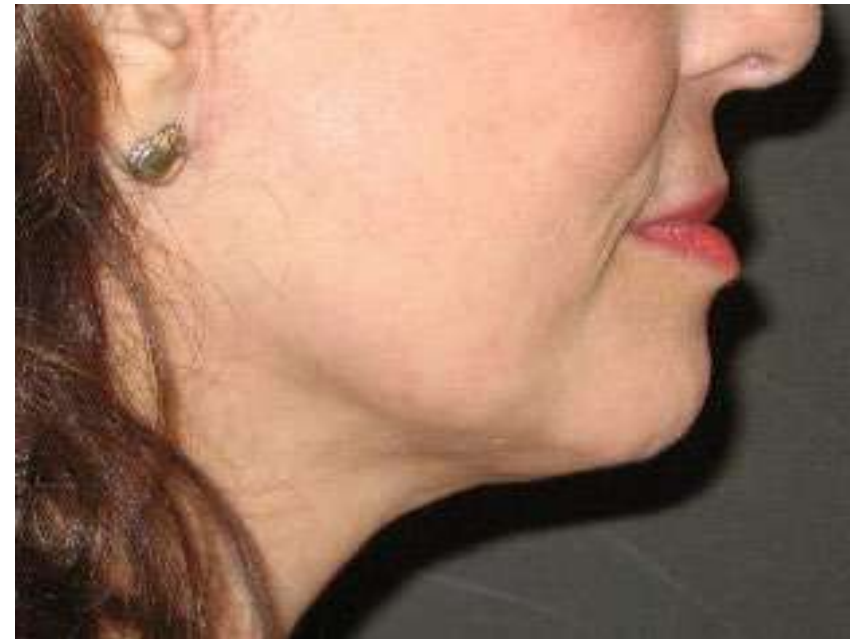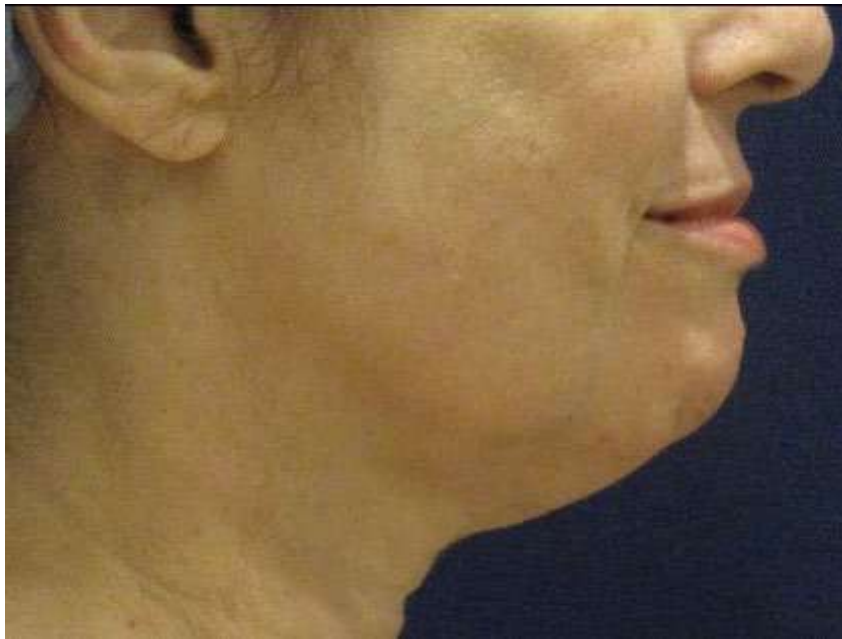Before

After



V-ST post Laser-Lipolysis

Case Study – REL#121	Dr. Matthew Schulman, NY, USA
Patient	Female
Number of Treatments	1 V-ST



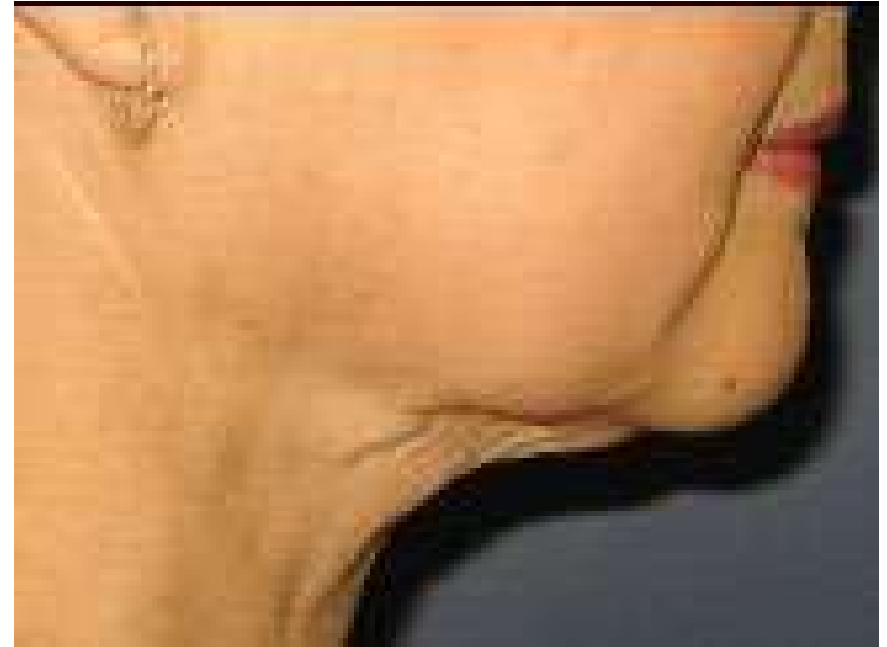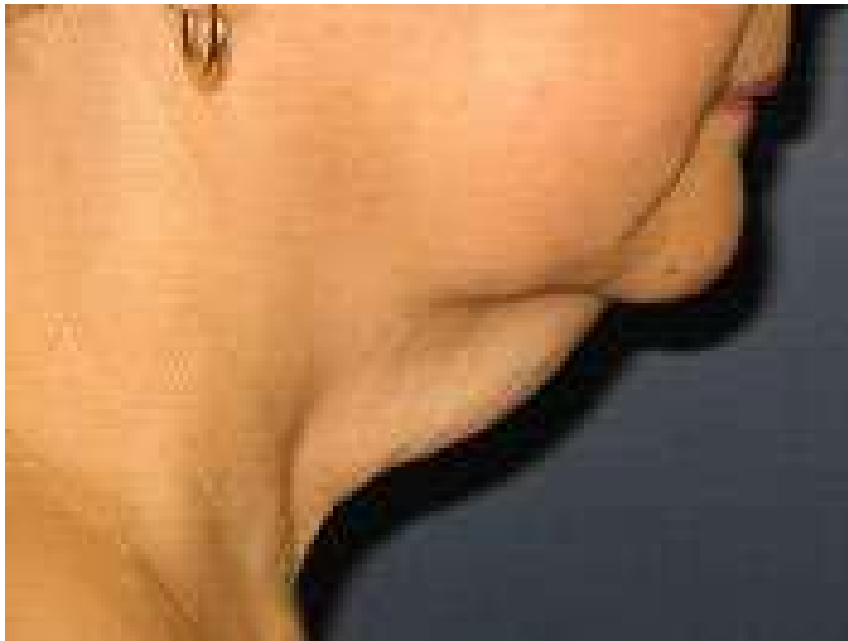Before

After



V-ST post Laser-Lipolysis

Case Study – REL#122	Dr. Matthew Schulman, NY, USA
Patient	Female
Number of Treatments	1 V-ST



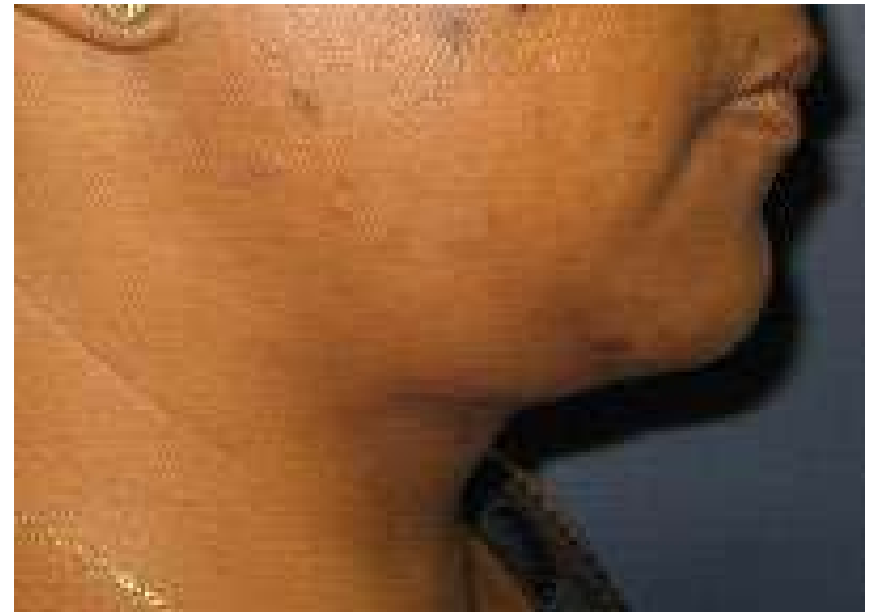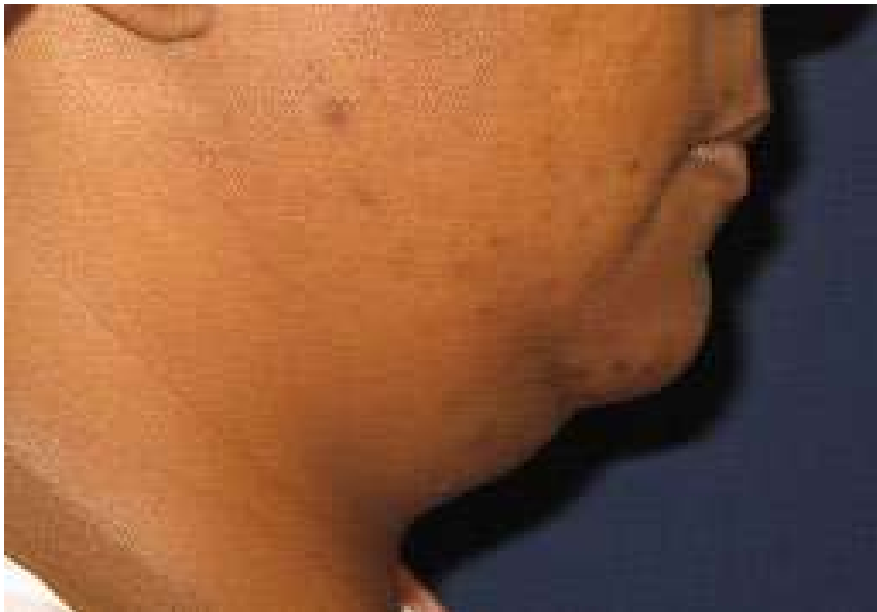Before

After



V-ST post Laser-Lipolysis

Case Study – REL#123	Dr. Matthew Schulman, NY, USA
Patient	Male
Number of Treatments	1 V-ST



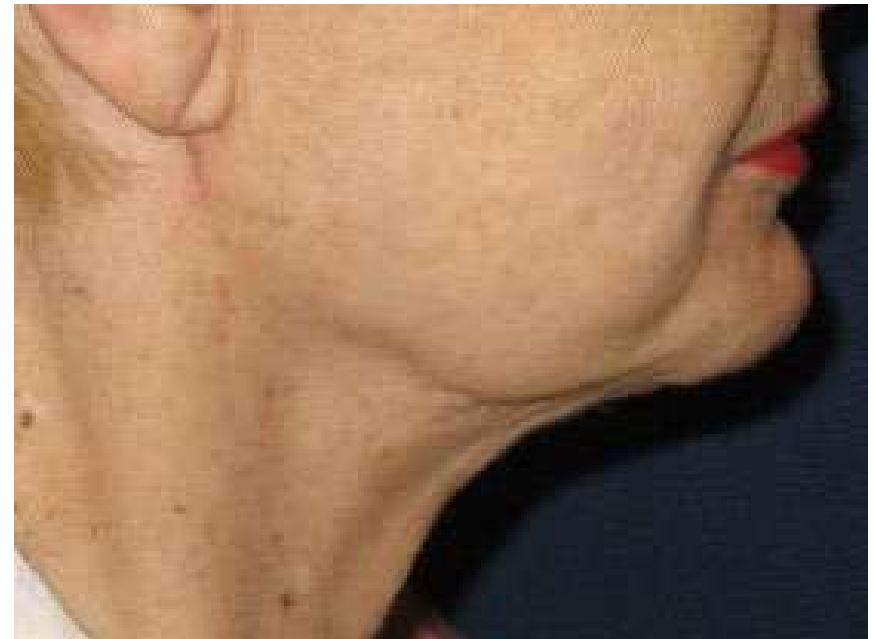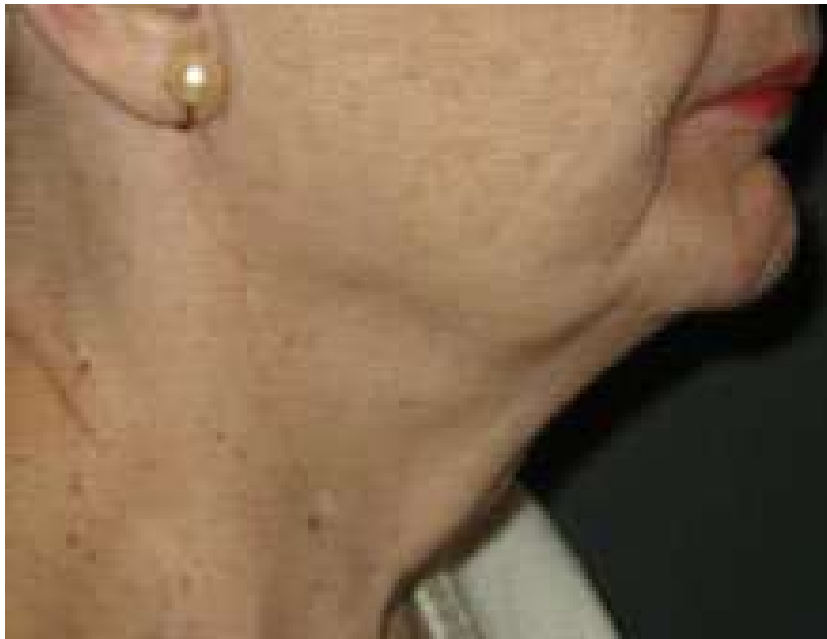Before

After



V-ST post Laser-Lipolysis

Case Study – REL#124	Dr. Matthew Schulman, NY, USA
Patient	Female
Number of Treatments	1 V-ST



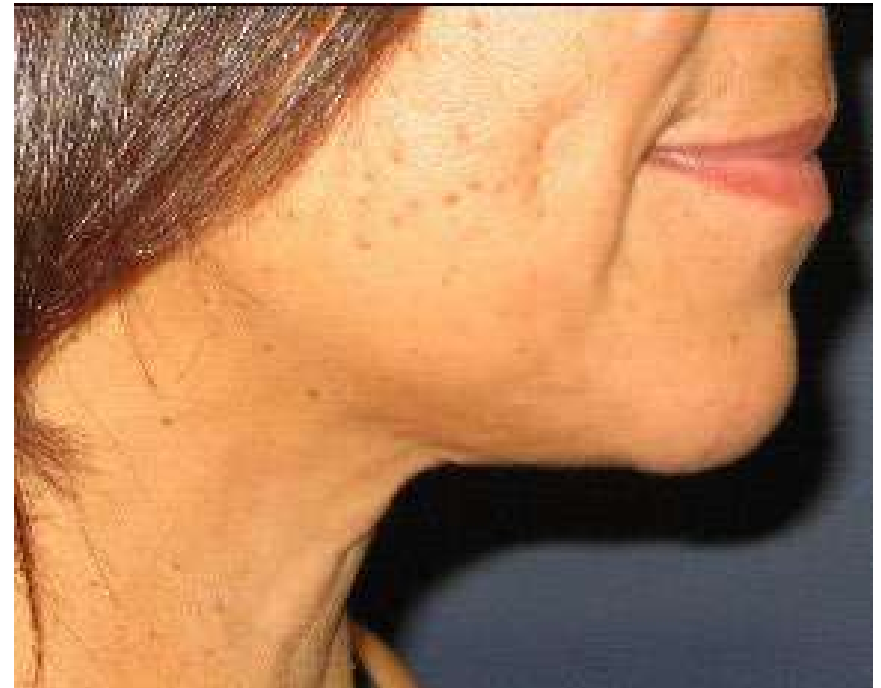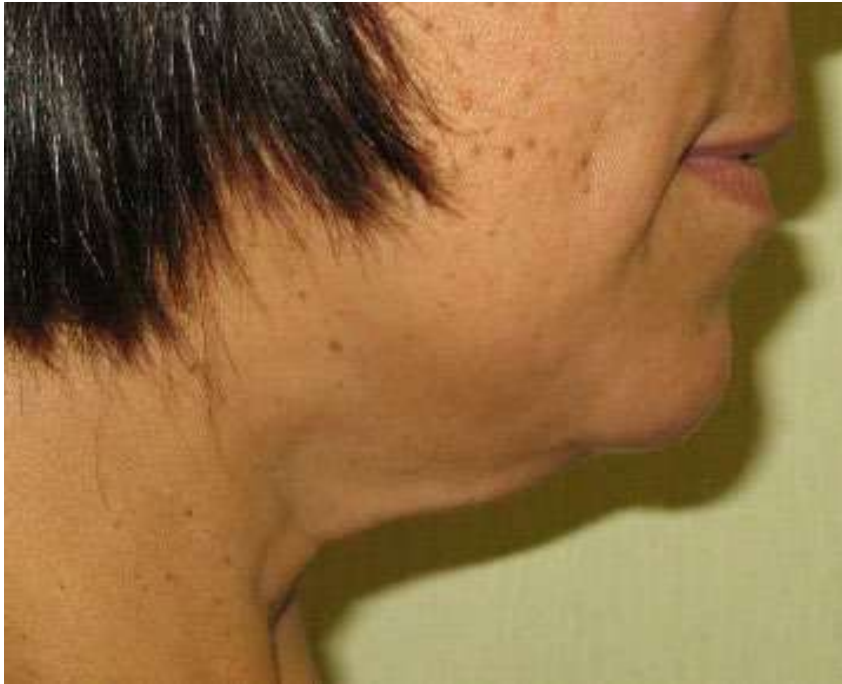Before

After



V-ST post Laser-Lipolysis

Case Study – REL#125	Dr. Matthew Schulman, NY, USA
Patient	Female
Number of Treatments	1 V-ST



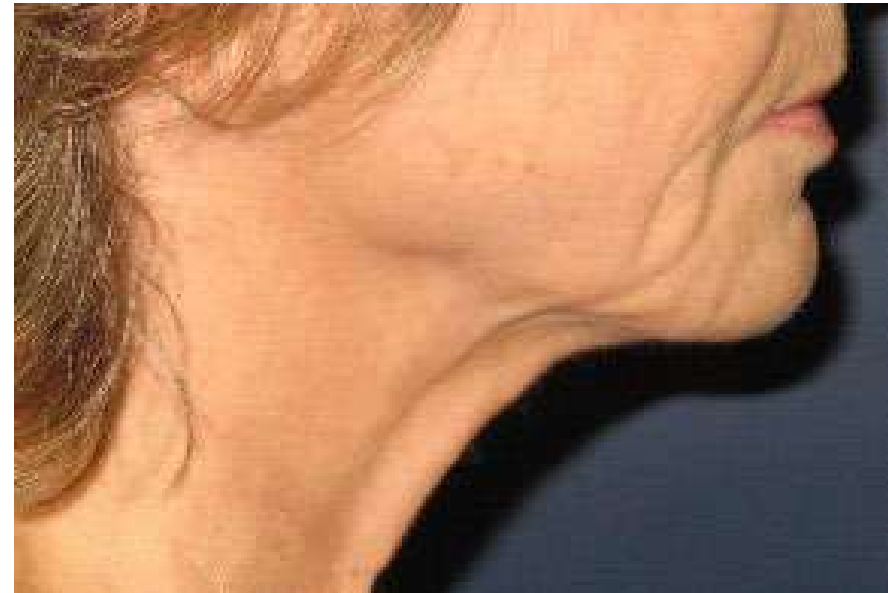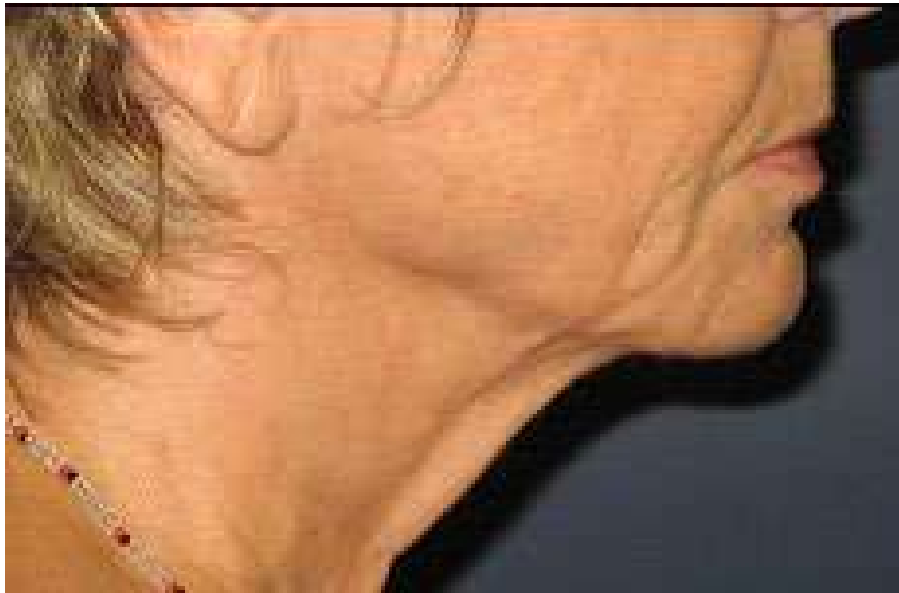Before

After



V-ST post Laser-Lipolysis

Case Study – REL#126	Dr. Matthew Schulman, NY, USA
Patient	Female
Number of Treatments	1 V-ST

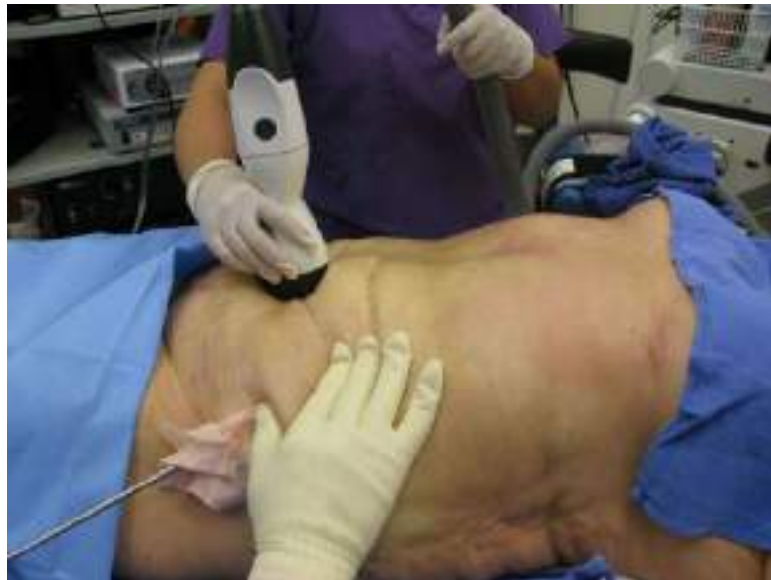

Before

After

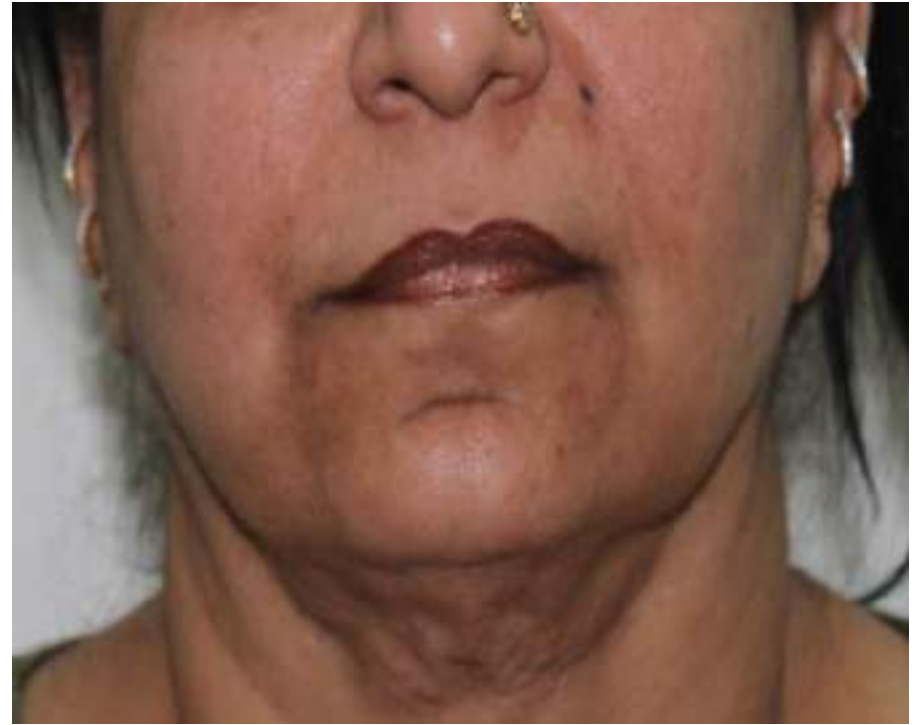
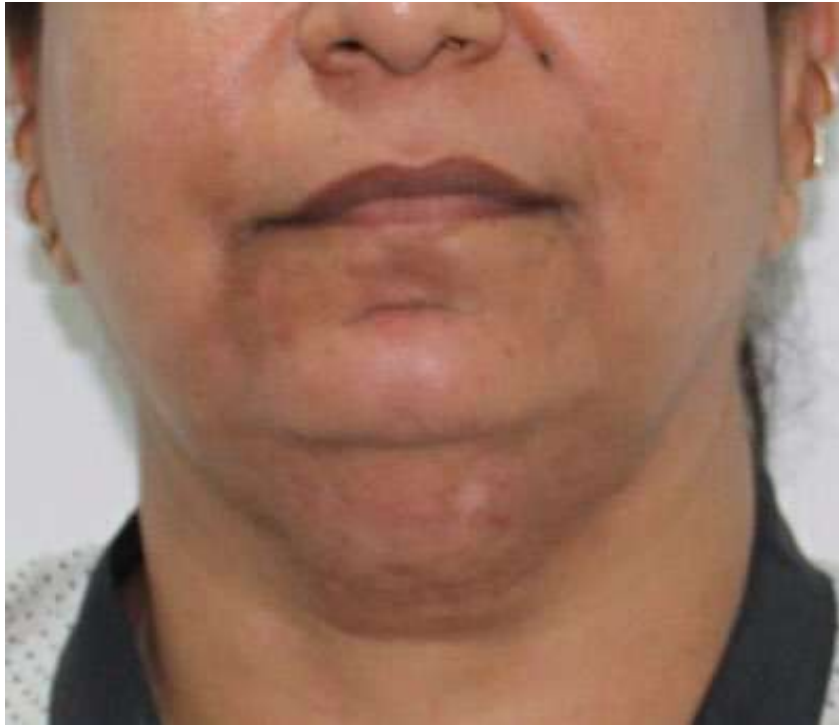
V-ST (CORE) & Liposuction



V-ST post Chin Liposuction

Case Study – RES#117-A	Dr. Sajal Halder, New-Delhi, India
Patient	Female, 42 years old
Number of Treatments	3 V-ST



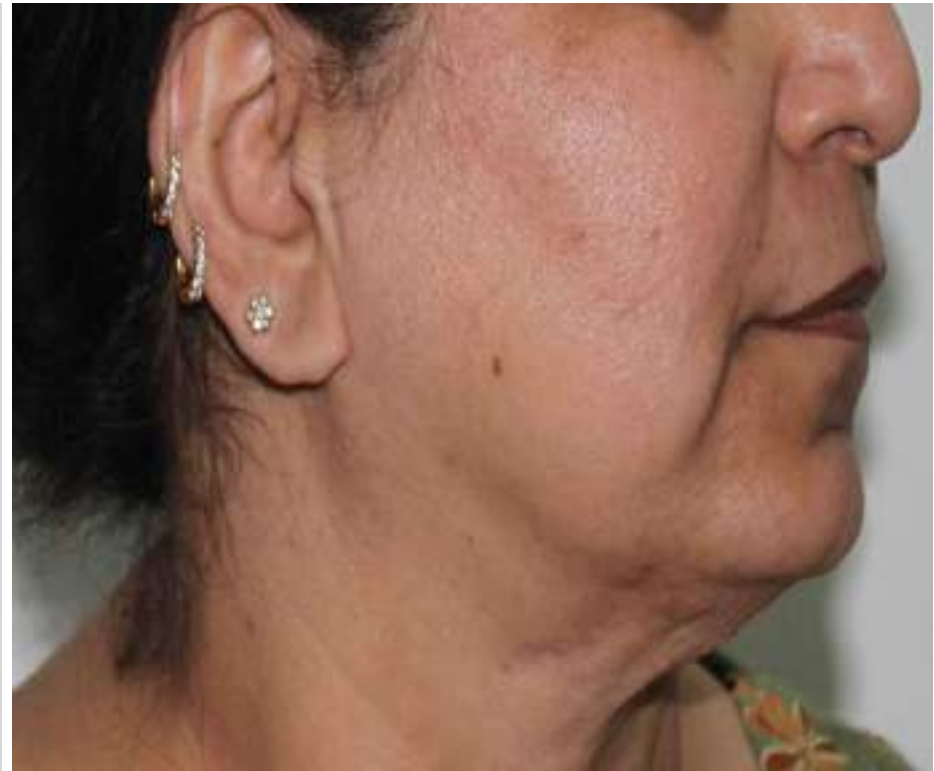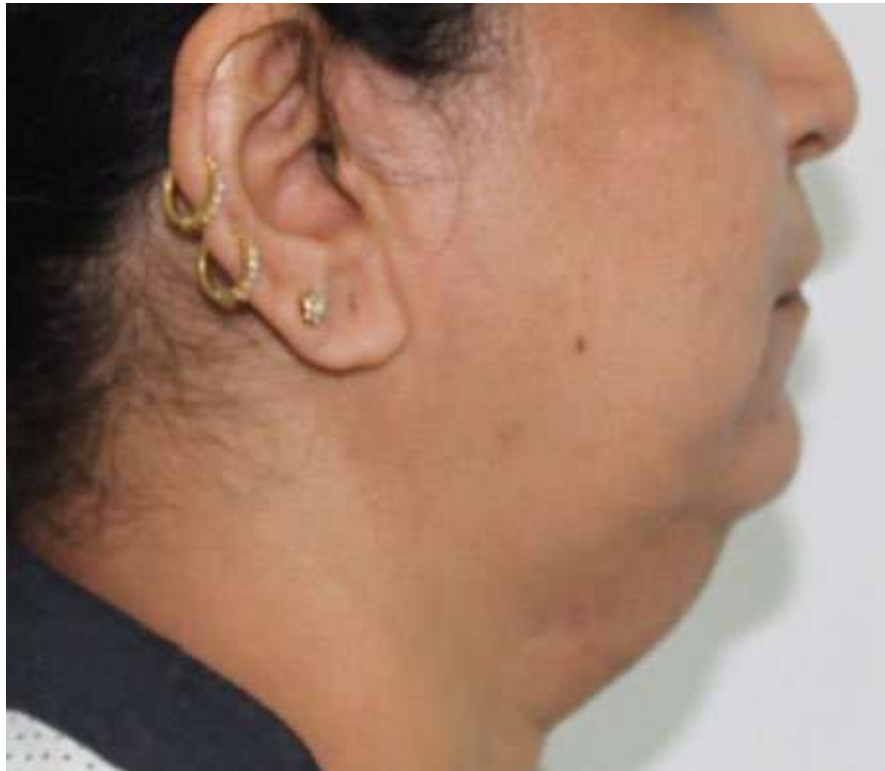Before

After



V-ST post Chin Liposuction

Case Study – RES#117-B	Dr. Sajal Halder, New-Delhi, India
Patient	Female, 42 years old
Number of Treatments	3 V-ST

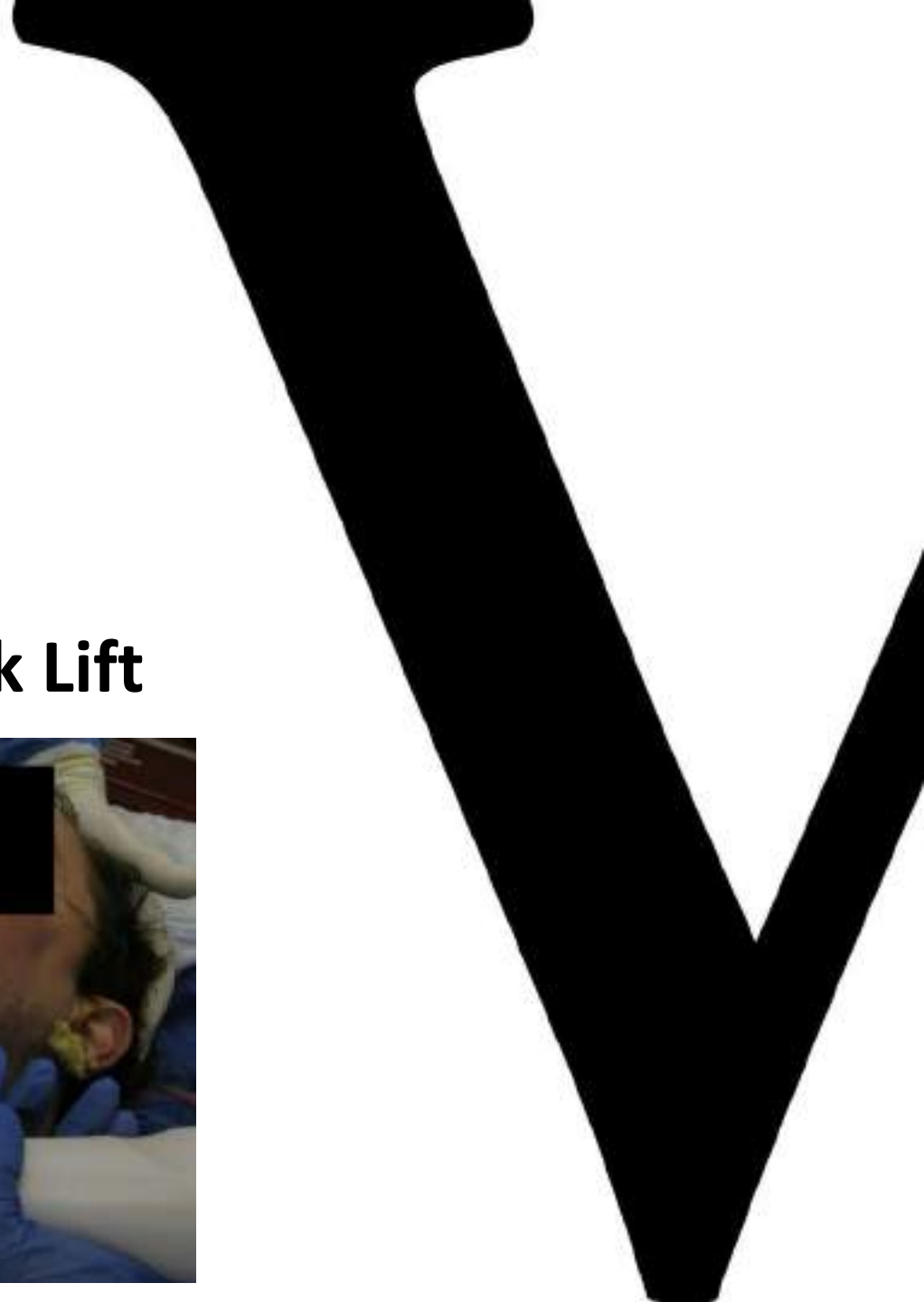
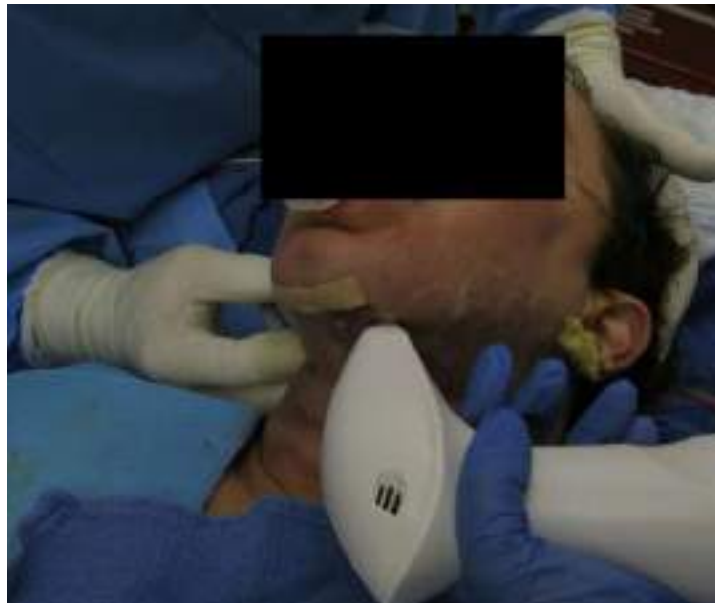
Before

After



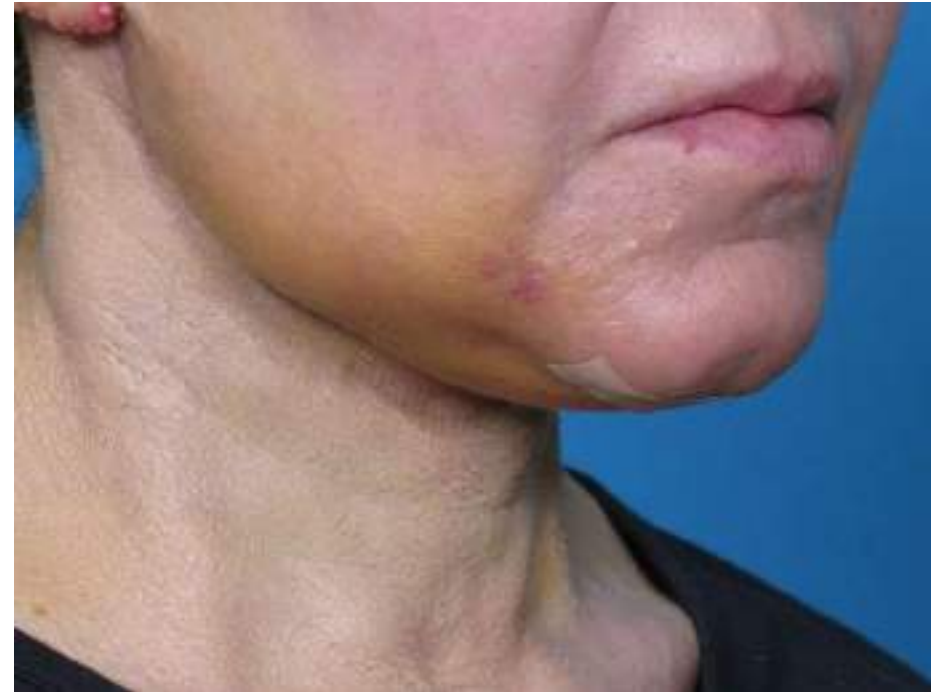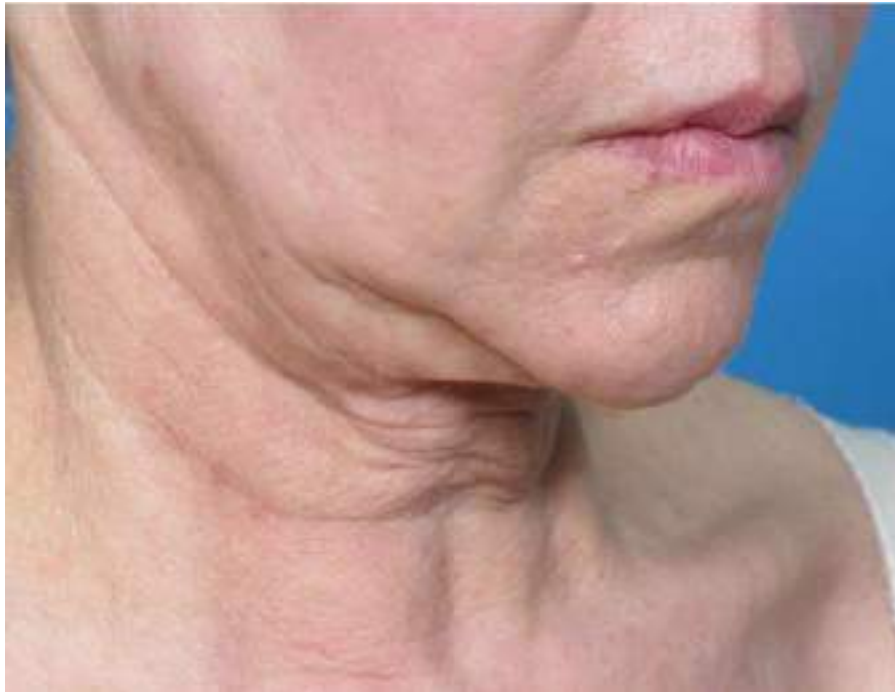V-ST (CORE) & Neck Lift





V-ST during Neck Lift

Case Study – RES#107A	Dr. Daniel Man, Boca Raton, Florida, USA
Patient	Female
Number of Treatments	2 V-ST



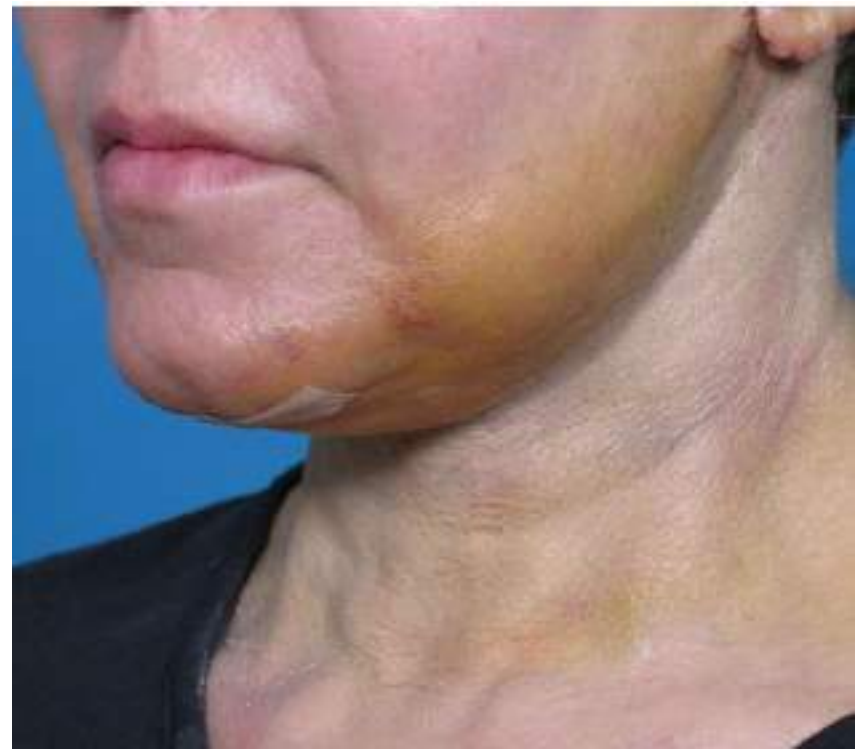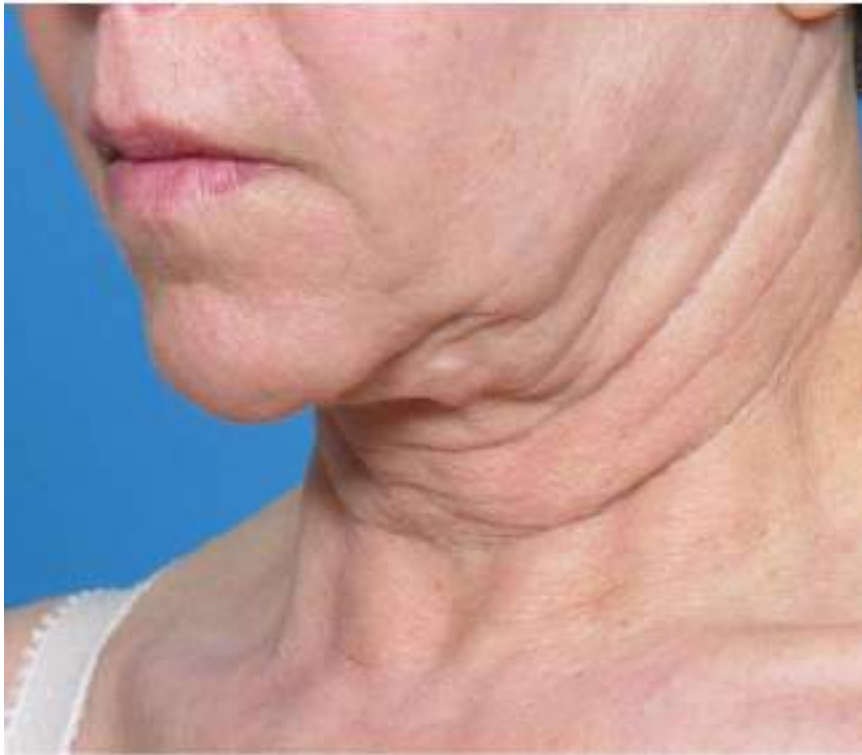Before

After



V-ST during and post Neck Lift

Case Study – RES#107-B	Dr. Daniel Man, Boca Raton, Florida, USA
Patient	Female
Number of Treatments	2 V-ST



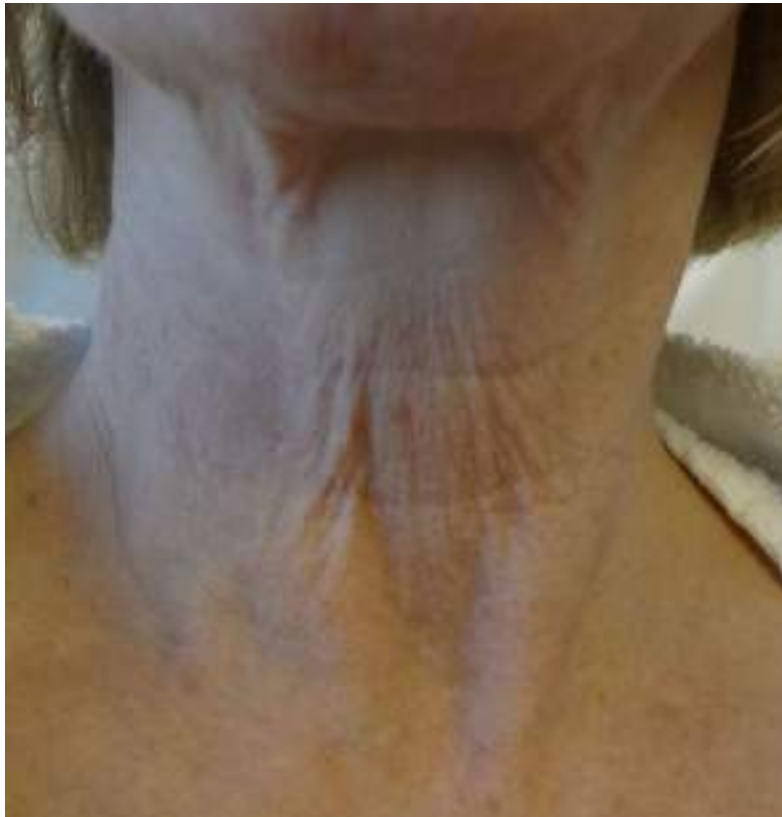Before

After

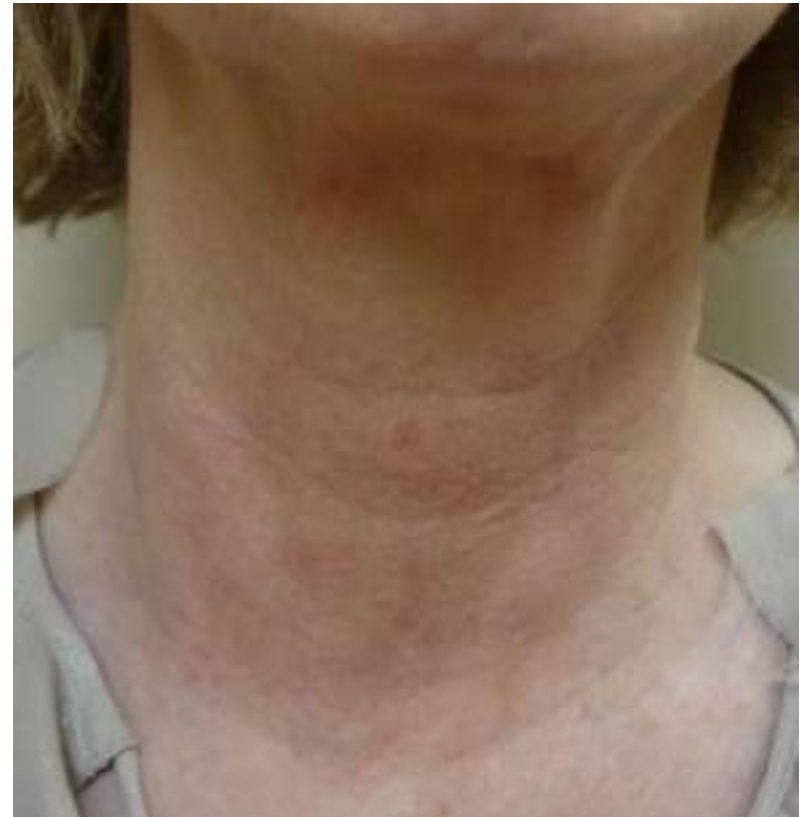

V-ST post Neck Lift

Case Study – RES#108-A	Dr. Hunt Neurohr, Wellskin Med Spa, Dallas, USA
Patient	Female, 64 years old
Number of Treatments	3 V-ST



After Neck Lift

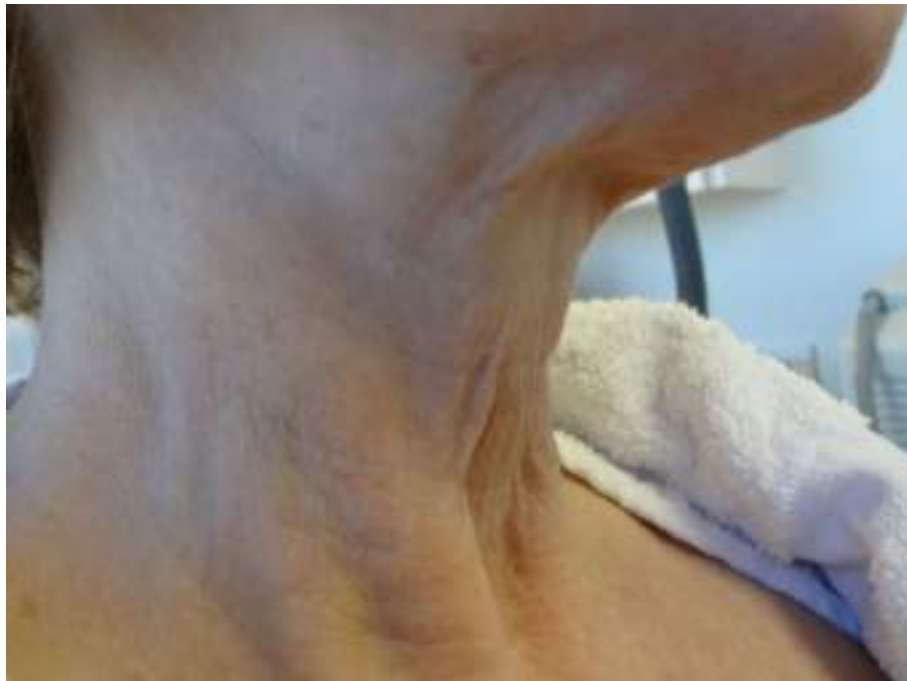

After CORE

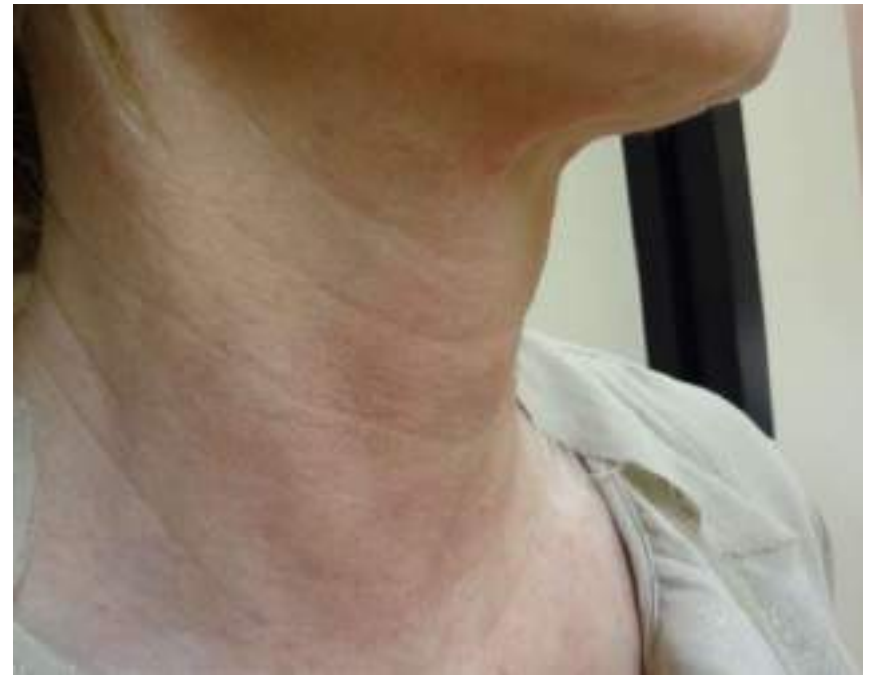

V-ST post Neck Lift

Case Study – RES#108-B	Dr. Hunt Neurohr, Wellskin Med Spa, Dallas, USA
Patient	Female, 64 years old
Number of Treatments	3 V-ST



After Neck Lift



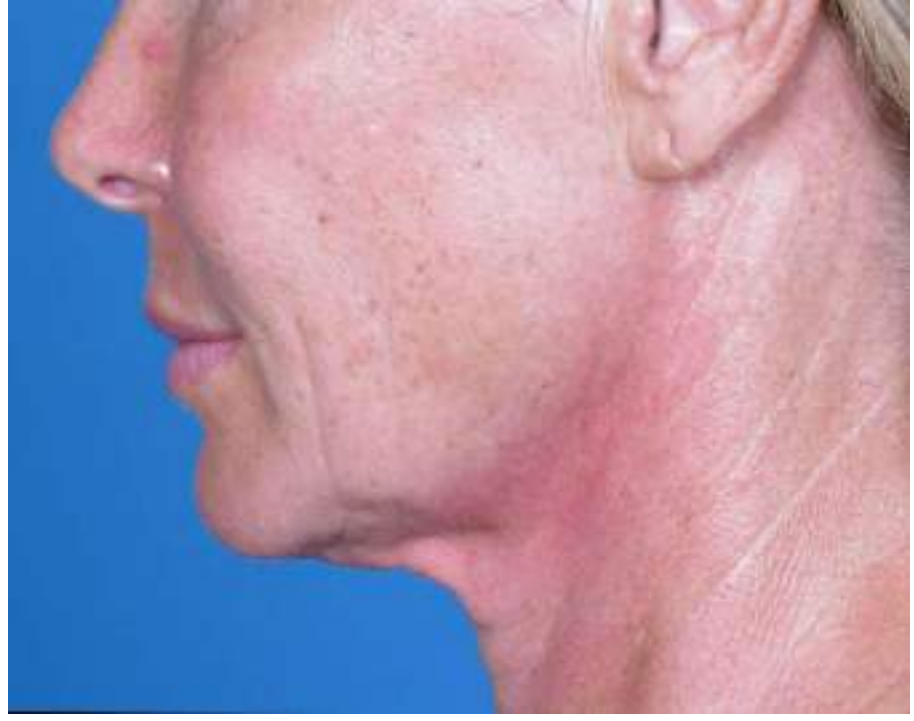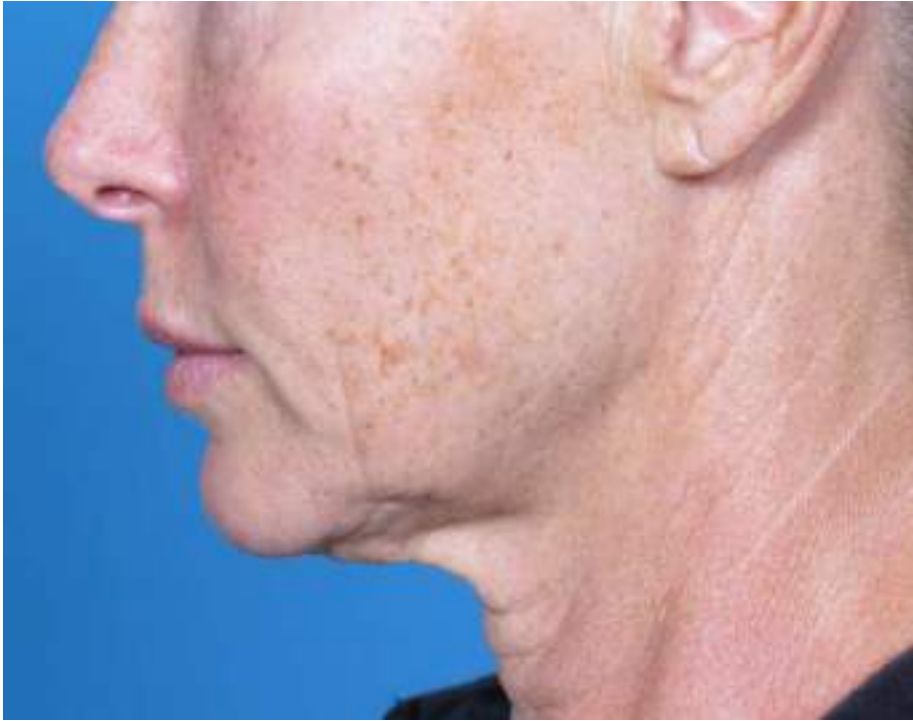After Reaction





V-ST post Neck Lift

Case Study – RES#114-A	Dr. Daniel Man, Boca Raton, Florida, USA
Patient	Female, 65 years old
Number of Treatments	6 V-ST



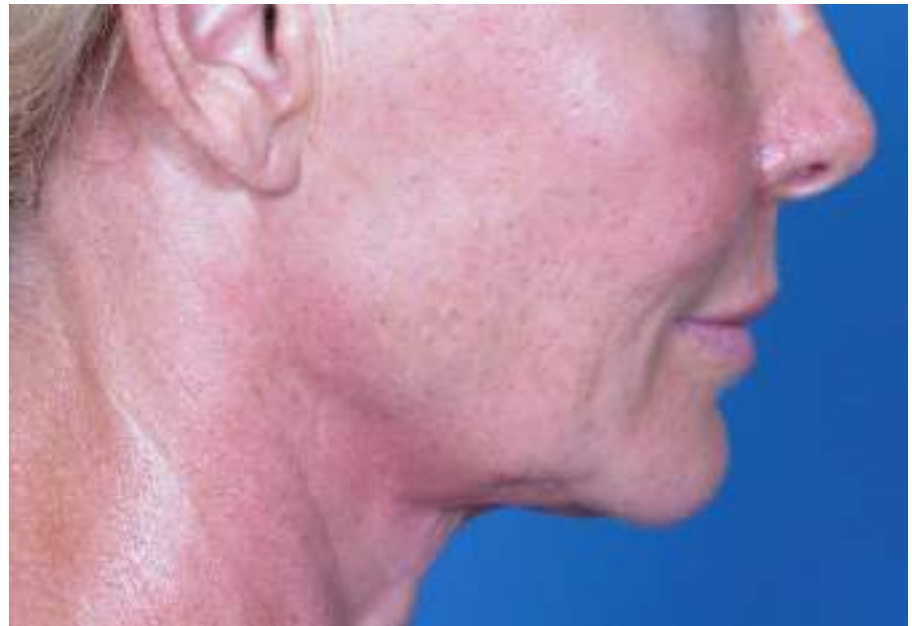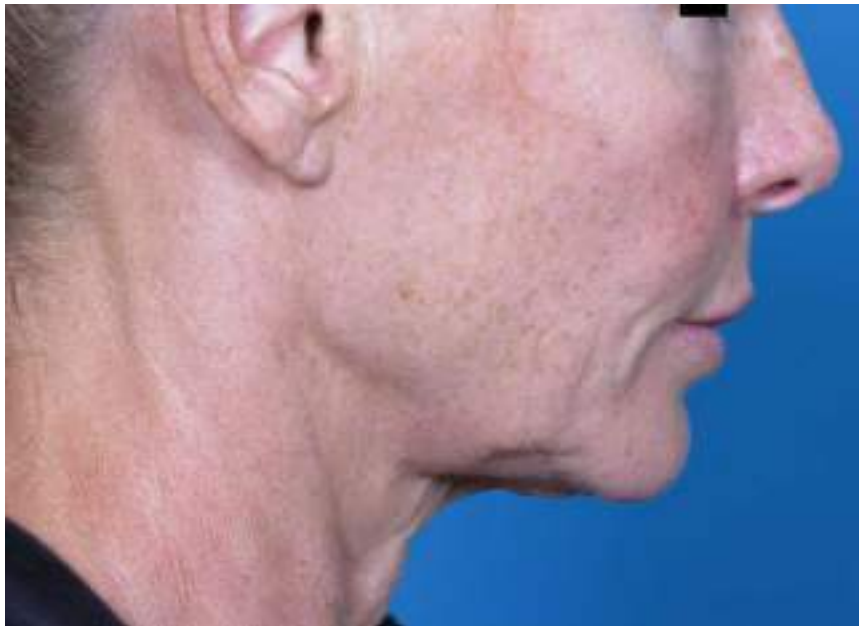Before

After



V-ST post Neck Lift

Case Study – RES#114-B	Dr. Daniel Man, Boca Raton, Florida, USA
Patient	Female, 65 years old
Number of Treatments	6 V-ST



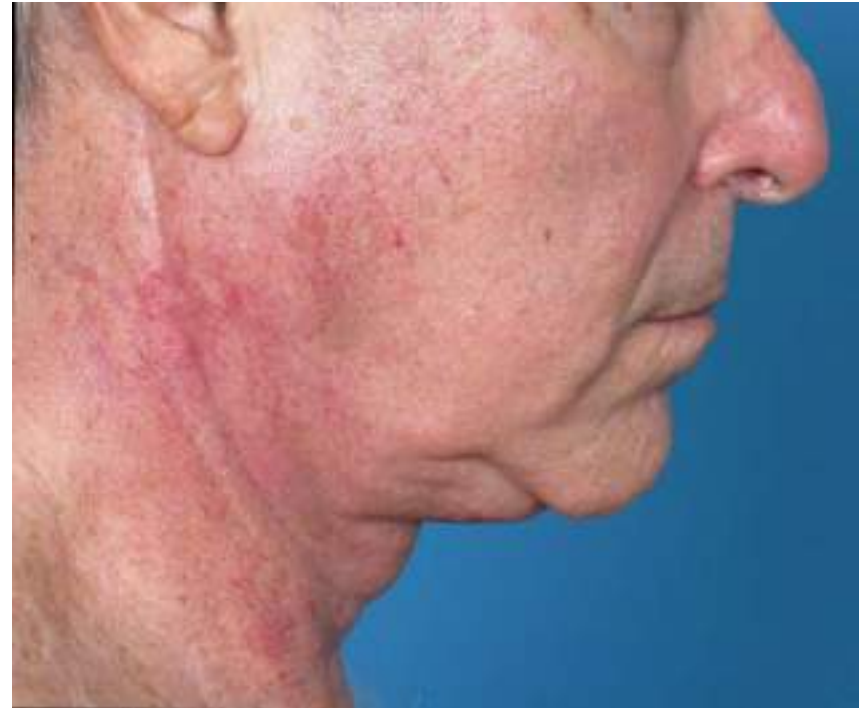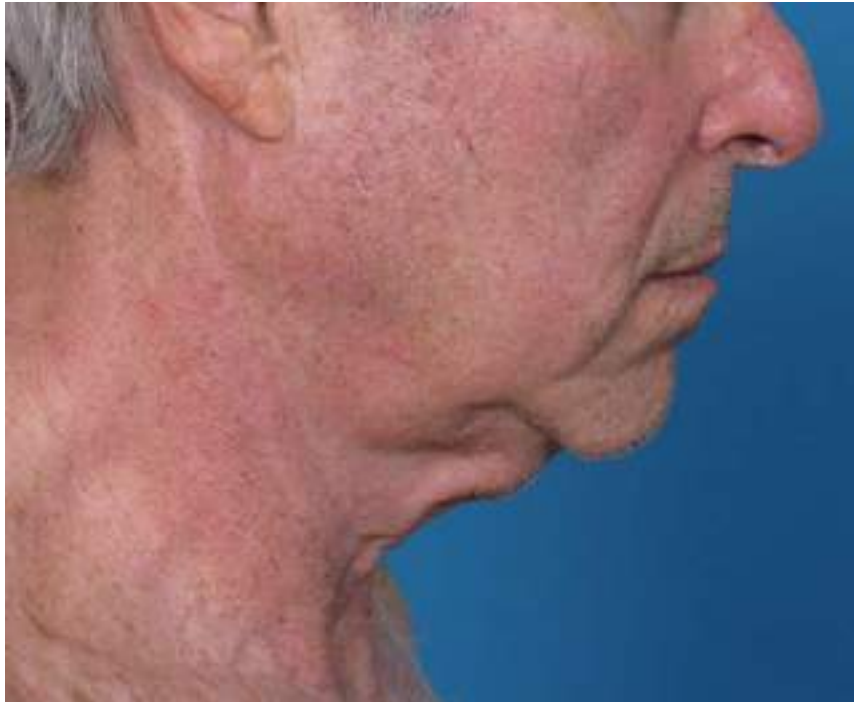Before

After



V-ST post Neck Lift

Case Study – RES#115	Dr. Daniel Man, Boca Raton, Florida, USA
Patient	Male, 72 years old
Number of Treatments	6 V-ST



Before

After

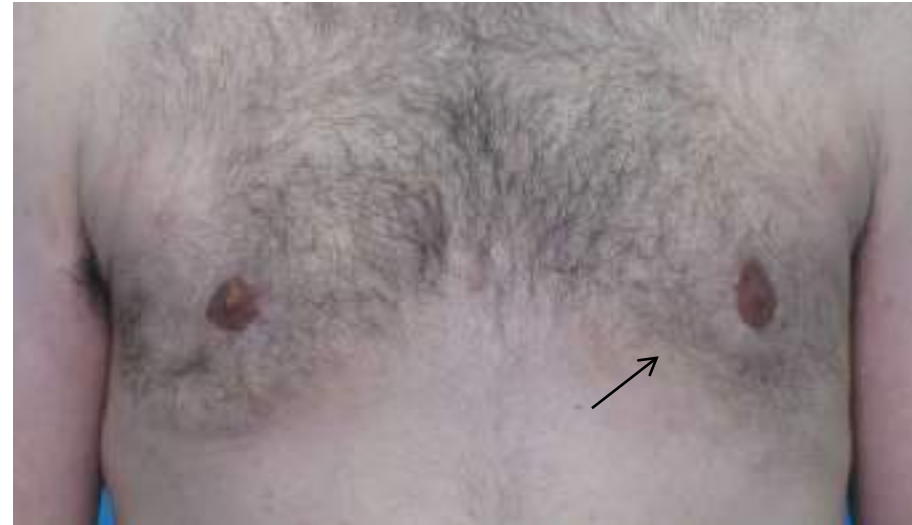
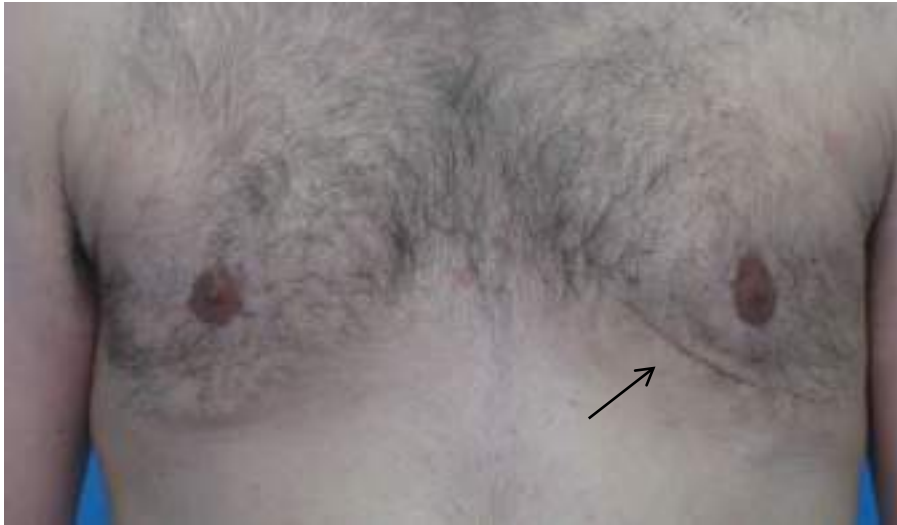
Surgical Procedures



RF after Gynecomastia

Case Study – RES#109	Dr. Daniel Man, Boca Raton, Florida, USA
Patient	Male
Number of Treatments	4 V-ST



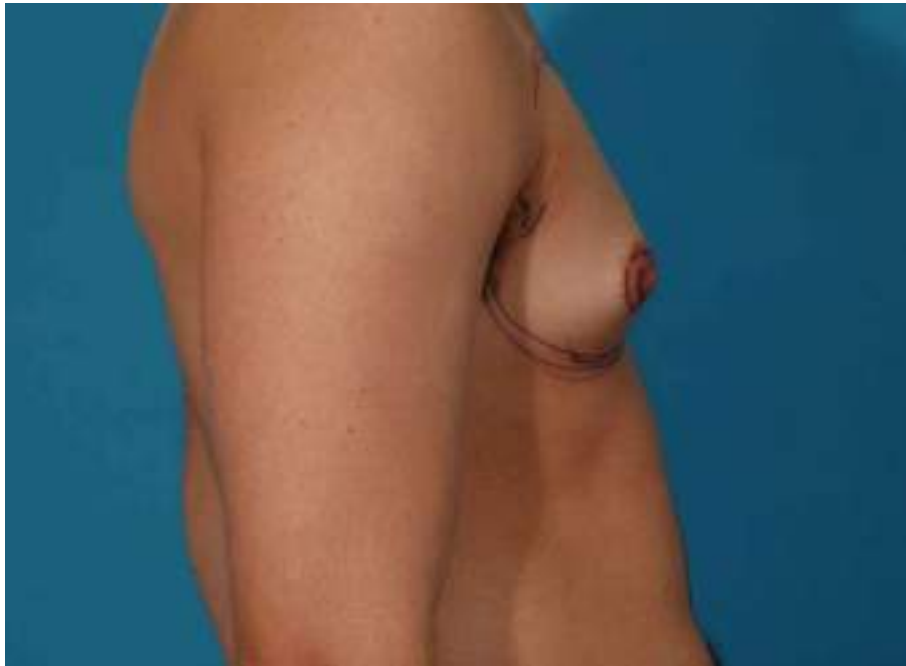Before

After

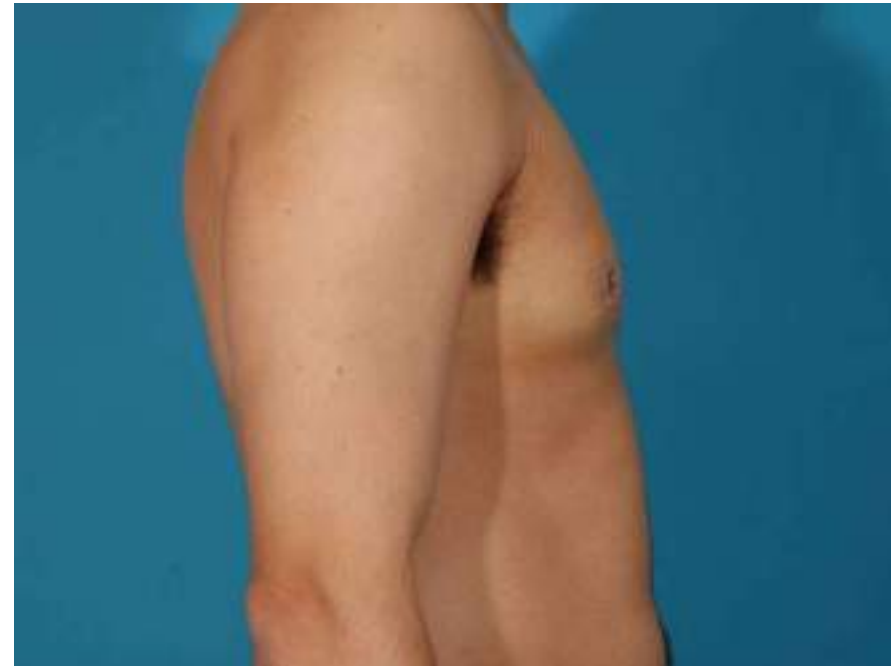

V-ST post Laser assisted liposuction for Gynecomastia

Case Study – RES#110	Dr. Daniel Man, Boca Raton, Florida, USA
Patient	Male
Number of Treatments	2 V-ST



Before

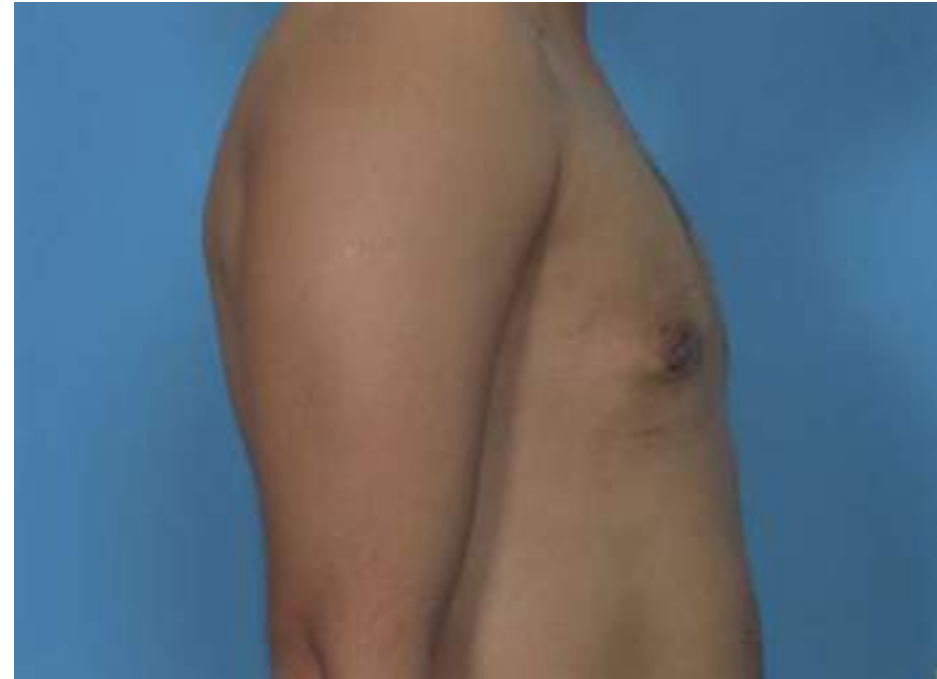
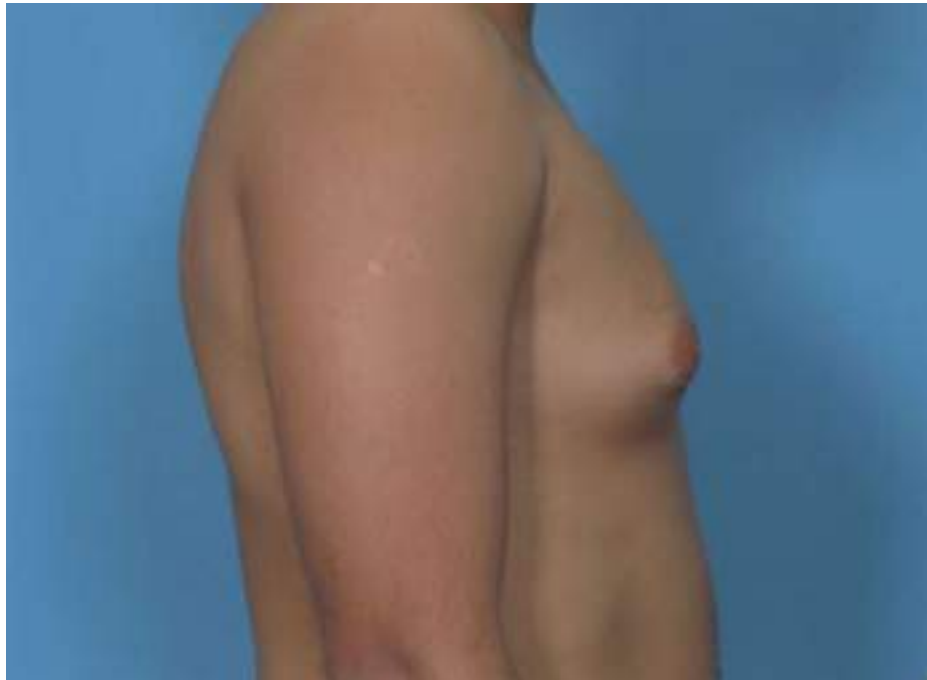

After



V-ST post Laser assisted liposuction for Gynecomastia

Case Study – RES#111	Dr. Daniel Man, Boca Raton, Florida, USA
Patient	Male
Number of Treatments	2 V-ST



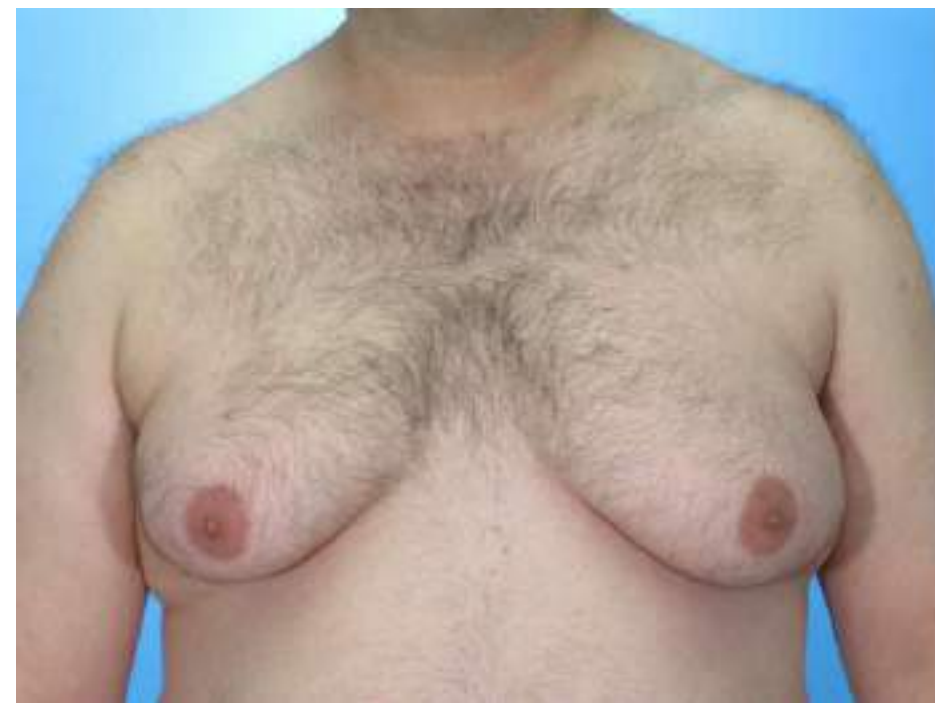Before

After

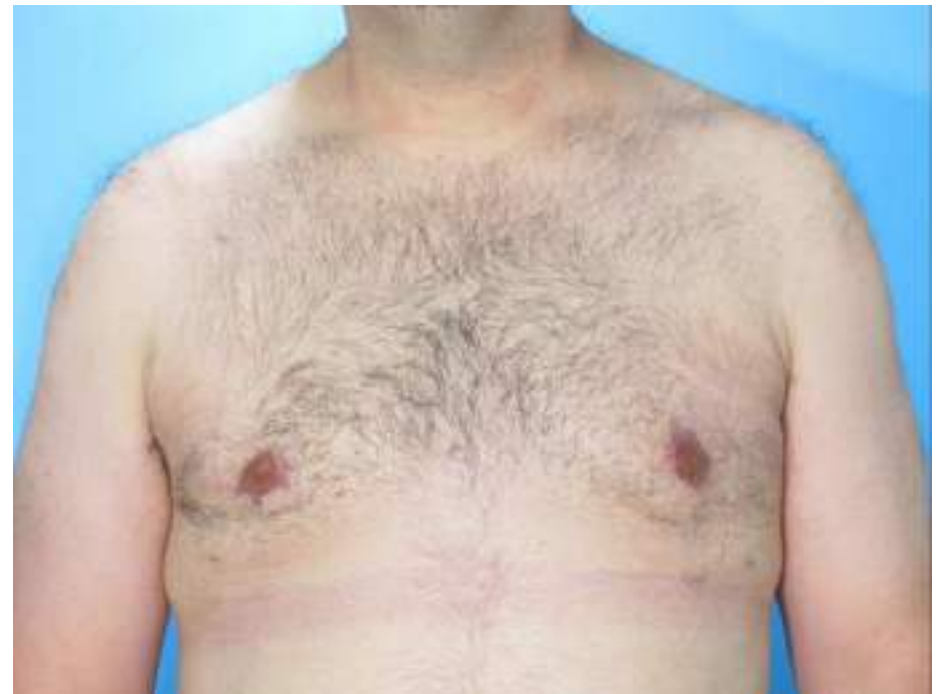

V-ST post Laser assisted liposuction for Gynecomastia

Case Study – RES#112	Dr. Daniel Man, Boca Raton, Florida, USA
Patient	Male
Number of Treatments	3 V-ST



Before

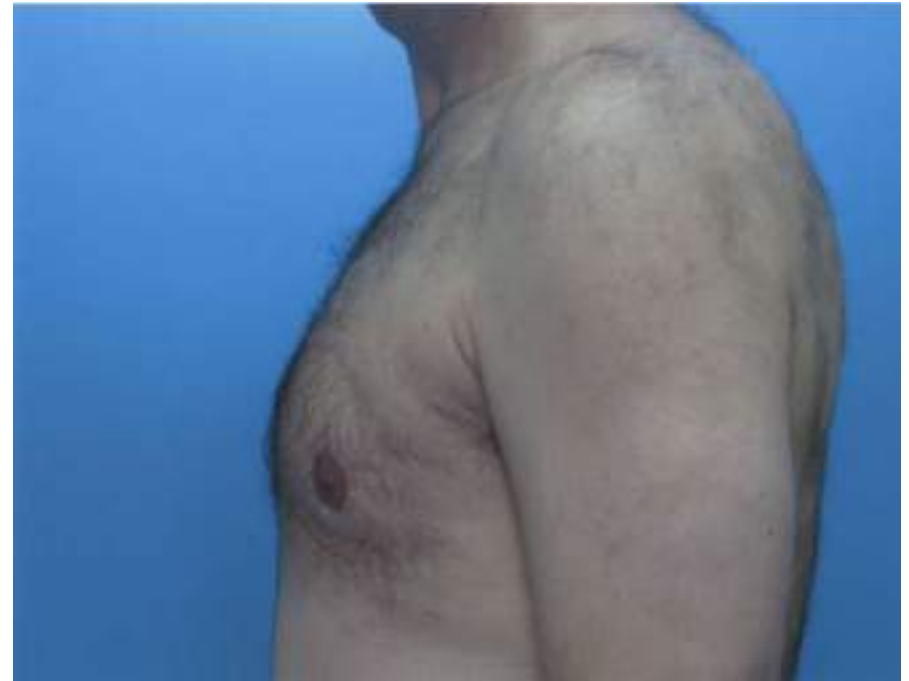
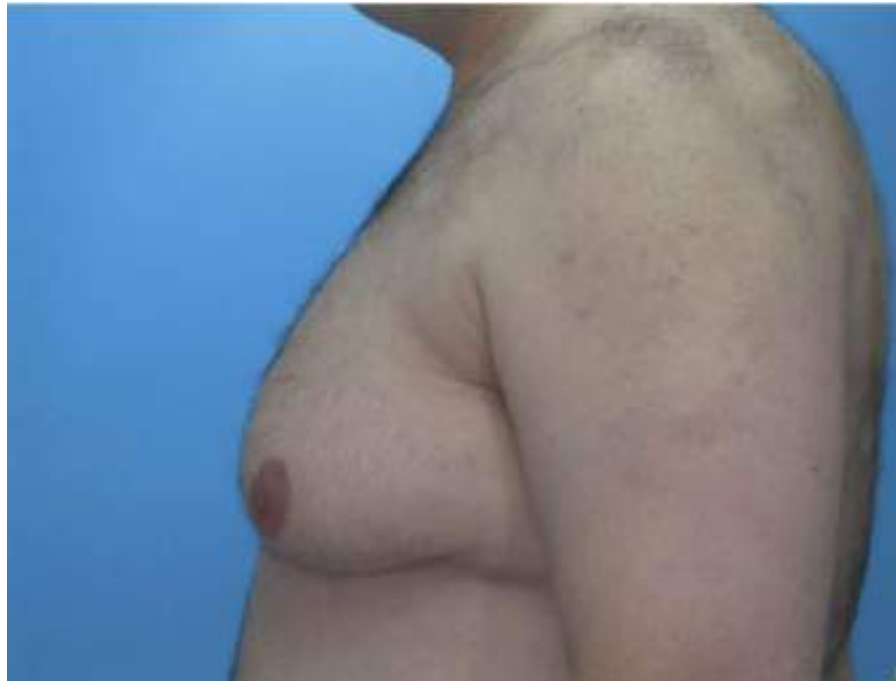
After



V-ST post Laser assisted liposuction for Gynecomastia

Case Study – RES#113	Dr. Daniel Man, Boca Raton, Florida, USA
Patient	Male
Number of Treatments	3 V-ST



Before

After





Thank You!

Questions? Comments?



VIORA