

# V·FORM

## Case Studies



# 6 cm Circumferential Reduction

**Case Study – VF#013-A**

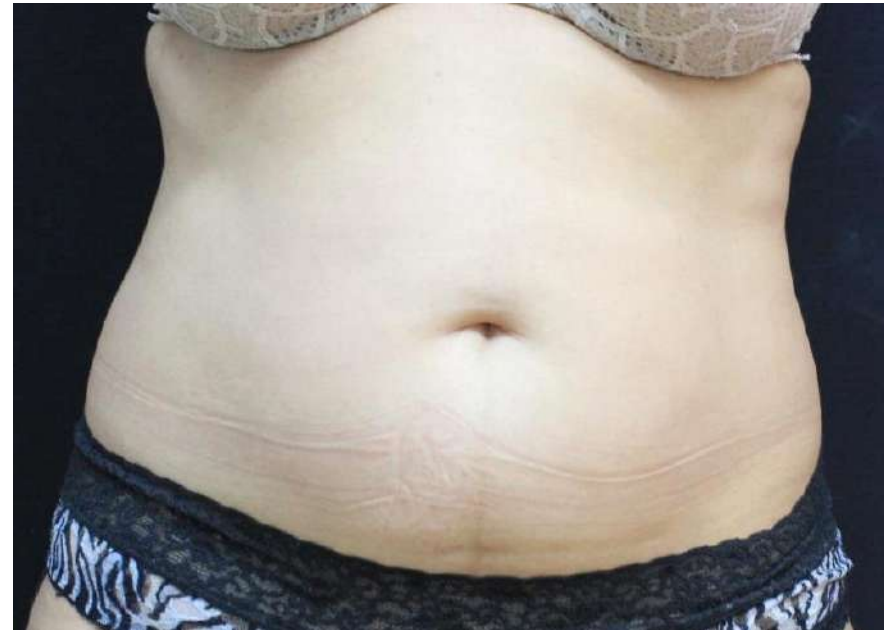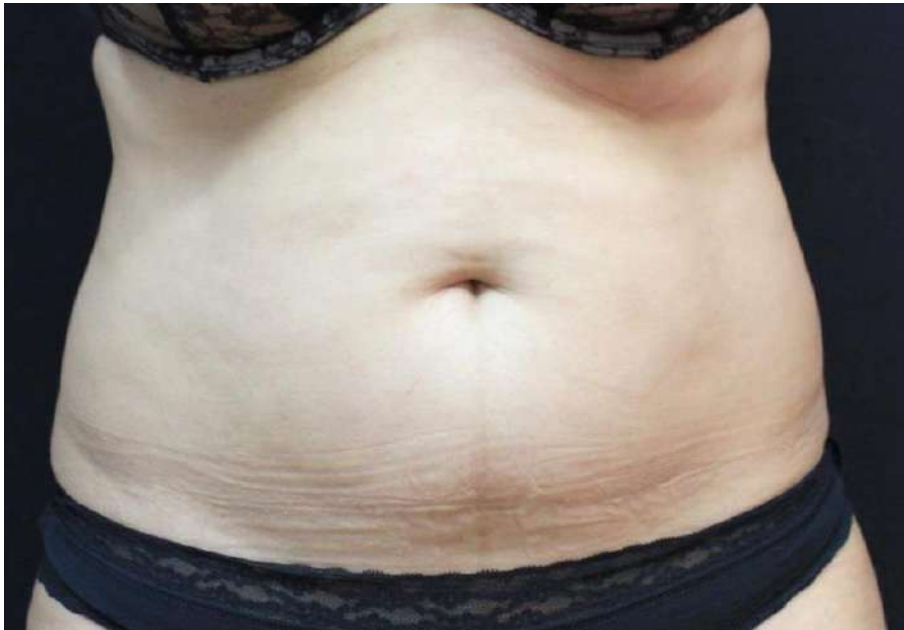**Dr. Cruzy Tagger, Viora Ltd.**

**Patient**

Female, 56 years old (BMI 26)

**Number of Treatments**

**8 V-FORM**



**Before**

**After**



# 6 cm Circumferential Reduction

**Case Study – VF#013-B**

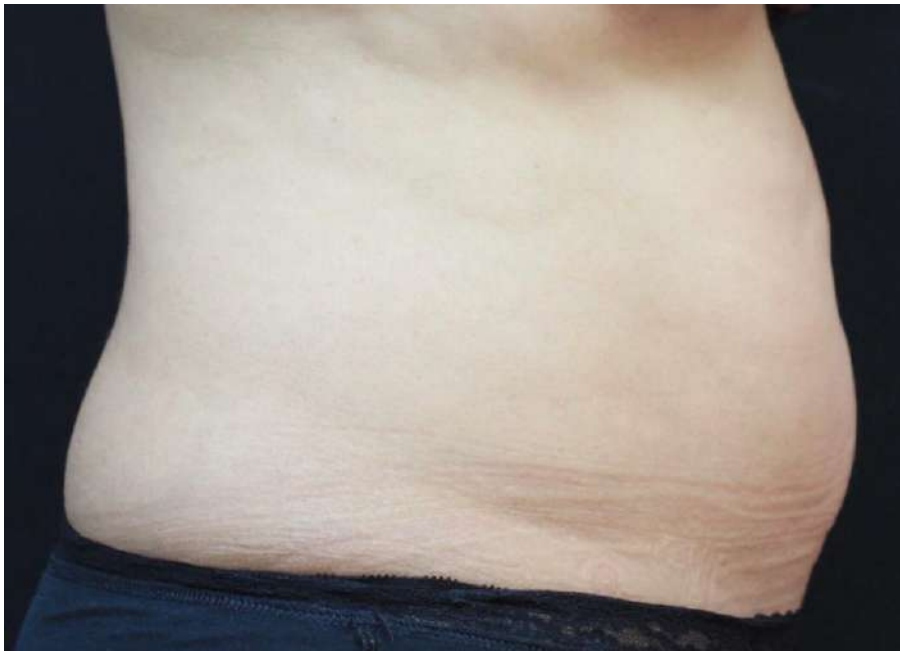**Dr. Cruzy Tagger, Viora Ltd.**

**Patient**

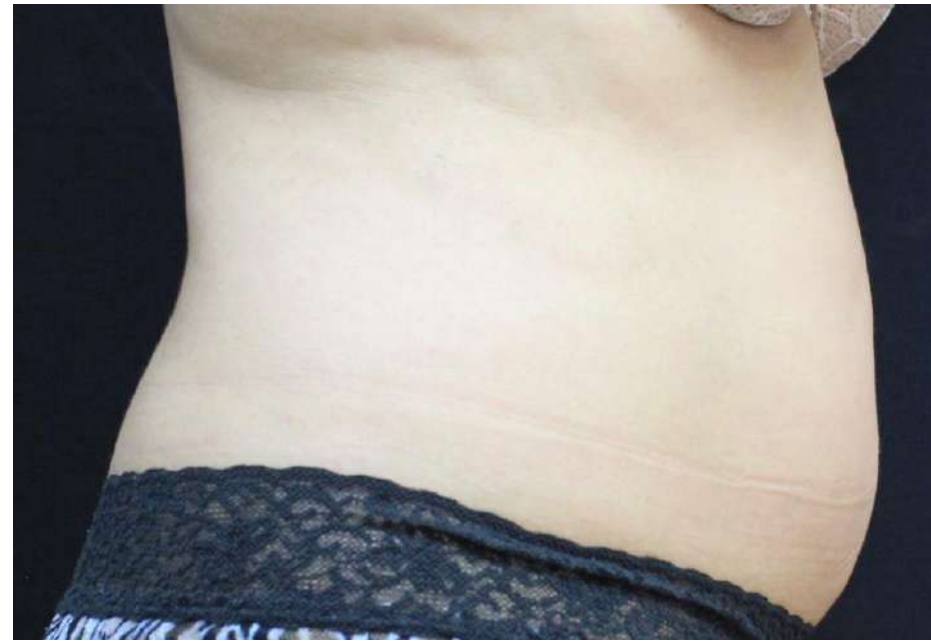Female, 56 years old (BMI 26)

**Number of Treatments**

**8 V-FORM**



**Before**



**After**



# 6 cm Circumferential Reduction

**Case Study – VF#013-C**

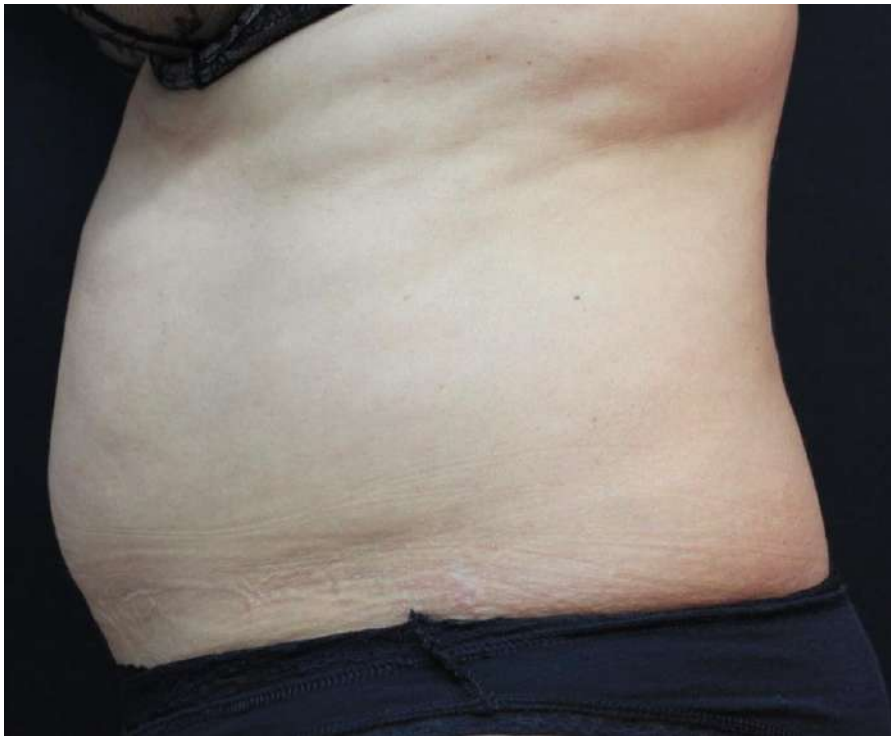**Dr. Cruzy Tagger, Viora Ltd.**

**Patient**

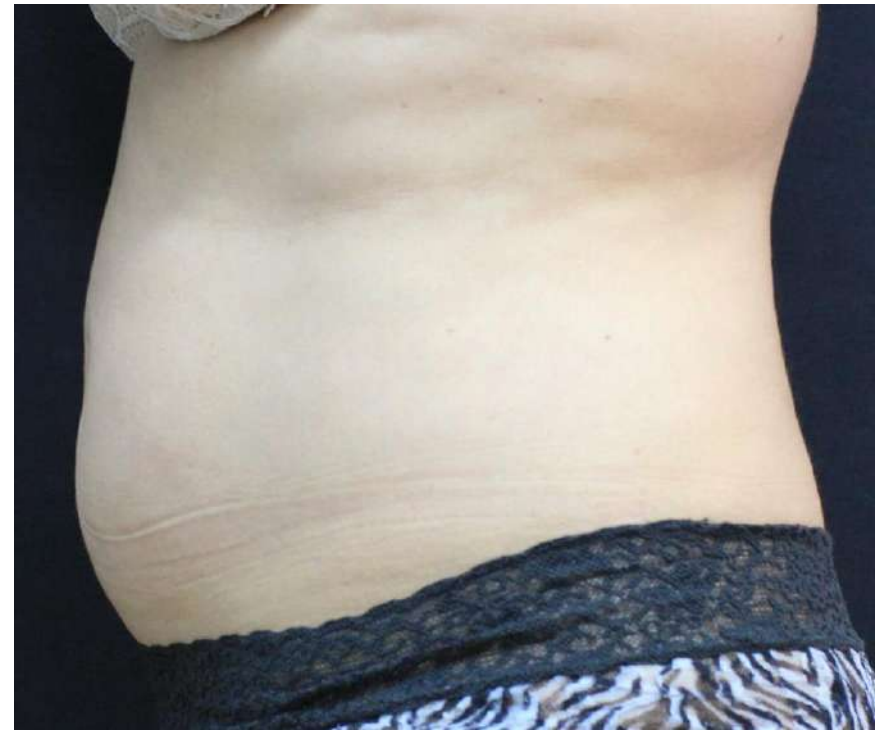Female, 56 years old (BMI 26)

**Number of Treatments**

**8 V-FORM**



**Before**



**After**



# 15 cm Circumferential Reduction

**Case Study – VF#019-A**

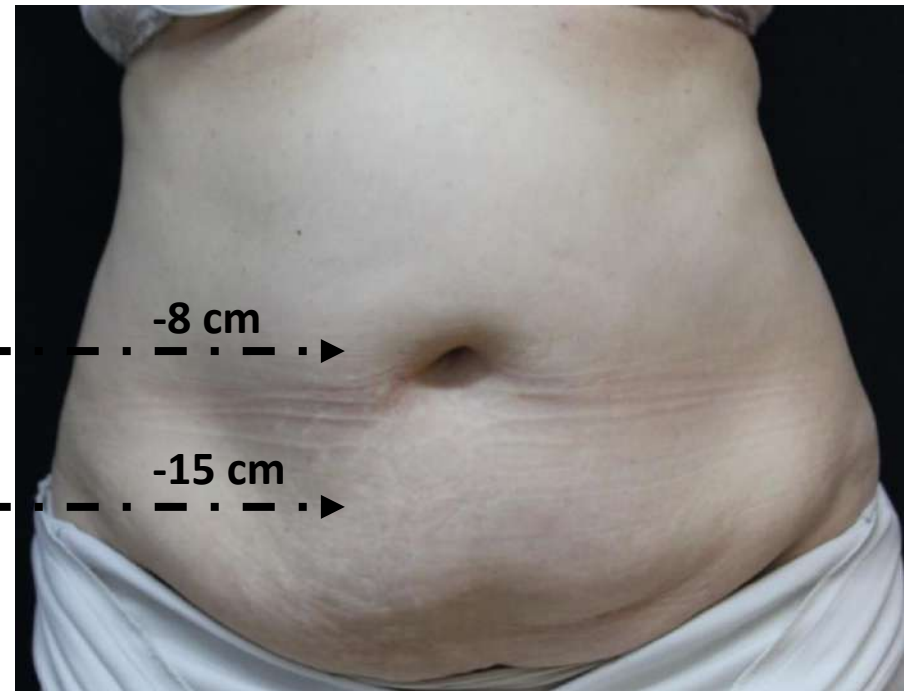
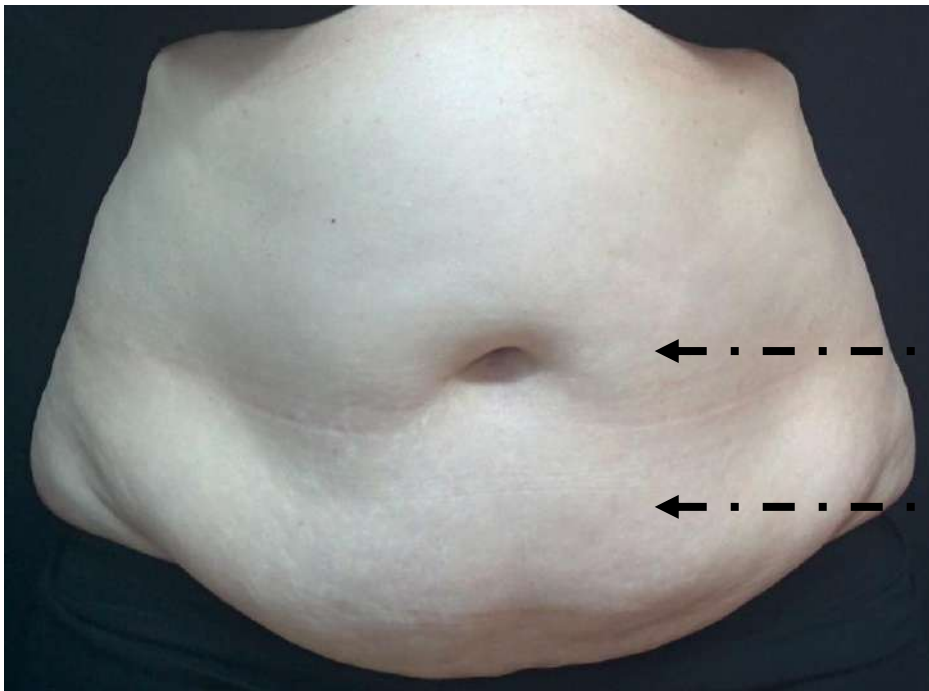
**Dr. Inna Belenky, Viora Ltd.**

**Patient**

Female, 70 years old (BMI 31)

**Number of Treatments**

**8 V-FORM**



**Before**

**4 weeks after 8 treatments**



# 15 cm Circumferential Reduction

**Case Study – VF#019-B**

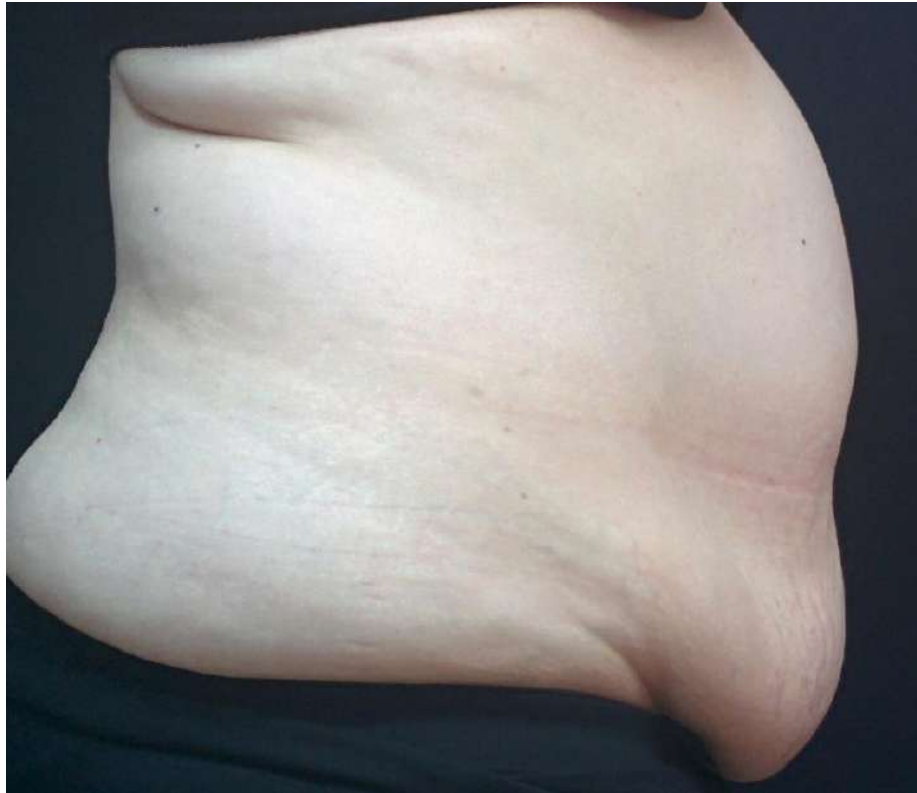**Dr. Inna Belenky, Viora Ltd.**

**Patient**

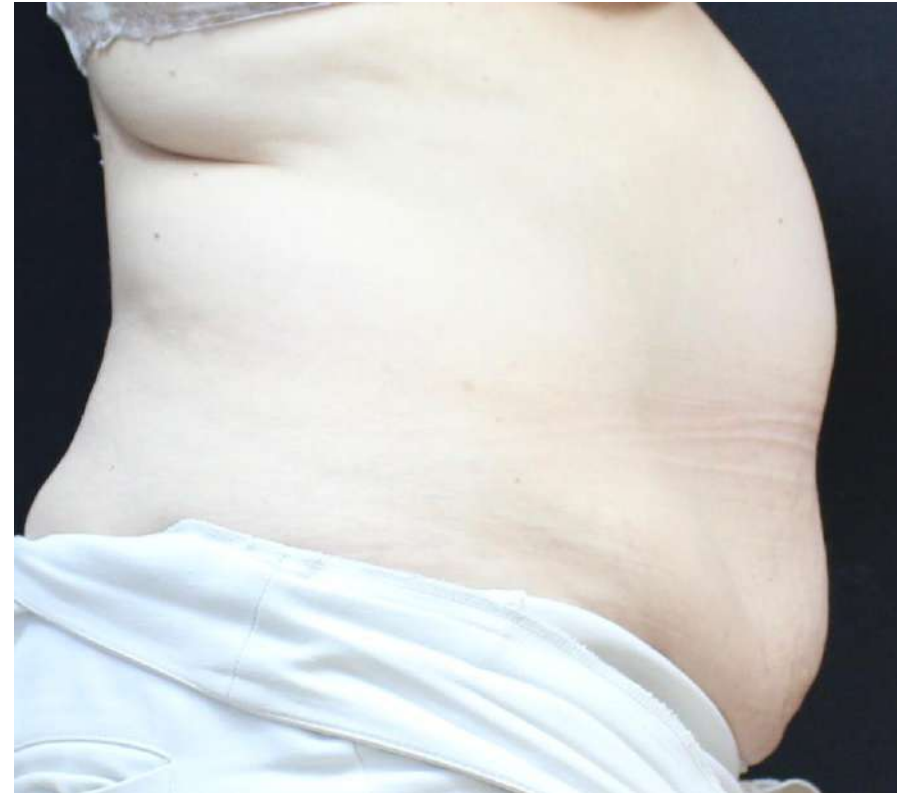Female, 70 years old (BMI 31)

**Number of Treatments**

**8 V-FORM**



**Before**



**4 weeks after 8 treatments**



# 15 cm Circumferential Reduction

**Case Study – VF#019-C**

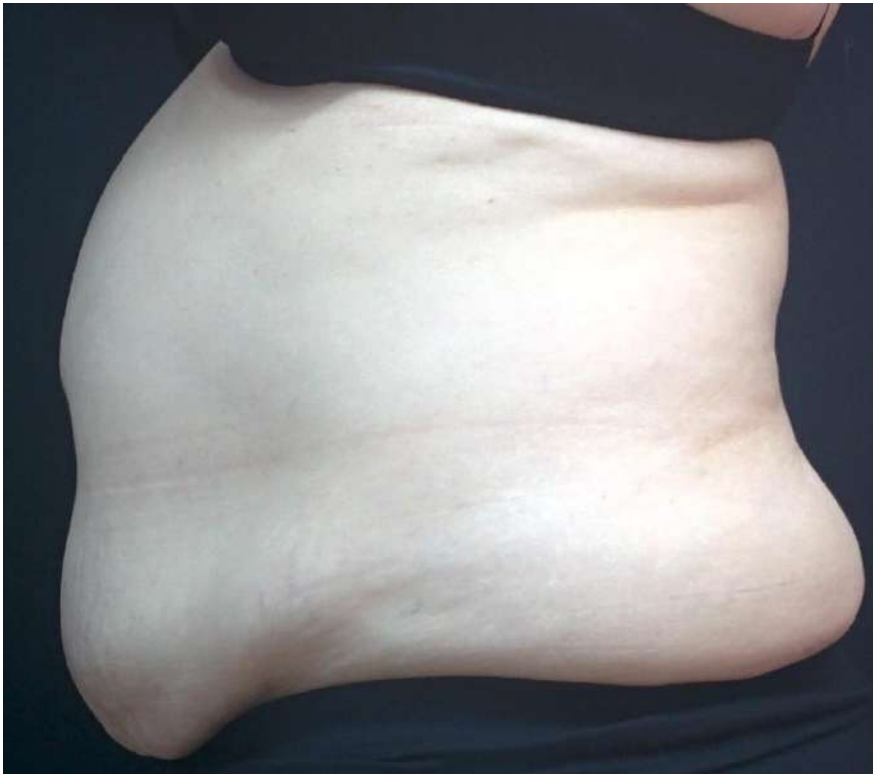**Dr. Inna Belenky, Viora Ltd.**

**Patient**

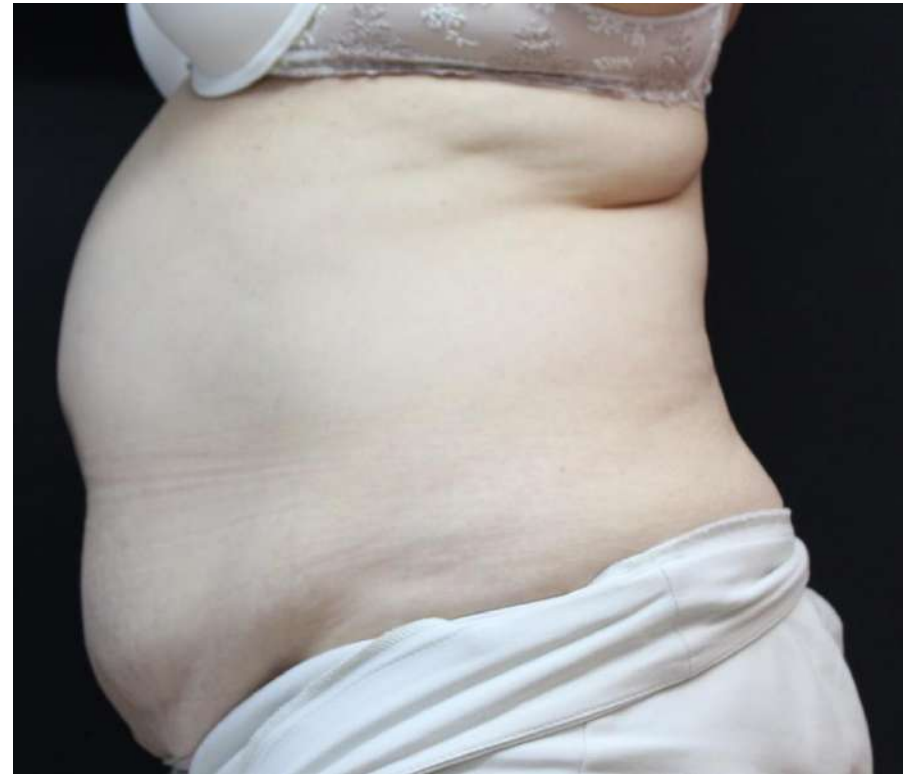Female, 70 years old (BMI 31)

**Number of Treatments**

**8 V-FORM**



**Before**



**4 weeks after 8 treatments**



# 4.5 cm Circumferential Reduction

**Case Study – VF#022-A**

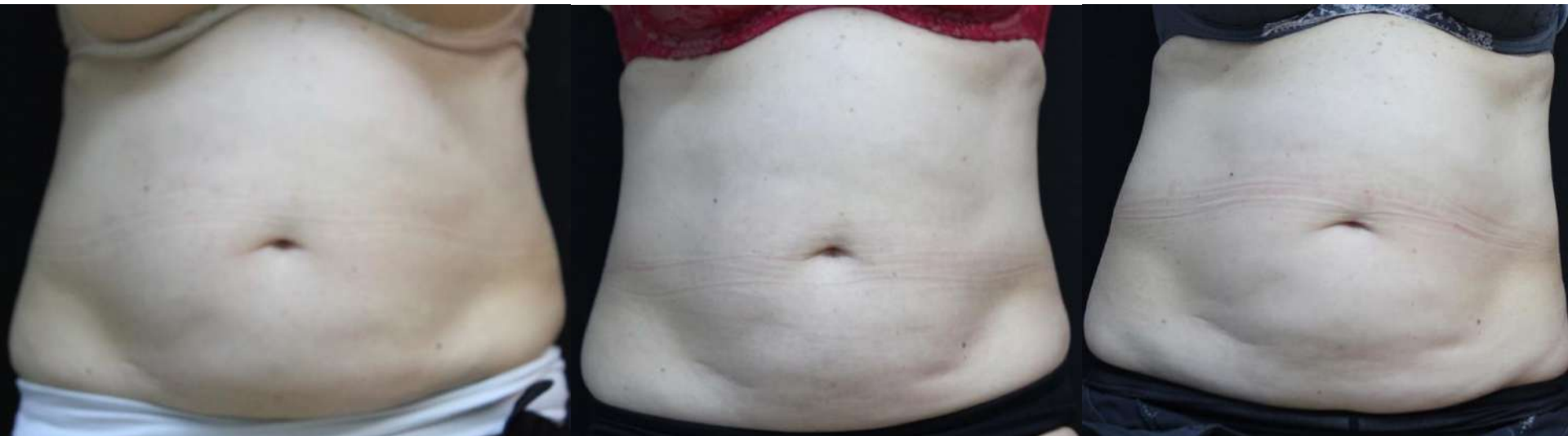**Dr. Cruzy Tagger, Viora Ltd.**

**Patient**

Female, 61 years old (BMI 27)

**Number of Treatments**

**5 V-FORM**



**Before**

**After 4 Tx**

**After 5 Tx**





# 4.5 cm Circumferential Reduction

**Case Study – VF#022-B**

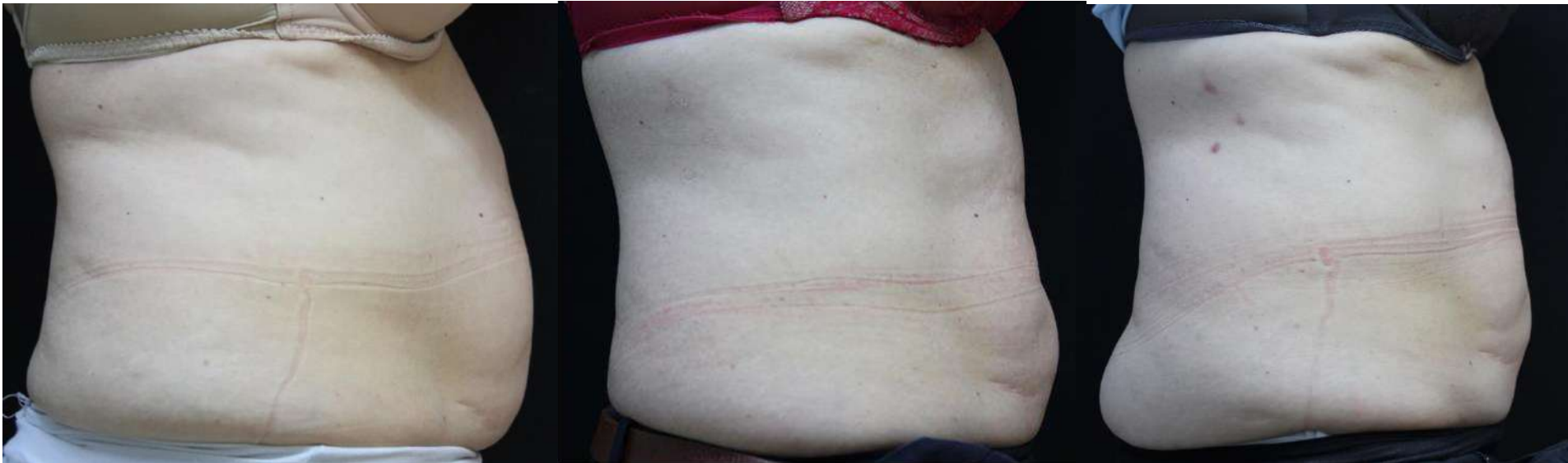**Dr. Cruzy Tagger, Viora Ltd.**

**Patient**

Female, 61 years old (BMI 27)

**Number of Treatments**

**5 V-FORM**



**Before**

**After 4 Tx**

**After 5 Tx**



# 3.5 cm Circumferential Reduction

**Case Study – VF#022-C**

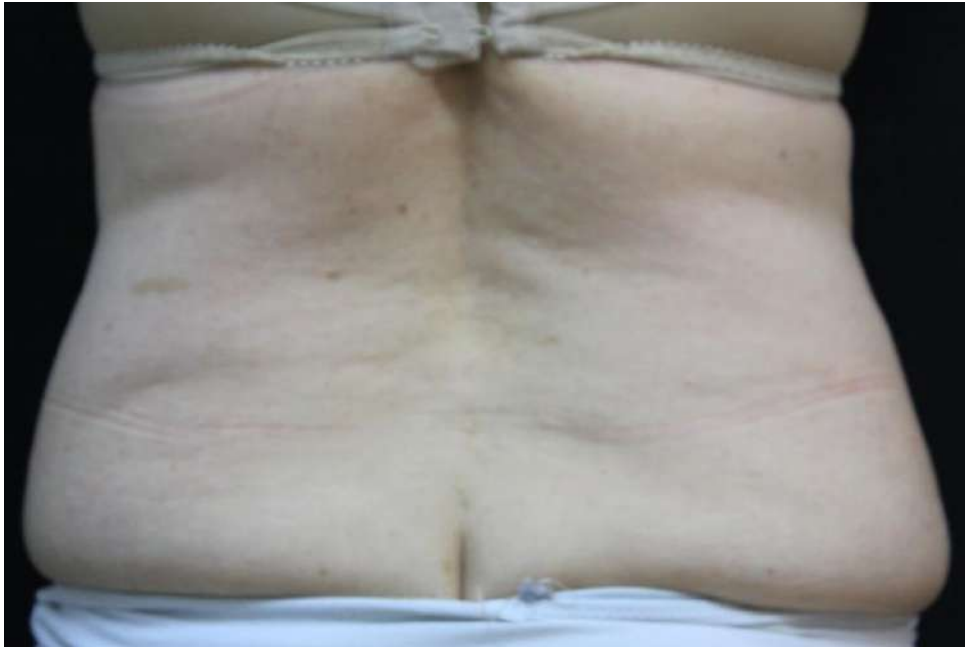**Dr. Cruzy Tagger, Viora Ltd.**

**Patient**

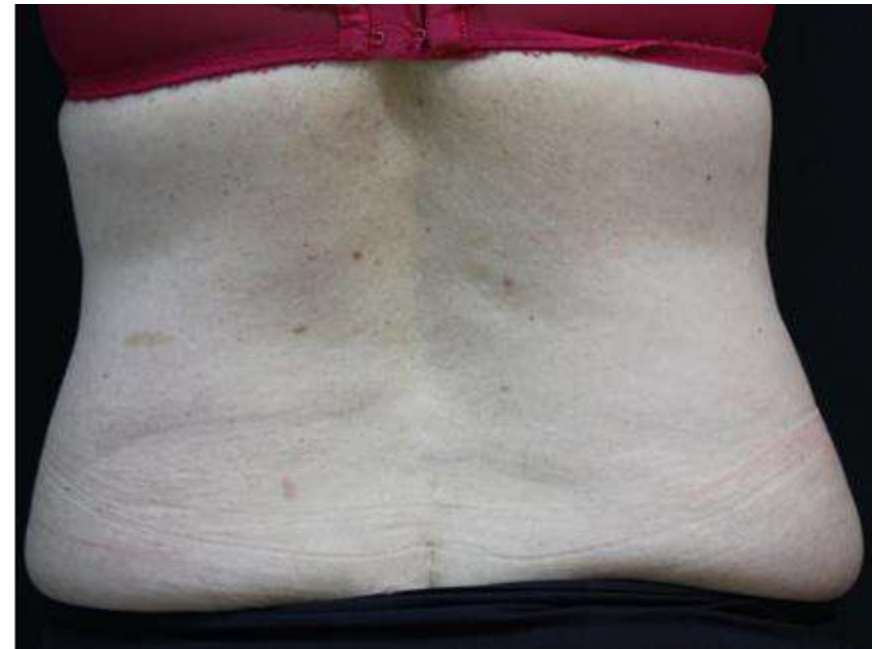Female, 61 years old (BMI 27)

**Number of Treatments**

**4 V-FORM**



**Before**



**After**



# 3.5 cm Circumferential Reduction

**Case Study – VF#022-D**

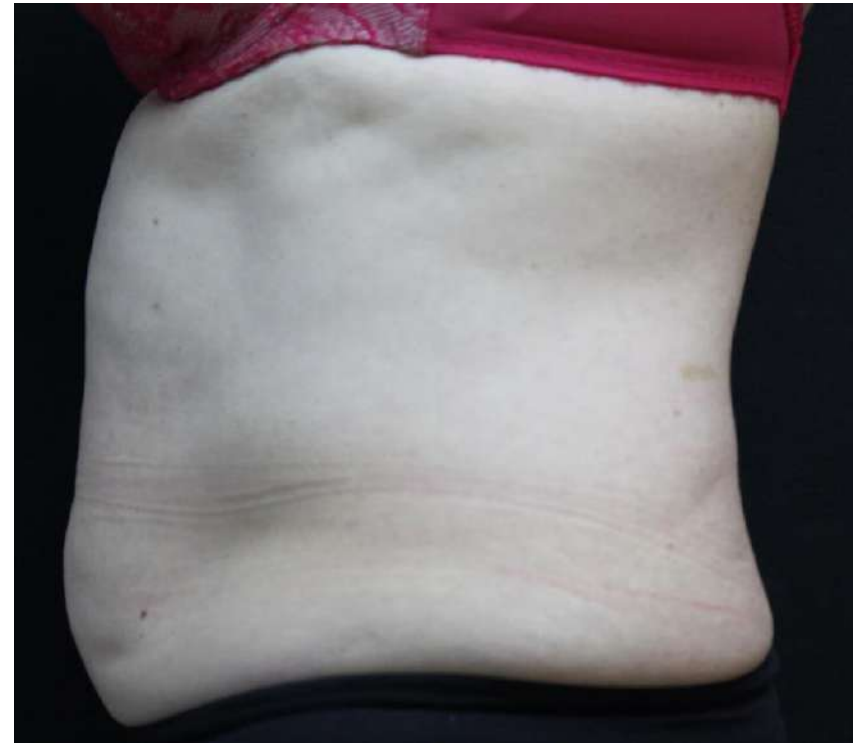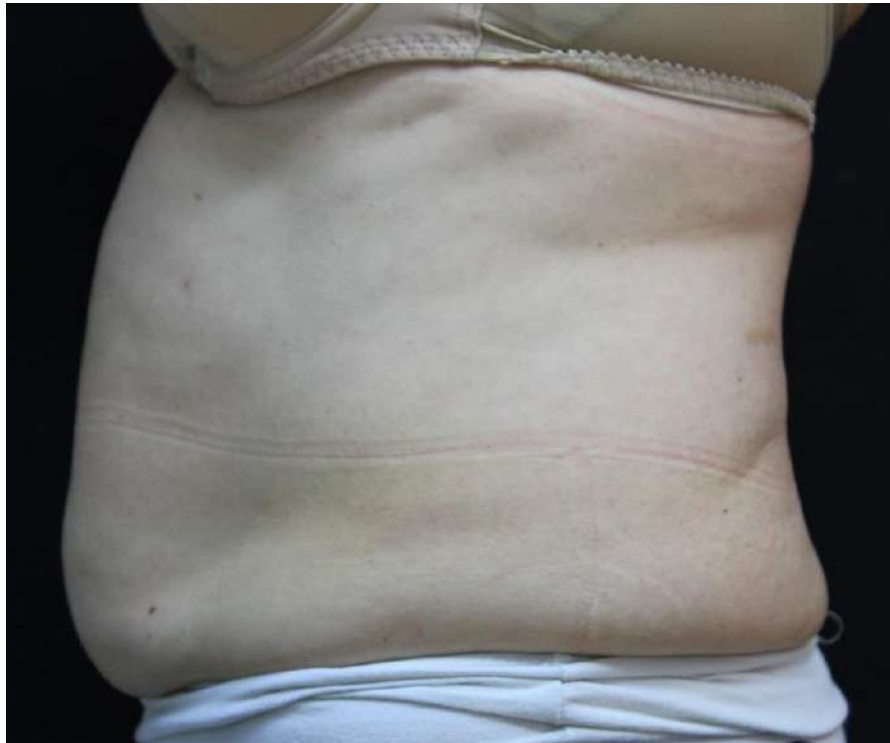**Dr. Cruzy Tagger, Viora Ltd.**

**Patient**

Female, 61 years old (BMI 27)

**Number of Treatments**

**4 V-FORM**



**Before**

**After**



# Circumferential Reduction

**Case Study – VF#031**

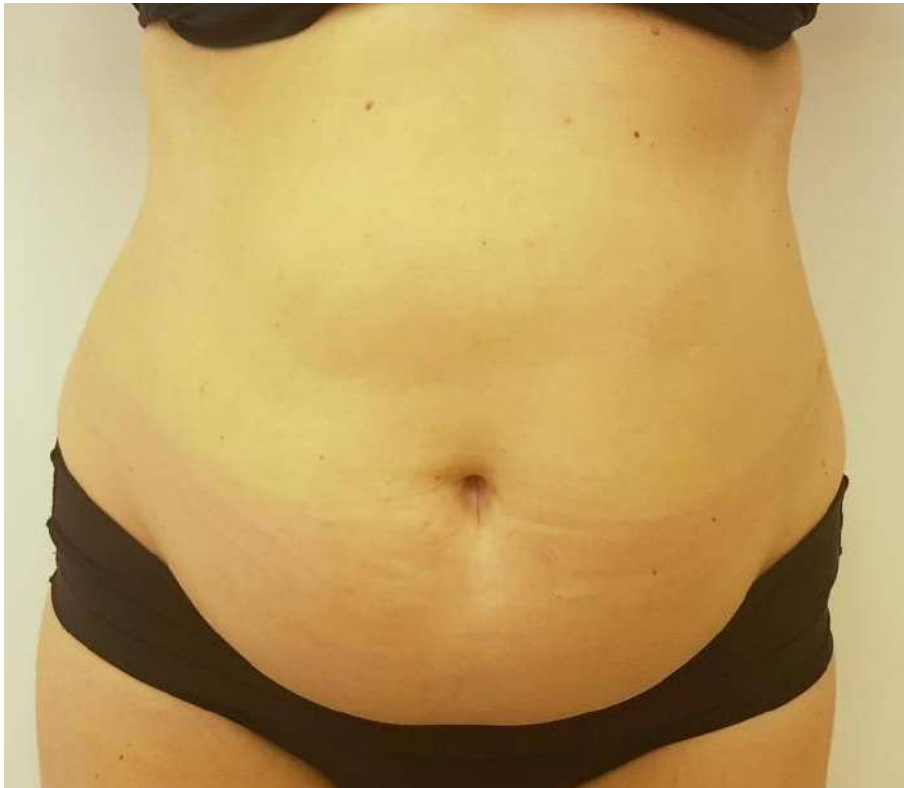**Viora Ltd.**

Patient

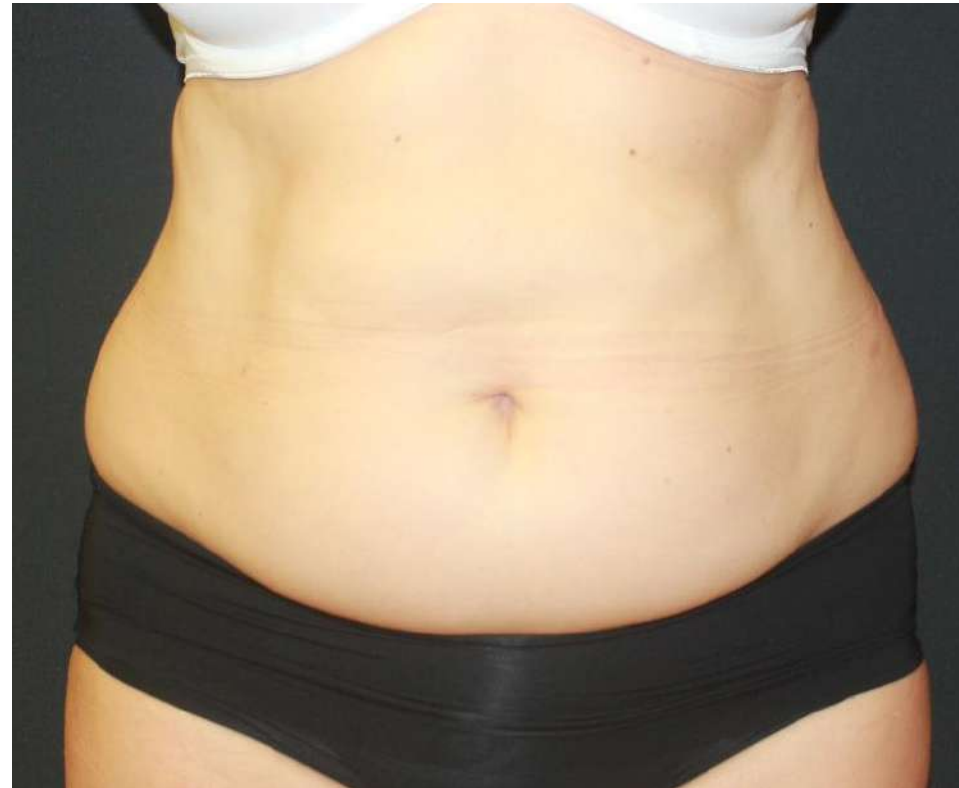Female, 45 years old (BMI 27)

**Number of Treatments**

**6 V-FORM**



**Before**



**1 week after 6 treatments**



# 9 cm Circumferential Reduction

**Case Study – VF#036-A**

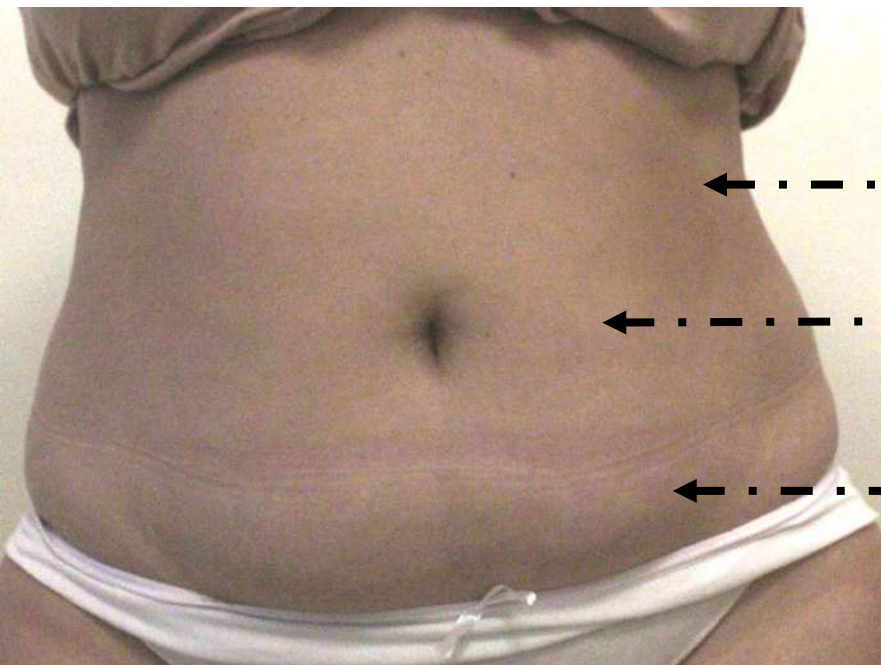
**Dr. Cruzy Tagger, Viora Ltd.**

**Patient**

Female, 52 years old (BMI 29)

**Number of Treatments**

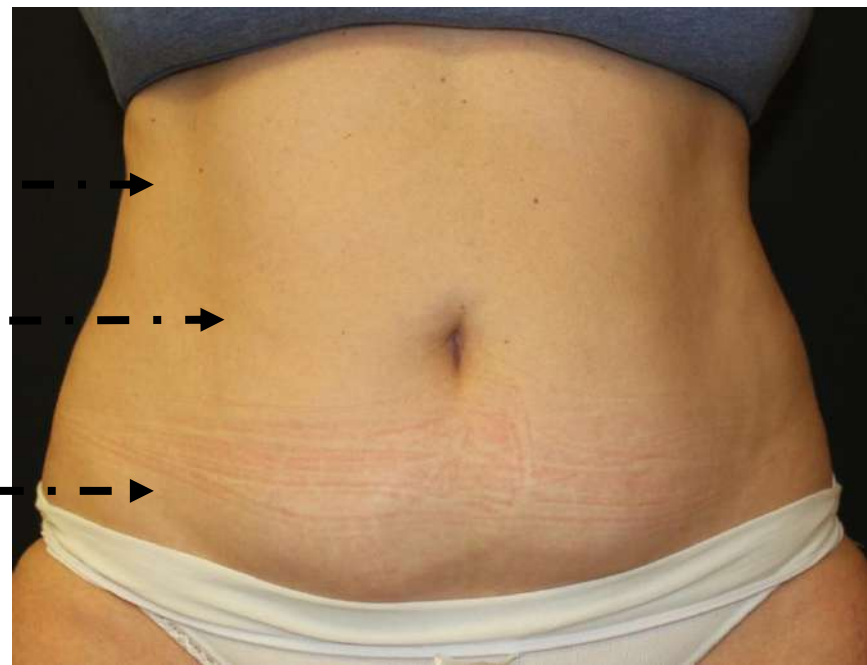
**3 V-FORM**



- 5 cm

- 9 cm

- 4 cm



**Before**

**After**



# 9 cm Circumferential Reduction

**Case Study – VF#036-B**

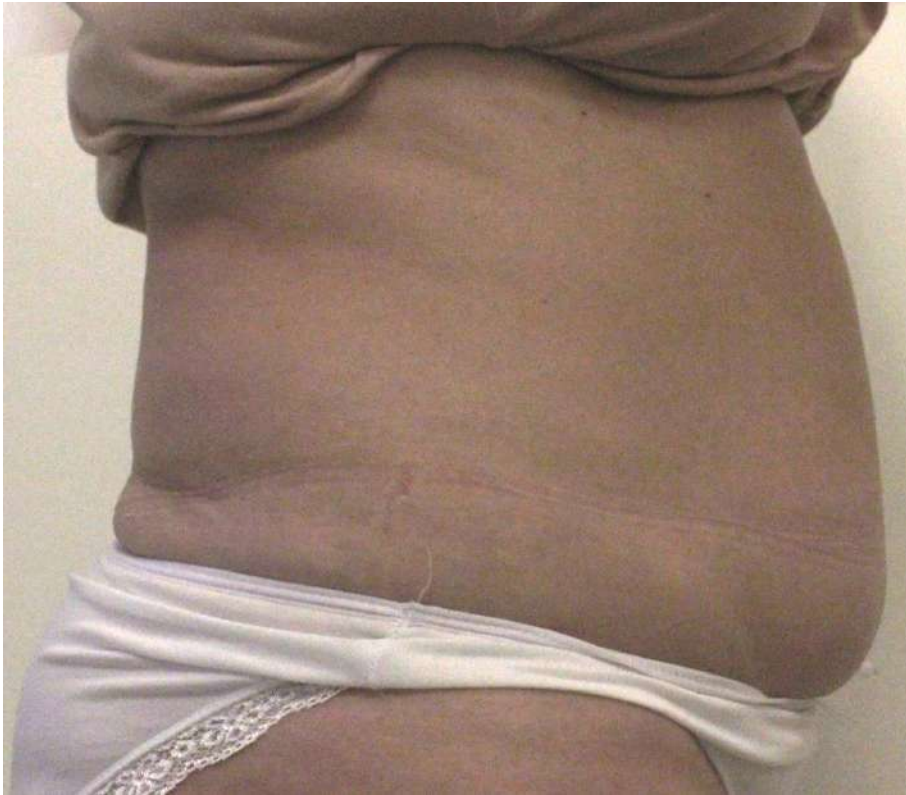**Dr. Cruzy Tagger, Viora Ltd.**

**Patient**

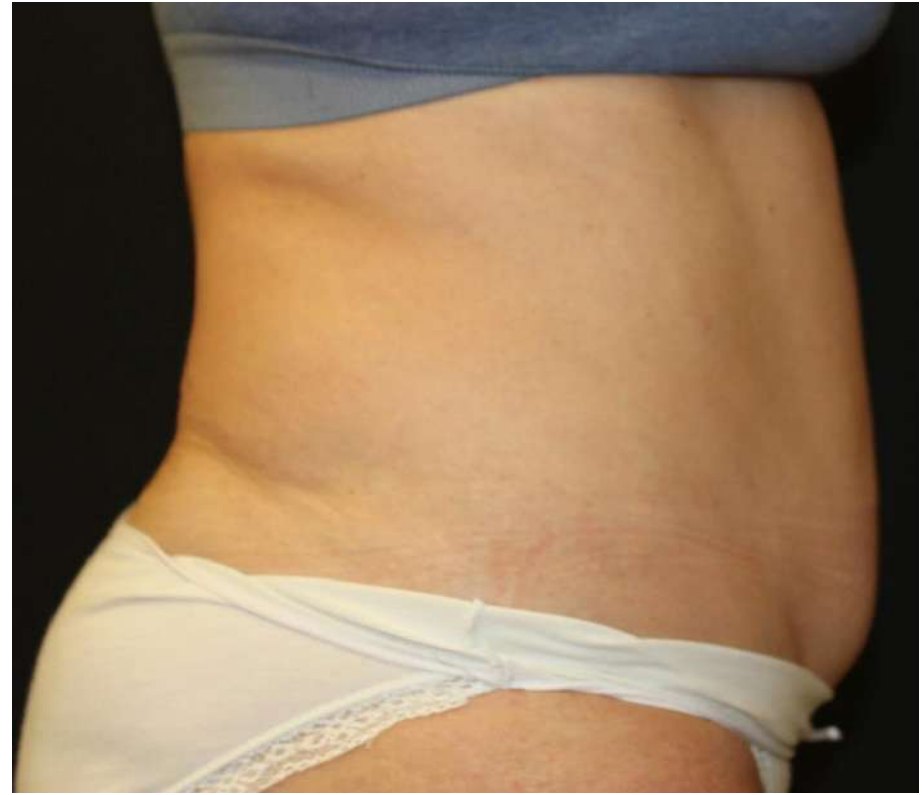Female, 52 years old (BMI 29)

**Number of Treatments**

**3 V-FORM**



**Before**



**After**



# 9 cm Circumferential Reduction

**Case Study – VF#036-C**

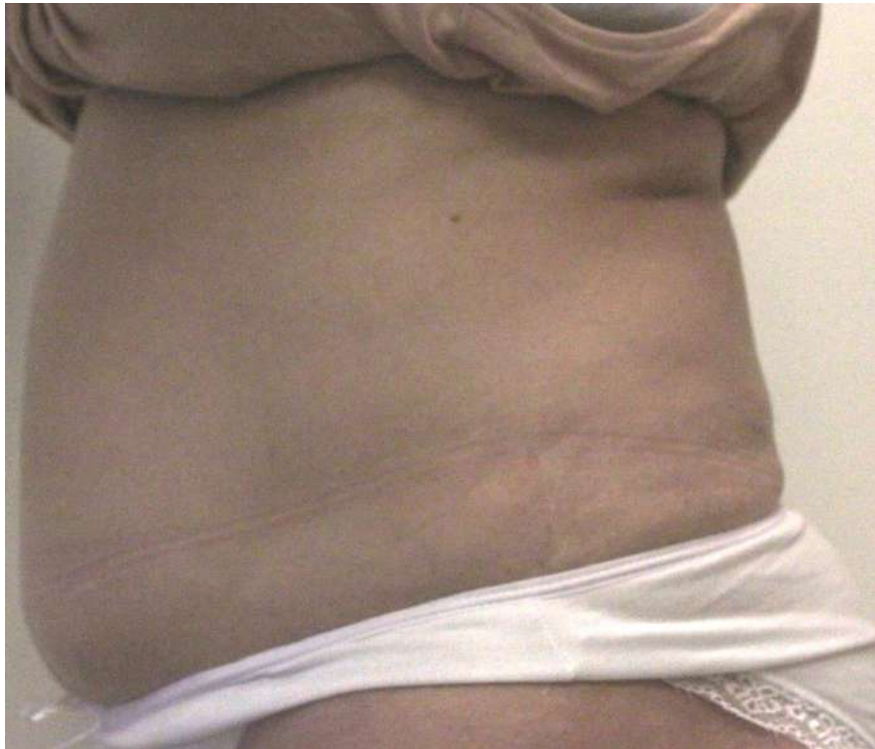**Dr. Cruzy Tagger, Viora Ltd.**

**Patient**

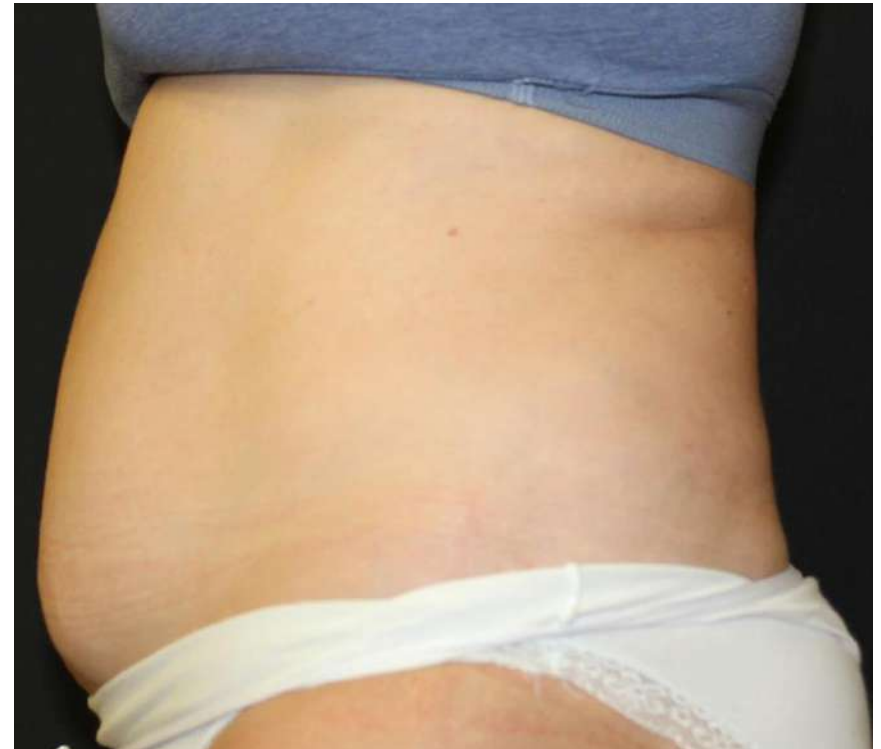Female, 52 years old (BMI 29)

**Number of Treatments**

**3 V-FORM**



**Before**



**After**



# 3 cm Circumferential Reduction

**Case Study – VF#041**

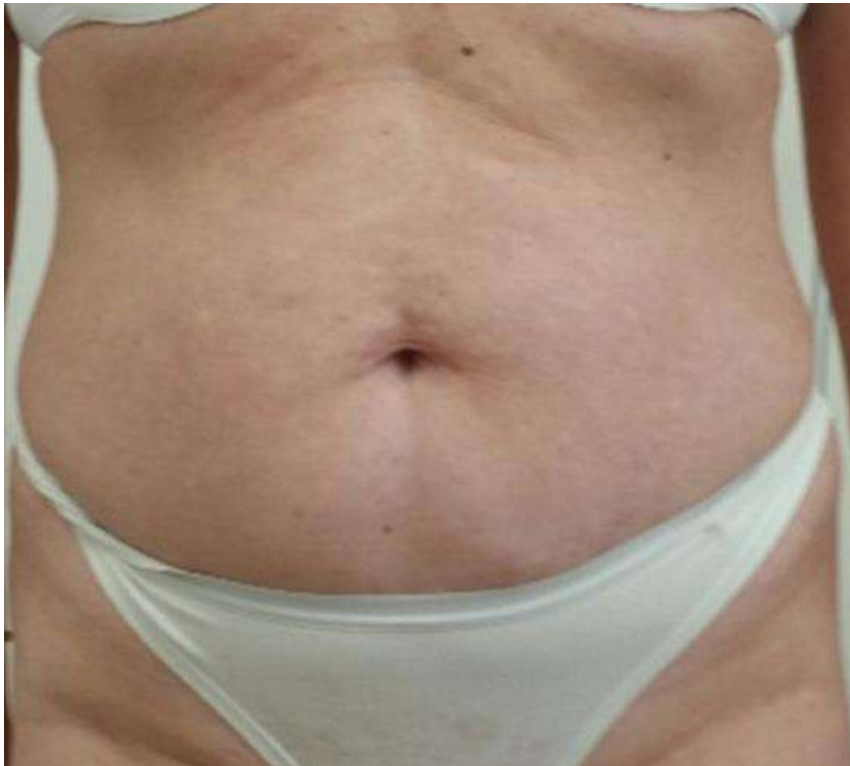**Dr. Lehavit Akerman, Herzeliya, Israel**

**Patient**

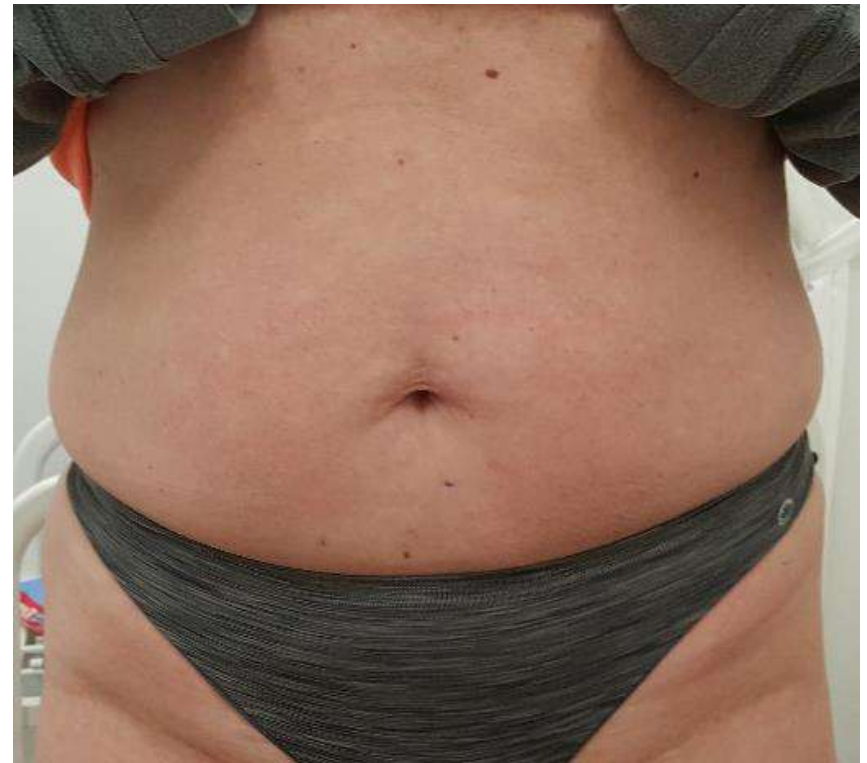Female, 47 years old

**Number of Treatments**

**6 V-FORM**



**Before**



**After**





# Back Contouring

**Case Study – VF#042**

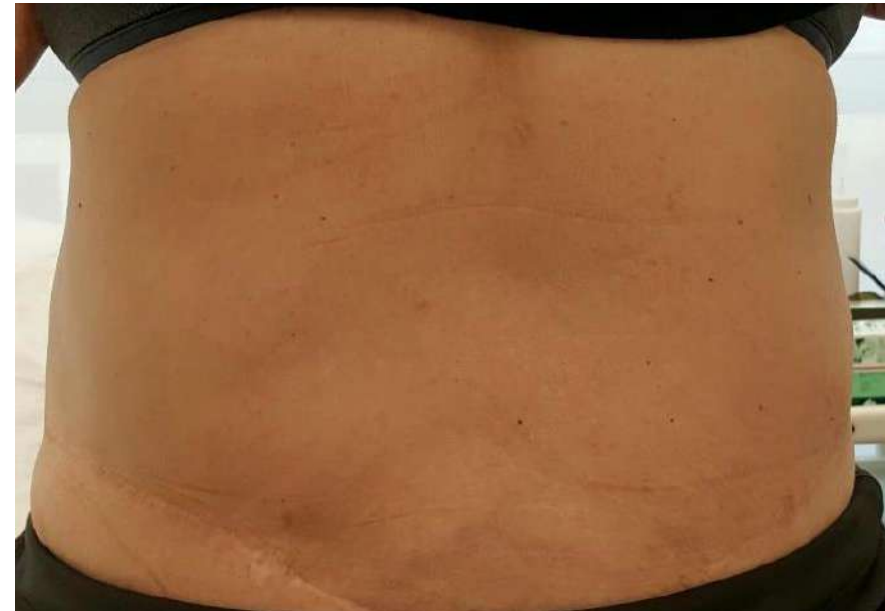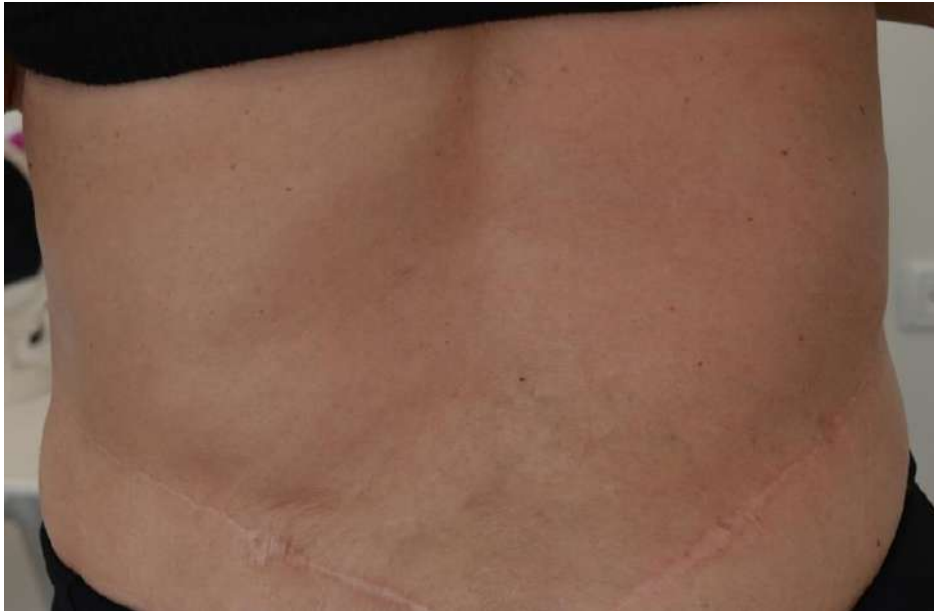**Dr. Lehavit Akerman, Herzeliya, Israel**

**Patient**

Female, 56 years old

**Number of Treatments**

**4 V-FORM**



**Before**

**After**



# 5 cm Circumferential Reduction

**Case Study – VF#48-A**

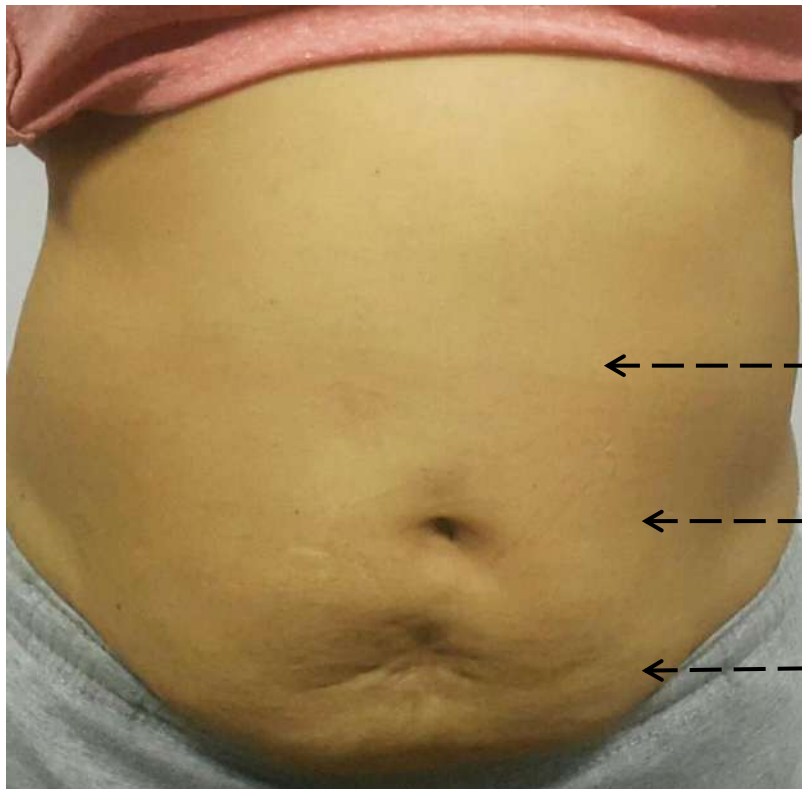**Dr. Theint Han Htwe, Yangon, Myanmar**

**Patient**

Female, 58 years old (BMI 24)

**Number of Treatments**

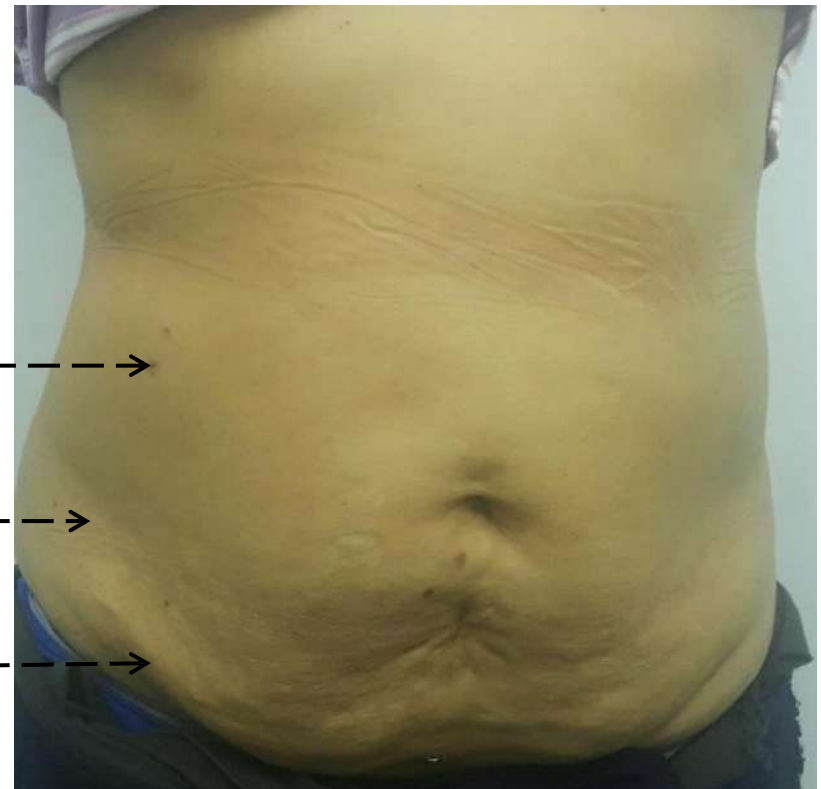**3 V-FORM (4 week before 1 lipo-injection)**



2 cm

4 cm

5 cm



**Before**

**After**



# 5 cm Circumferential Reduction

**Case Study – VF#48-B**

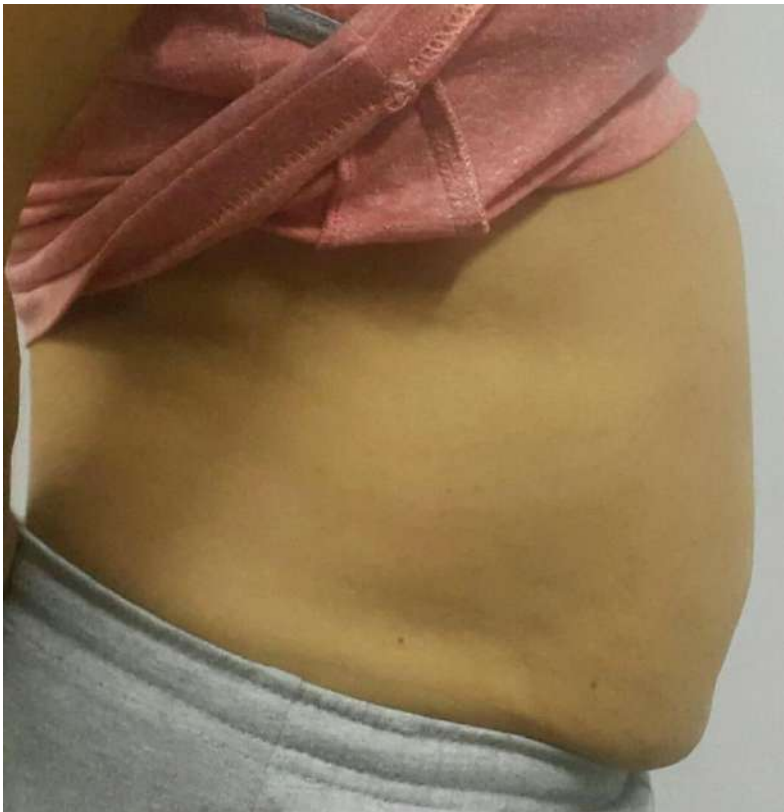**Dr. Theint Han Htwe, Yangon, Myanmar**

**Patient**

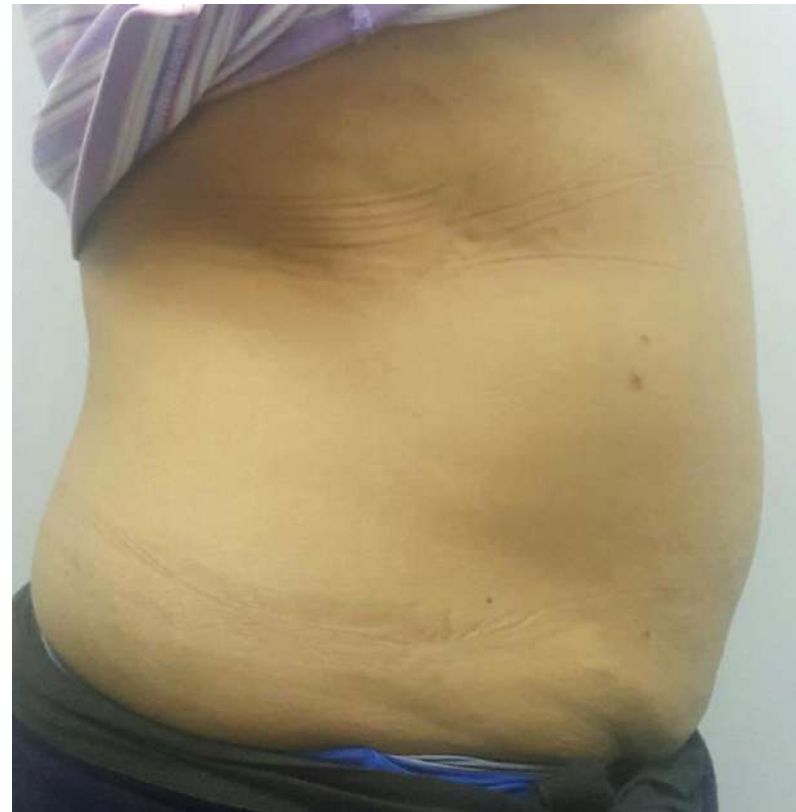Female, 58 years old (BMI 24)

**Number of Treatments**

**3 V-FORM (4 week before 1 lipo-injection)**



**Before**



**After**



# 5 cm Circumferential Reduction

**Case Study – VF#48-C**

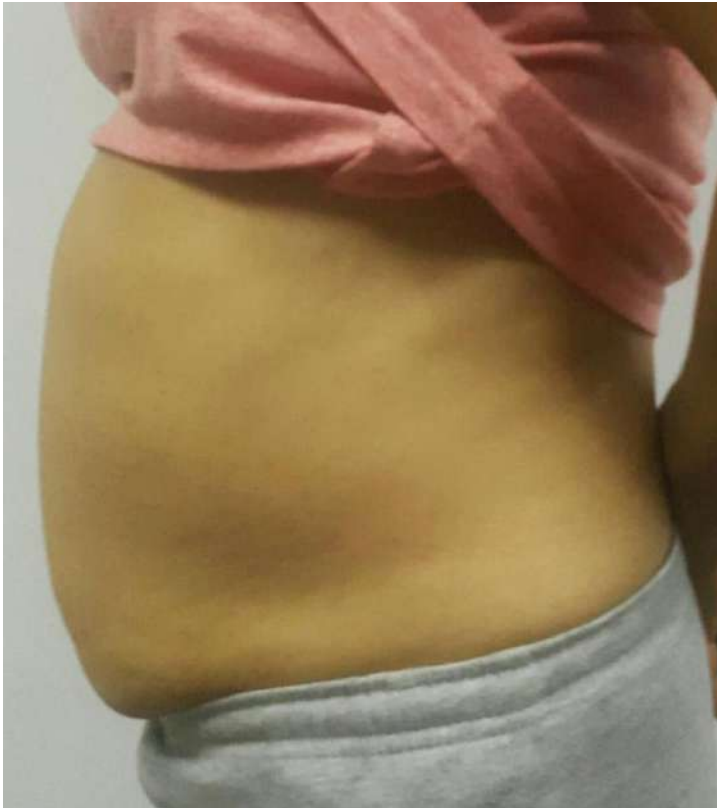**Dr. Theint Han Htwe, Yangon, Myanmar**

**Patient**

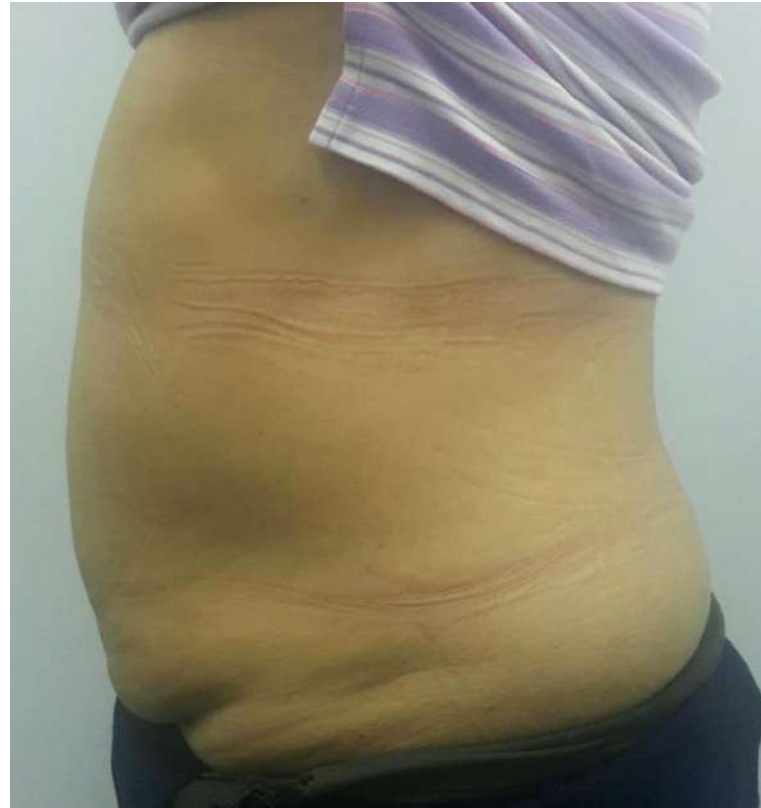Female, 58 years old (BMI 24)

**Number of Treatments**

**3 V-FORM (4 week before 1 lipo-injection)**



**Before**



**After**



# 5 cm Circumferential Reduction

**Case Study – VF#49-A**

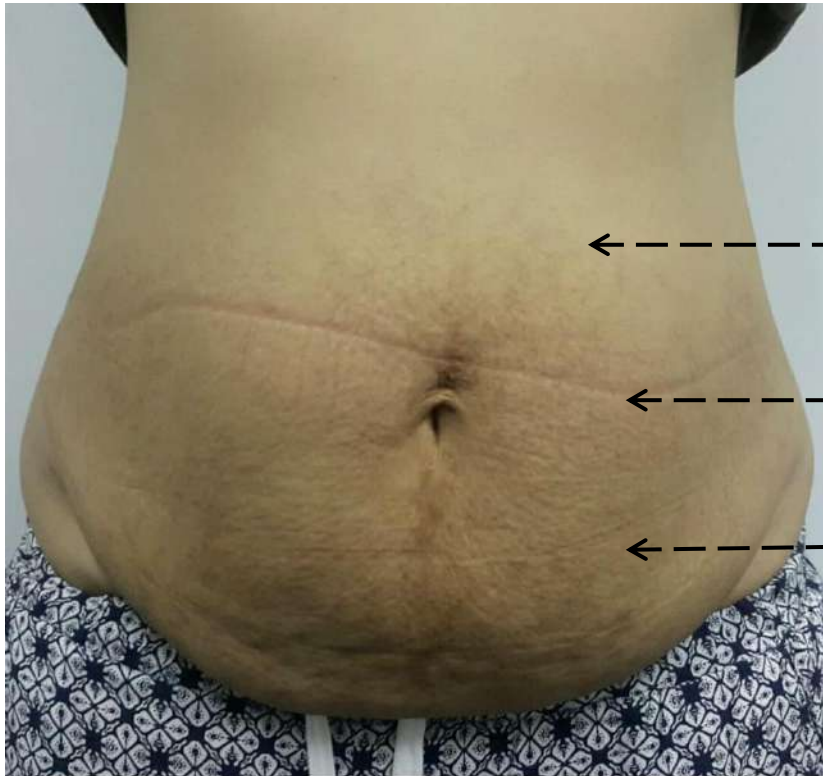**Dr. Theint Han Htwe, Yangon, Myanmar**

**Patient**

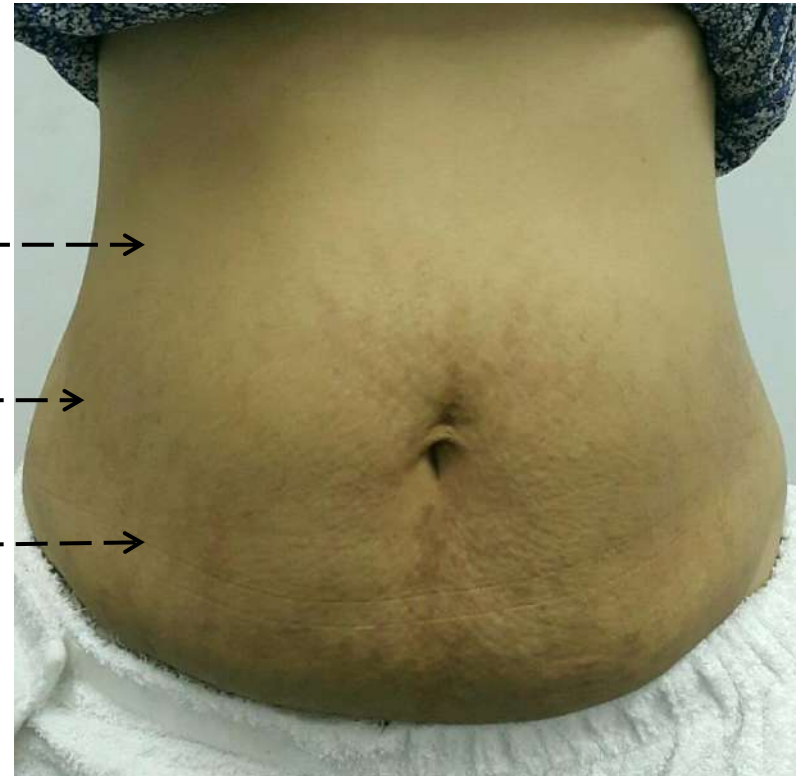
Female, 29 years old (BMI 26)

**Number of Treatments**

**1 V-FORM** (gym immediately post V-FORM)



**Before**



**After**



# 5 cm Circumferential Reduction

**Case Study – VF#49-B**

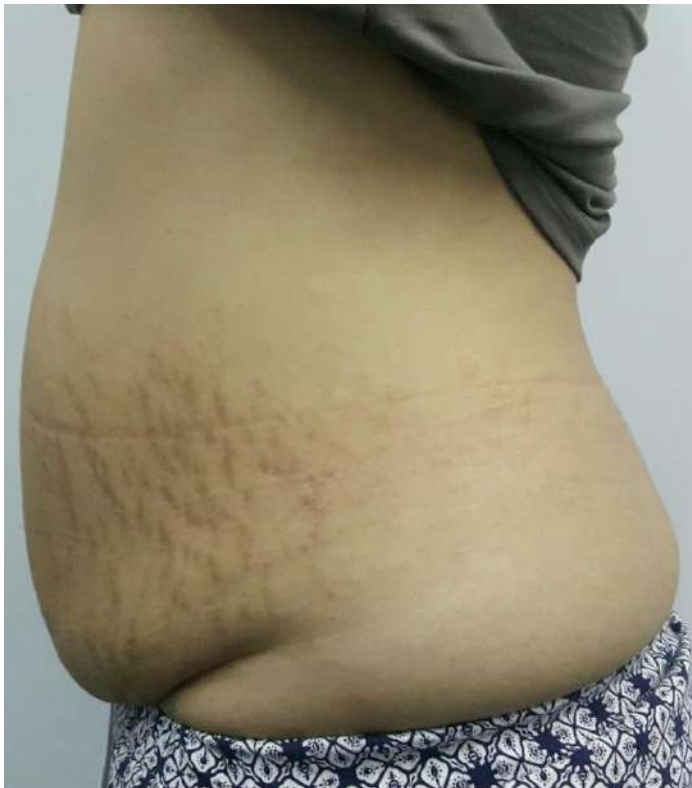**Dr. Theint Han Htwe, Yangon, Myanmar**

**Patient**

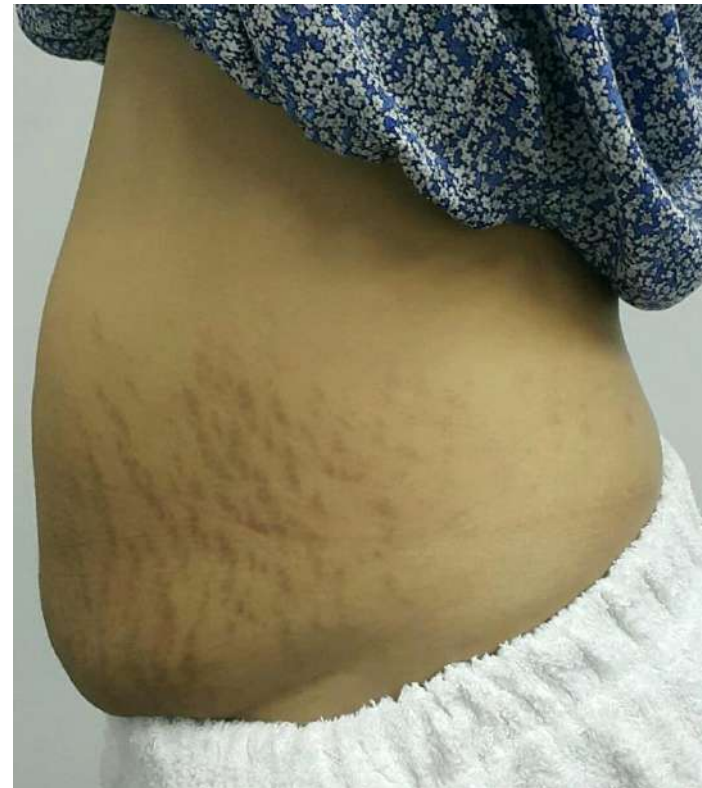Female, 29 years old (BMI 26)

**Number of Treatments**

**1 V-FORM** (gym immediately post V-FORM)



**Before**



**After**



# 5 cm Circumferential Reduction

**Case Study – VF#49-C**

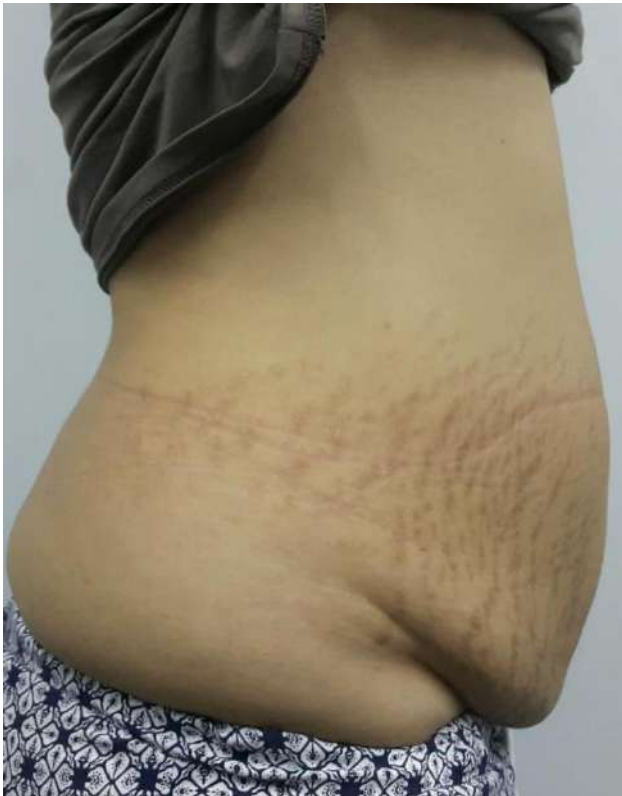**Dr. Theint Han Htwe, Yangon, Myanmar**

**Patient**

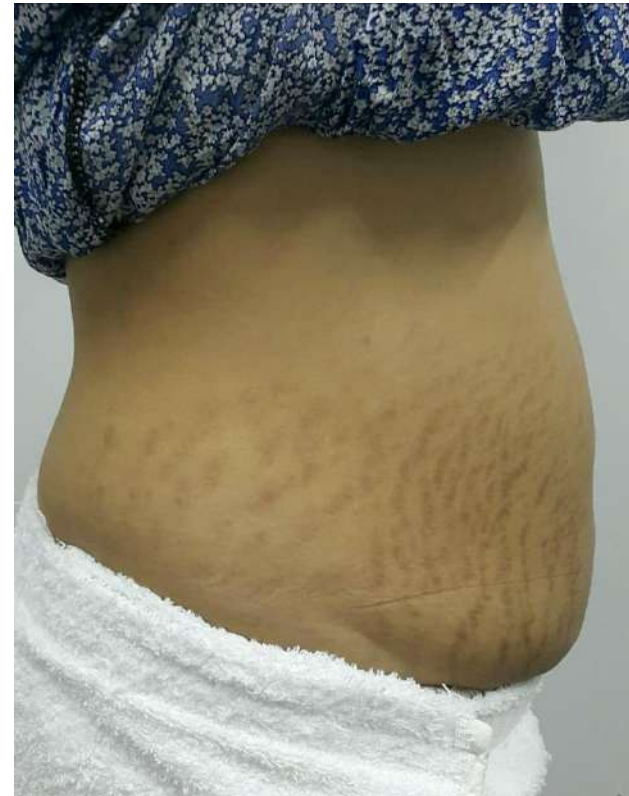Female, 29 years old (BMI 26)

**Number of Treatments**

**1 V-FORM** (gym immediately post V-FORM)



**Before**



**After**



# 5 cm Circumferential Reduction

**Case Study – VF#49-A**

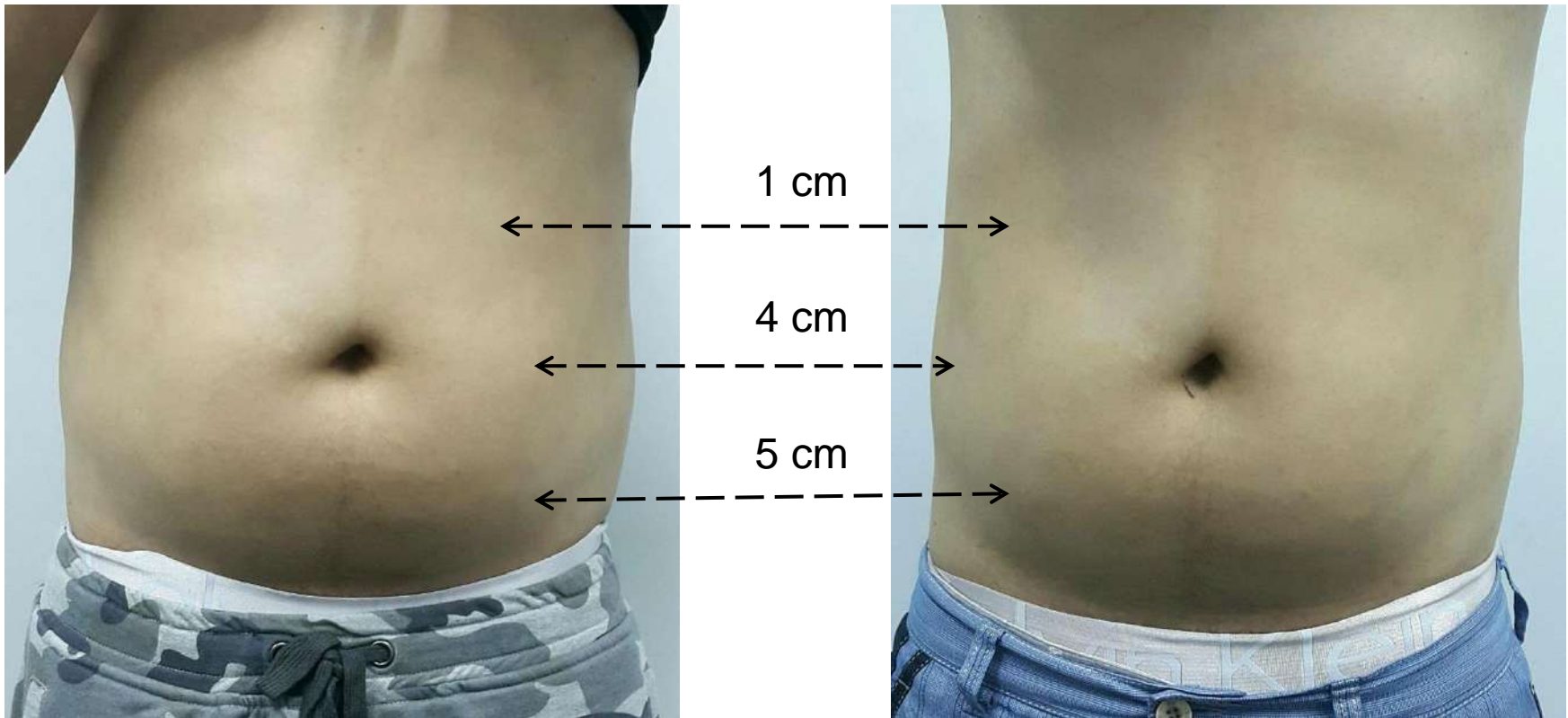
**Dr. Theint Han Htwe, Yangon, Myanmar**

**Patient**

Male, 35 years old (BMI 23)

**Number of Treatments**

**2 V-FORM (4 week before 1 lipo-injection)**



**Before**

**After**





# 5 cm Circumferential Reduction

**Case Study – VF#49-B**

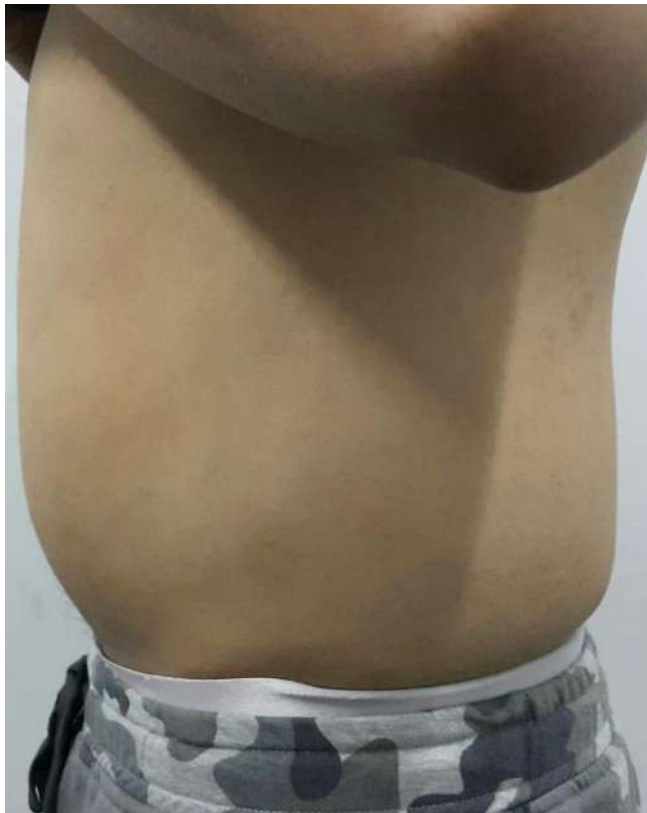**Dr. Theint Han Htwe, Yangon, Myanmar**

**Patient**

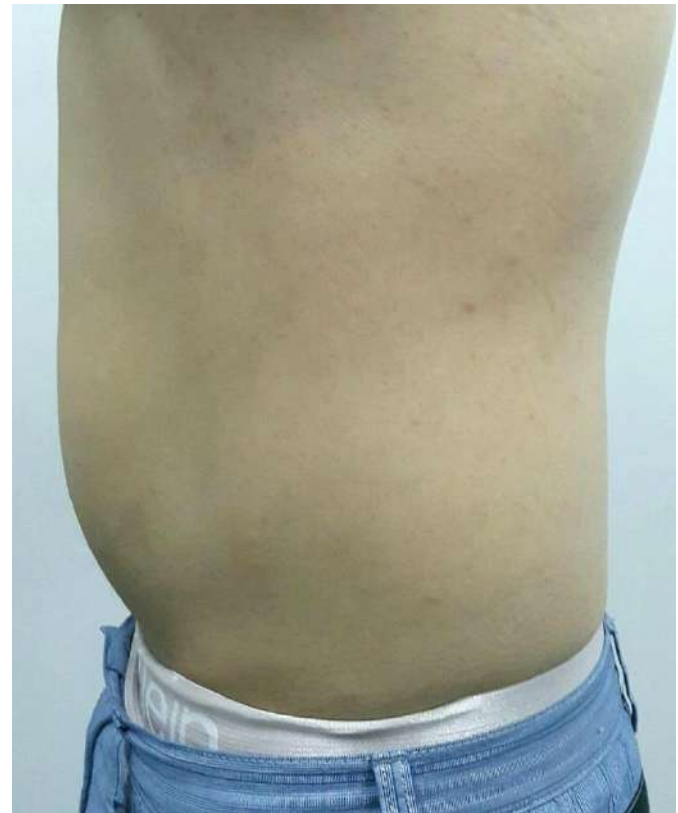Male, 35 years old (BMI 23)

**Number of Treatments**

**2 V-FORM (4 week before 1 lipo-injection)**



**Before**



**After**



# 5 cm Circumferential Reduction

**Case Study – VF#49-C**

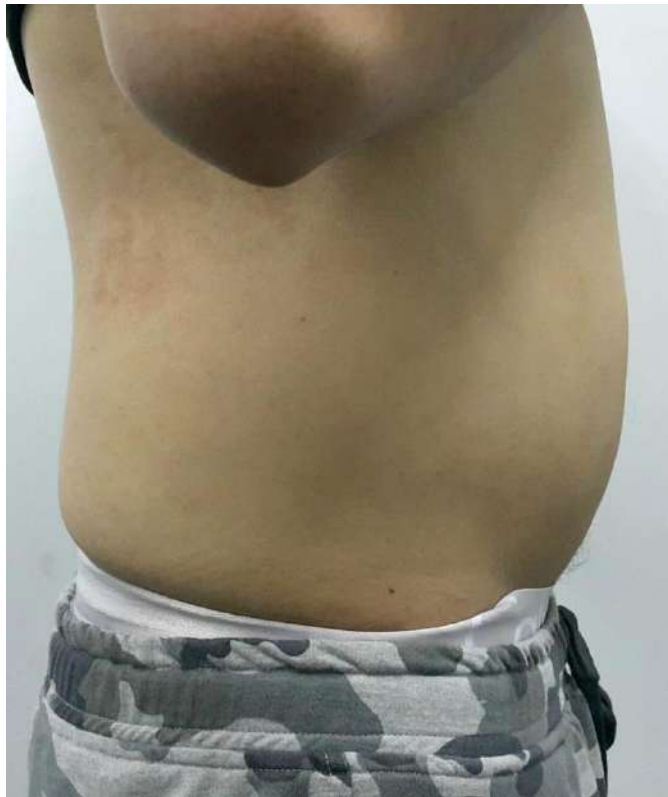**Dr. Theint Han Htwe, Yangon, Myanmar**

**Patient**

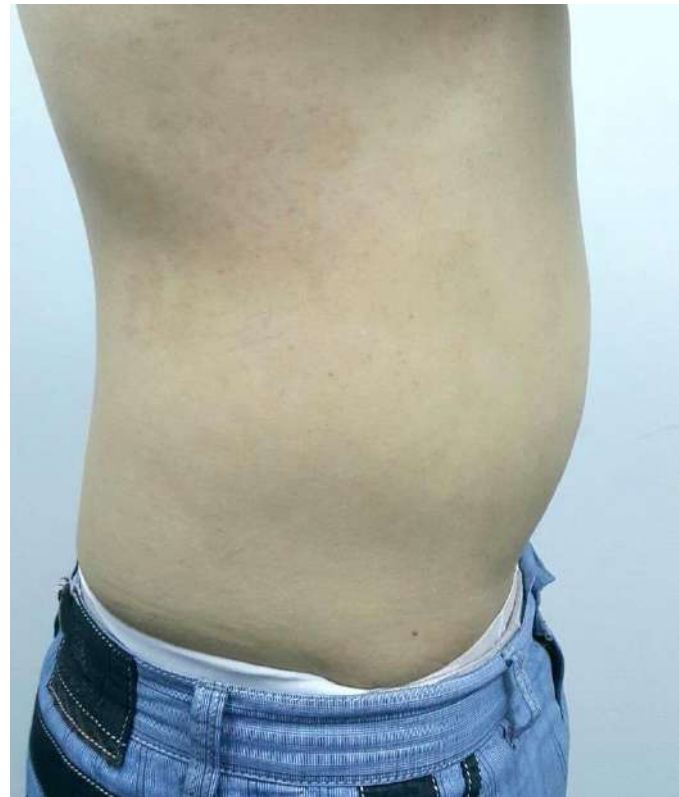Male, 35 years old (BMI 23)

**Number of Treatments**

**2 V-FORM (4 week before 1 lipo-injection)**



**Before**



**After**



# 2.2 cm Abdomen Circumferential Reduction

**Case Study – VF#056-A**

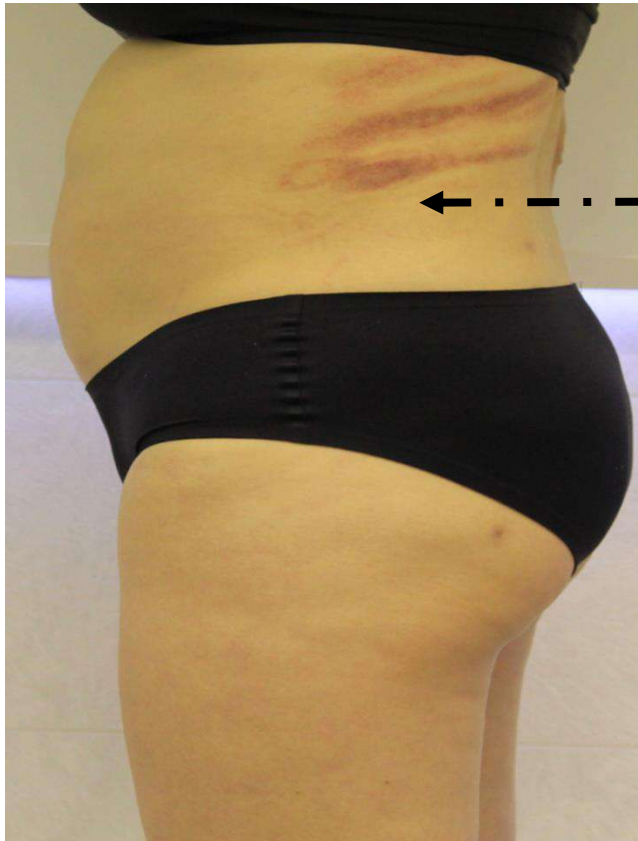**Dr. James K. M. Chan, Hong Kong**

**Patient**

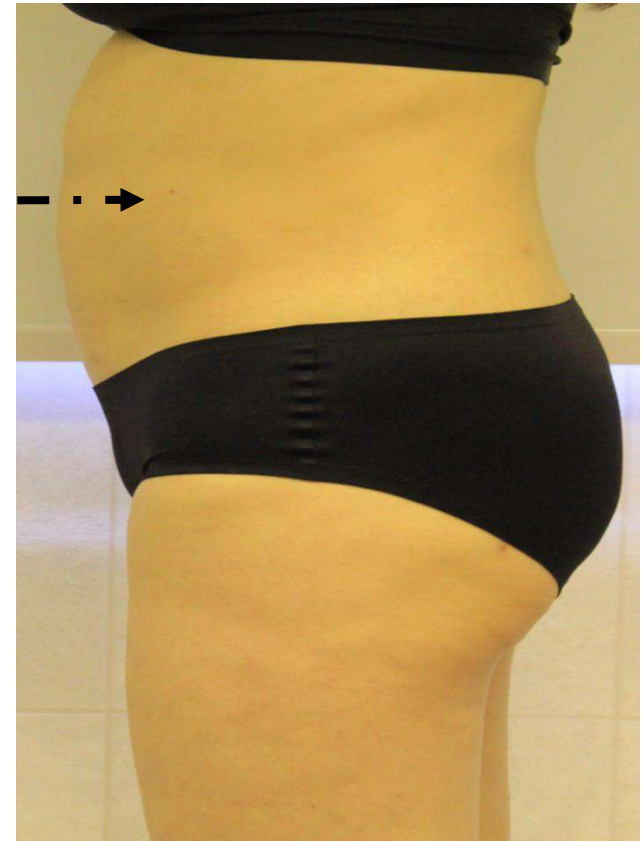
Female, 50 years old (Fitzpatrick IV, BMI 22)

**Number of Treatments**

**6 V-FORM**



- 2.2 cm



**Before**

**After**



# 2.2 cm Abdomen Circumferential Reduction

Case Study – VF#056-B

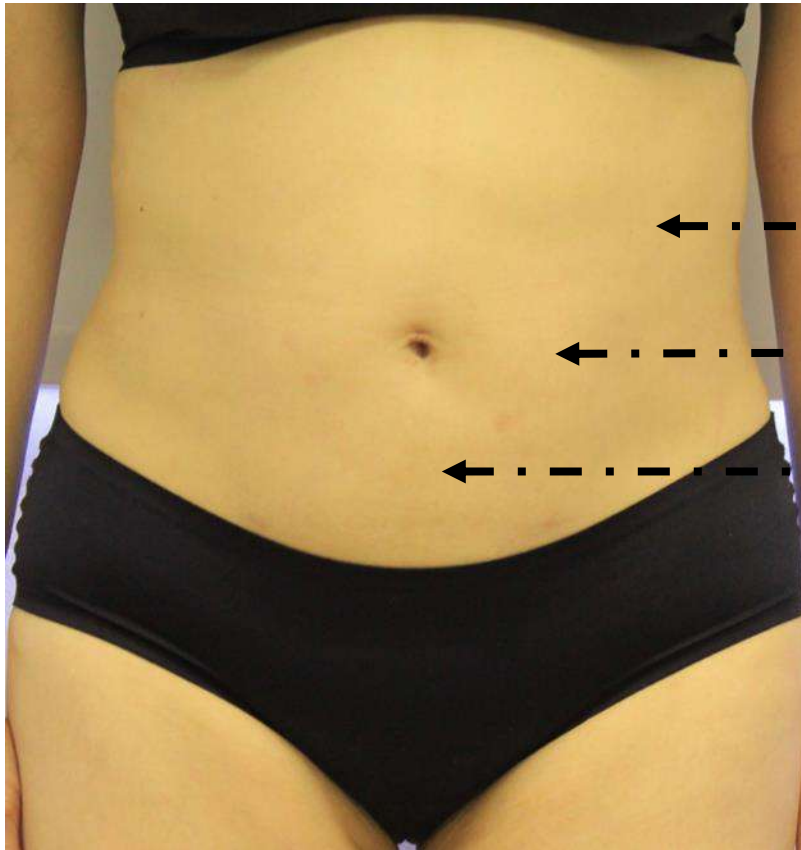Dr. James K. M. Chan, Hong Kong

Patient

Female, 50 years old (Fitzpatrick IV, BMI 22)

Number of Treatments

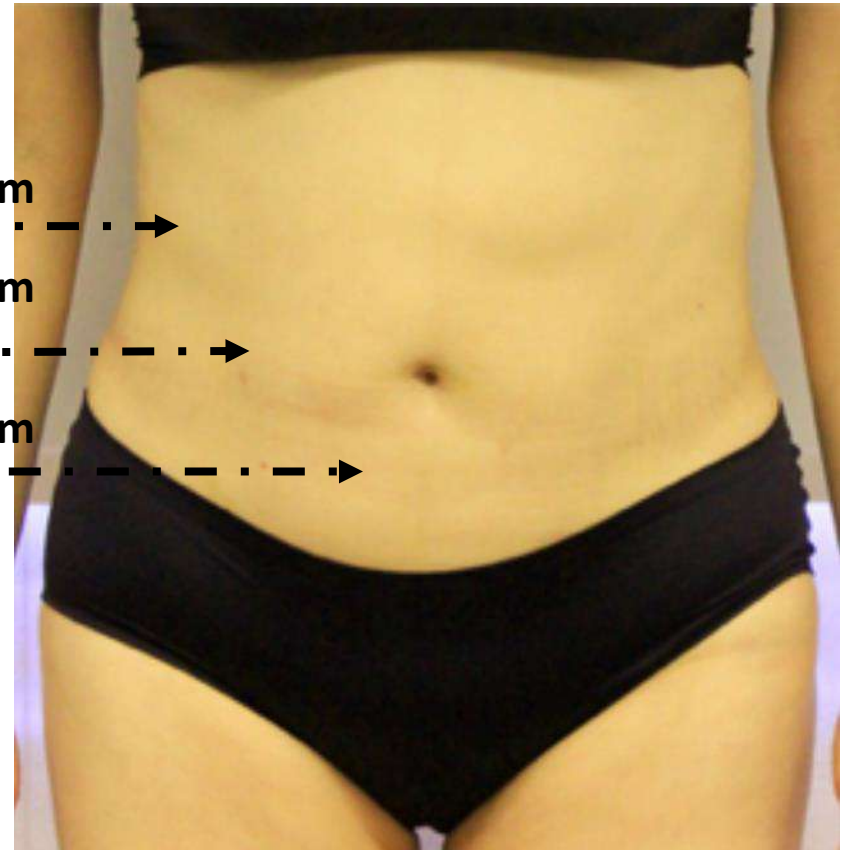
6 V-FORM



- 1.1 cm

- 2.2 cm

- 0.9 cm



Before

After



# 2.2 cm Abdomen Circumferential Reduction

**Case Study – VF#056-C**

**Dr. James K. M. Chan, Hong Kong**

**Patient**

Female, 50 years old (Fitzpatrick IV, BMI 22)

**Number of Treatments**

**6 V-FORM**

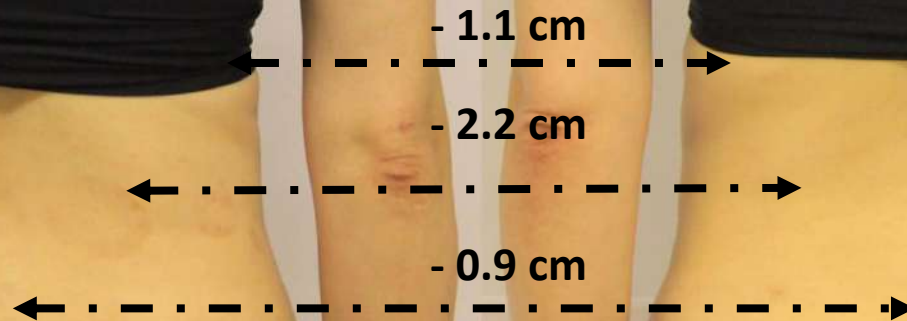

Photo courtesy: Dr. James Chan Ka Ming (HK)

**Before**

**After**



# Abdomen Circumferential Reduction

**Case Study – VF#058-A**

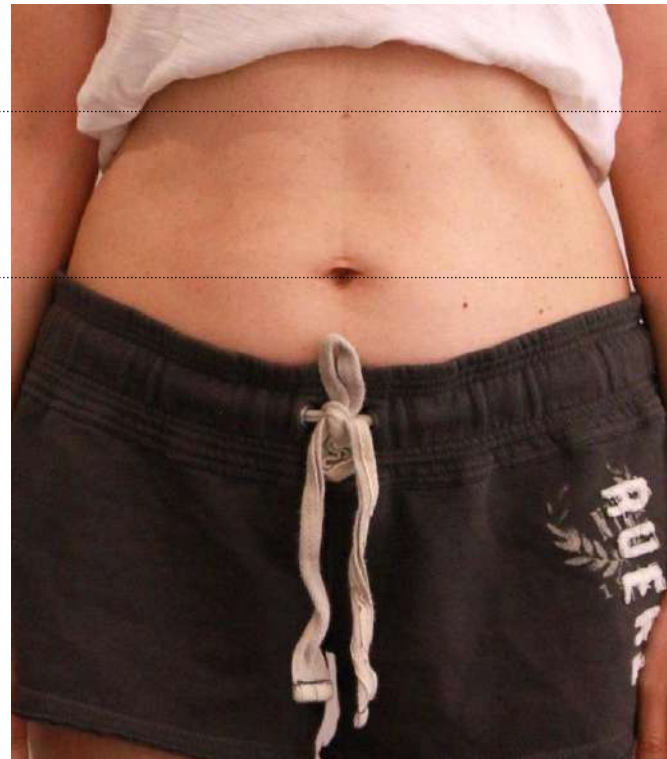
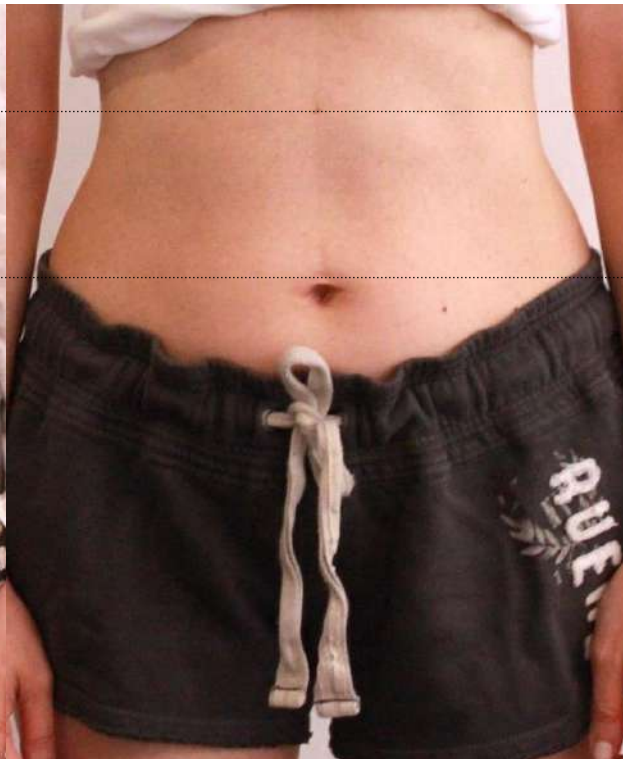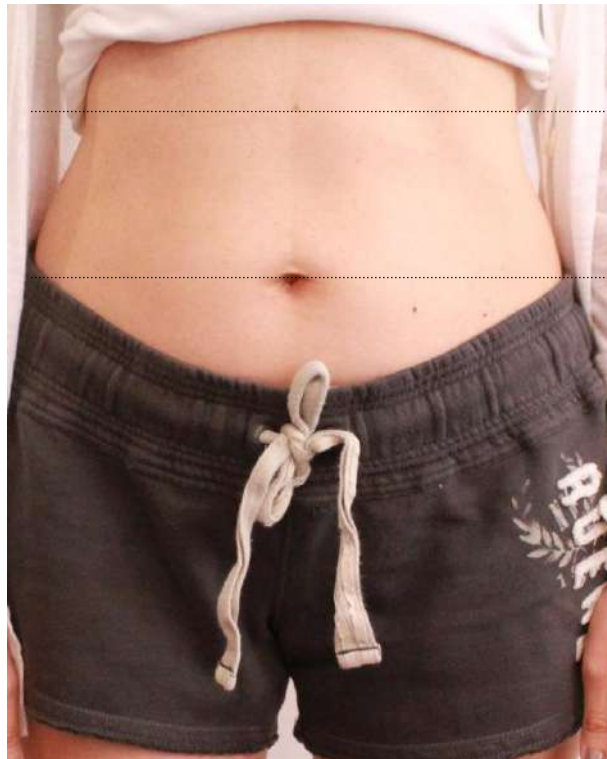**Dr. James K. M. Chan, Hong Kong**

**Patient**

Female, 40 years old

**Number of Treatments**

**8 V-FORM (BC Medium)**



**Before**

**After 6 Tx**

**After 8 Tx**



# Abdomen Circumferential Reduction

**Case Study – VF#058-B**

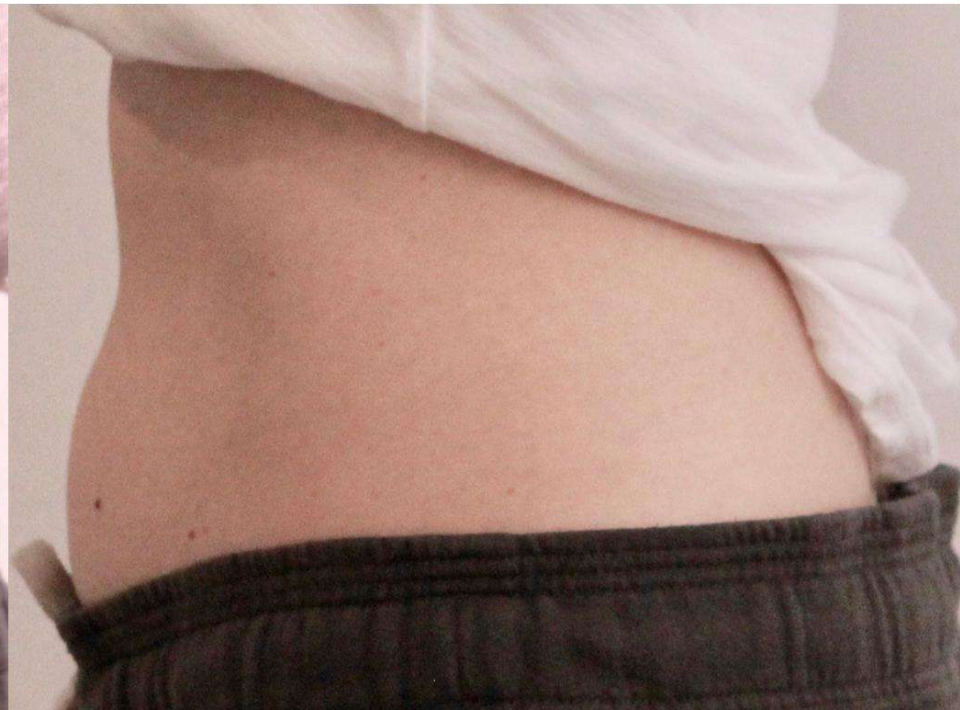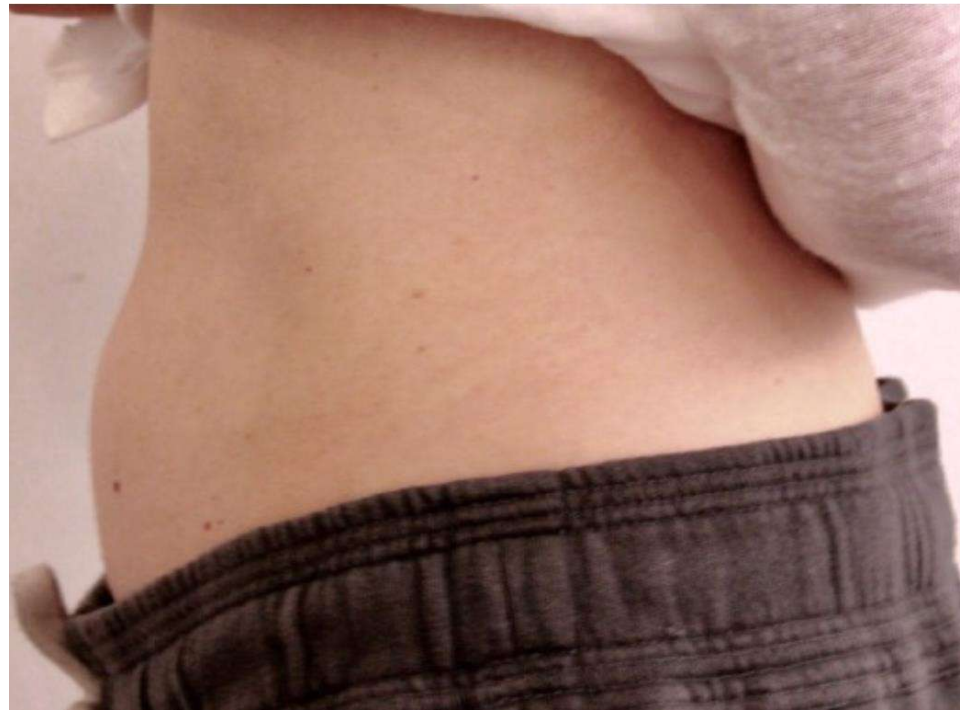**Dr. James K. M. Chan, Hong Kong**

**Patient**

Female, 40 years old

**Number of Treatments**

**6 V-FORM (BC Medium)**



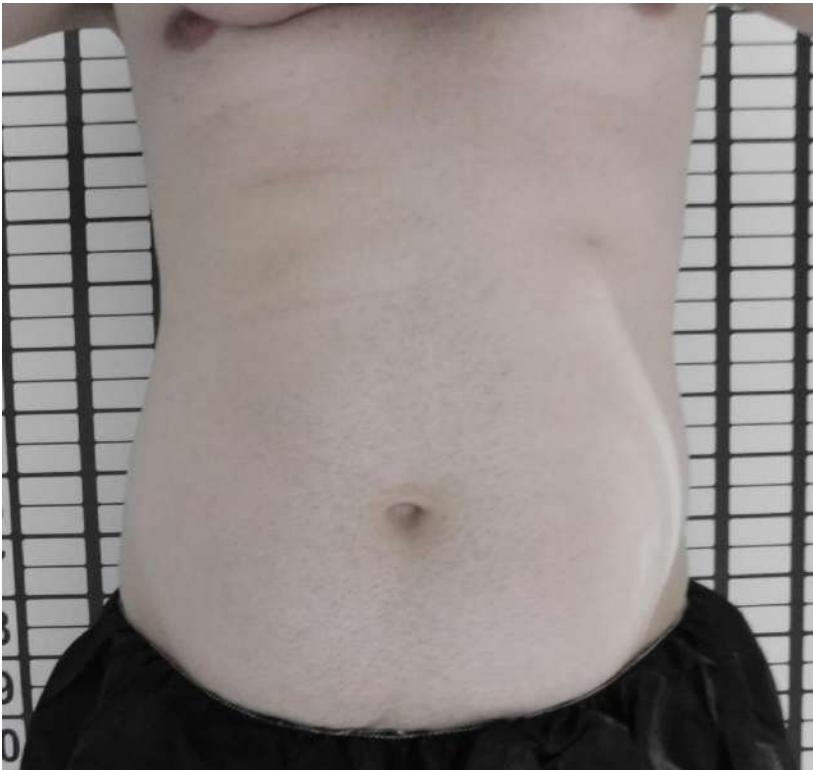**Before**

**After**

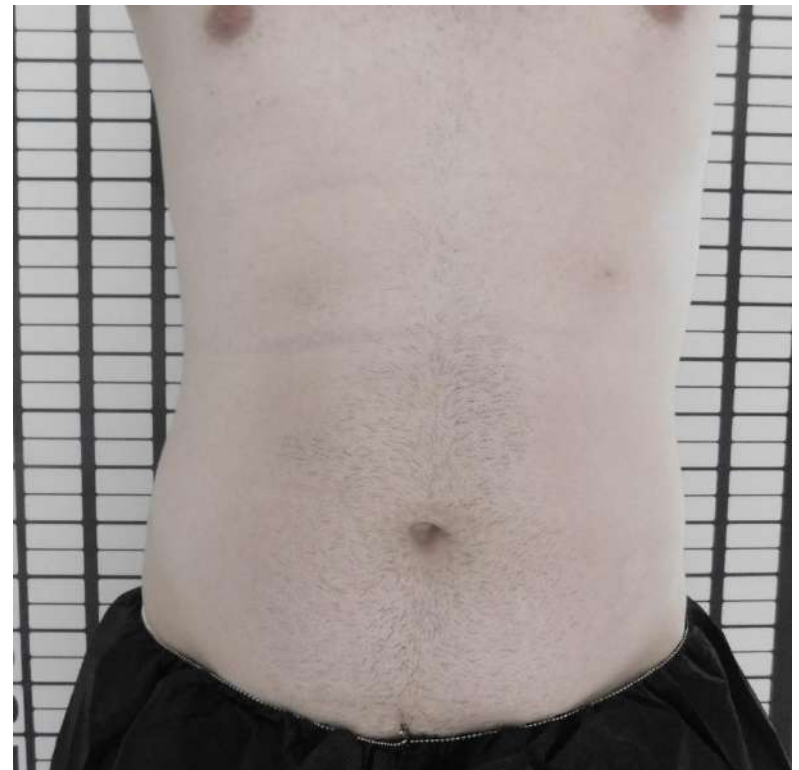

# Abdomen Contouring

<b>Case Study – VF#061</b>	<b>Dr Patricia Rittes, Sao Paulo, Brazil</b>
Patient	Male, 28 years old
Number of Treatments	<b>10 V-FORM (BC Medium)</b>



Before



After





**Arms**

  
**V I O R A**



# 4 cm Circumferential Reduction

**Case Study – VF#020-A**

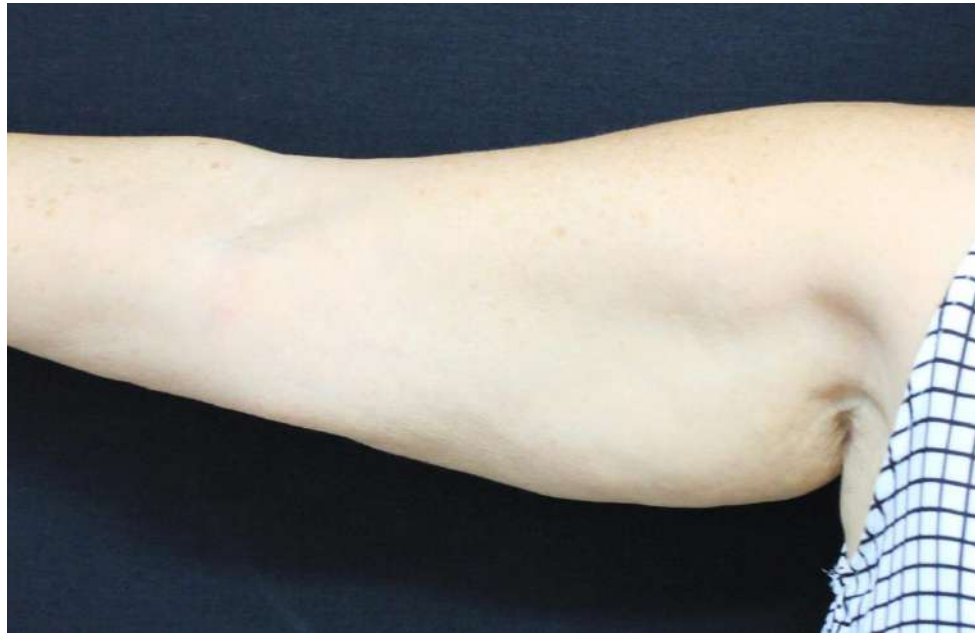**Dr. Inna Belenky, Viora Ltd.**

**Patient**

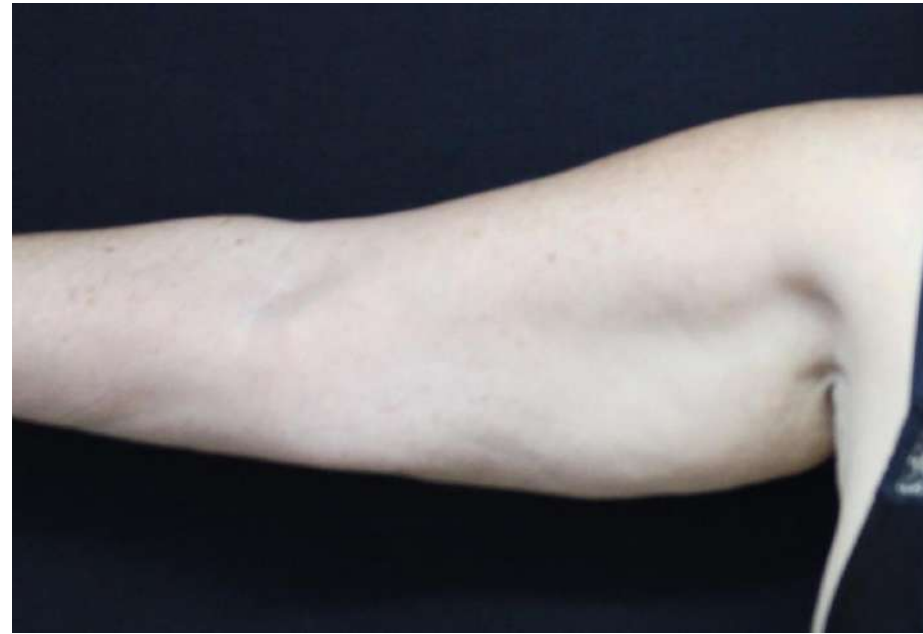Female, 70 years old (BMI 31)

**Number of Treatments**

**8 V-FORM**



**Before**



**4 weeks After**



# 1 cm Circumferential Reduction

**Case Study – VF#020-B**

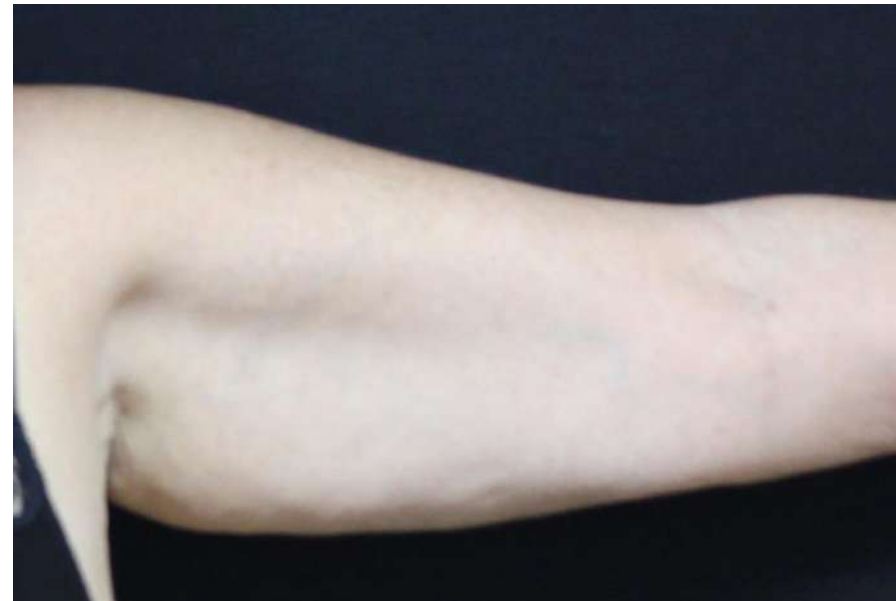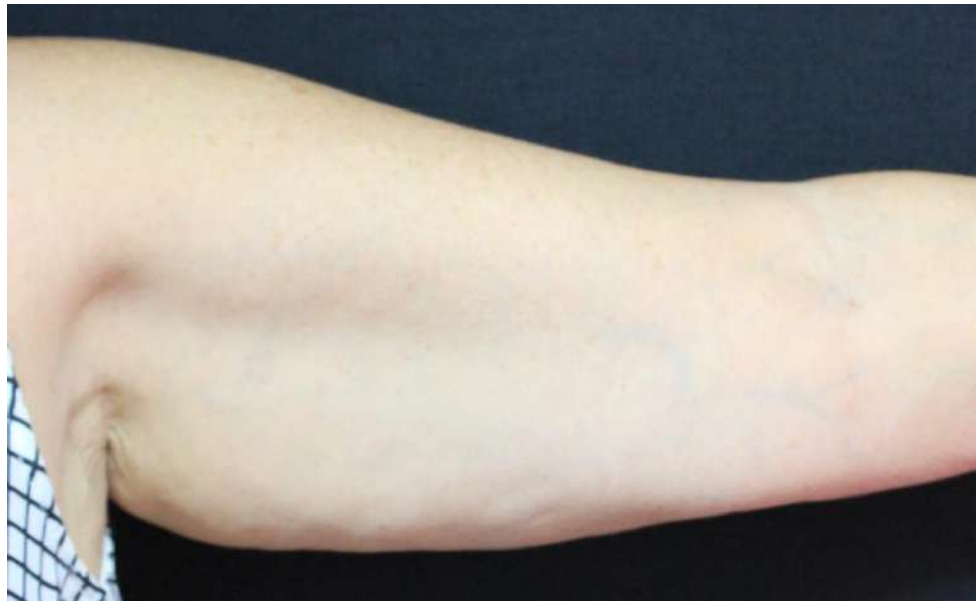**Dr. Inna Belenky, Viora Ltd.**

**Patient**

Female, 70 years old (BMI 31)

**Number of Treatments**

**8 V-FORM**



**Before**

**4 weeks After**



**Cellulite**

  
VIORA



# 2.5 cm Circumferential Reduction & Cellulite

**Case Study – VF#024**

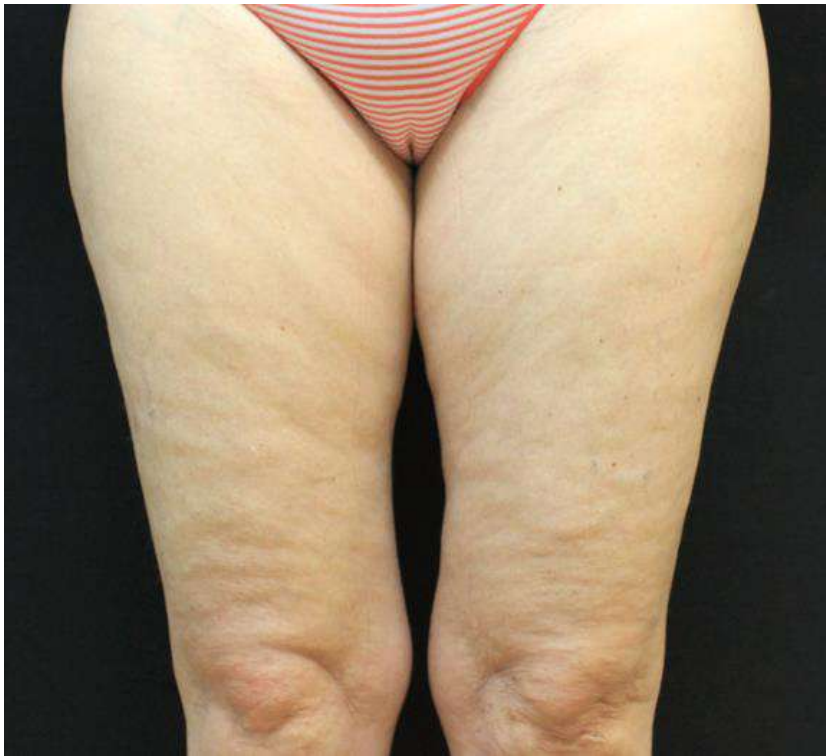**Dr. Cruzy Tagger, Viora Ltd.**

Patient

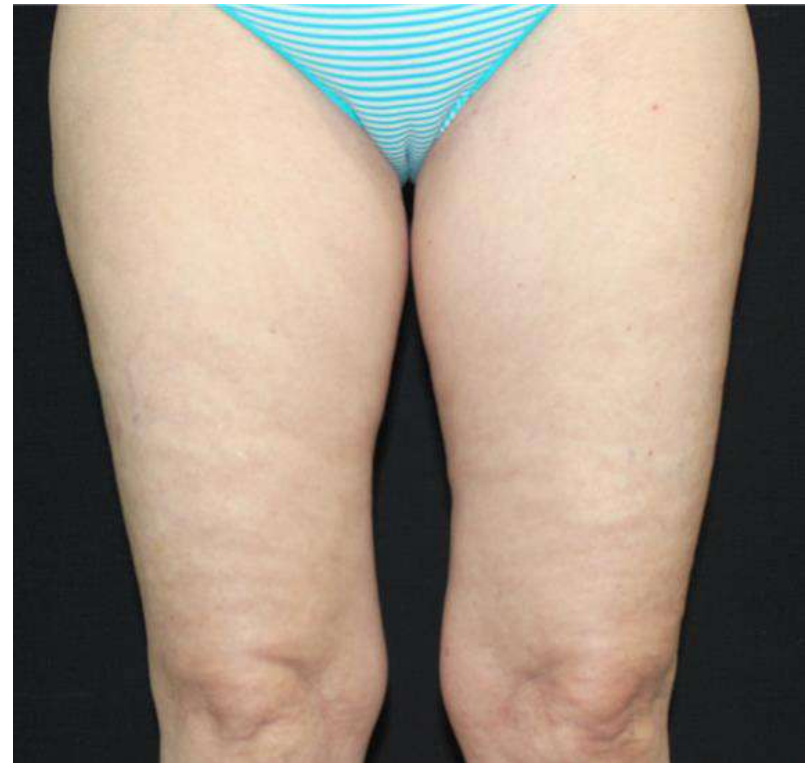Female, 57 years old (BMI 23)

**Number of Treatments**

**3 V-FORM**



**Before**



**After**



# Cellulite

**Case Study – VF#027-A**

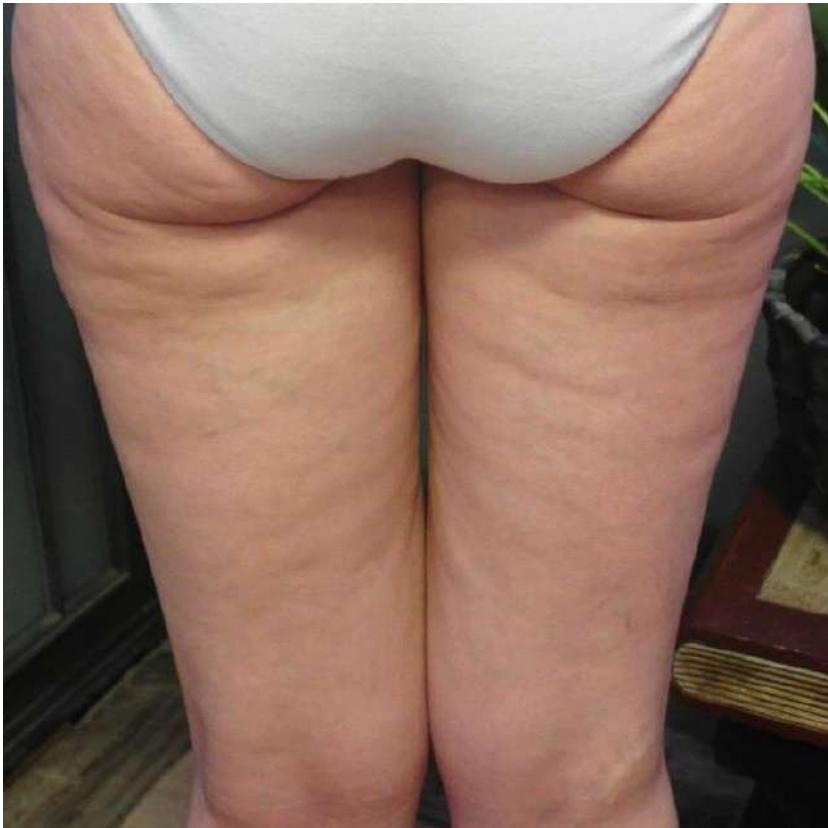**Ronit Sade, Israel**

Patient

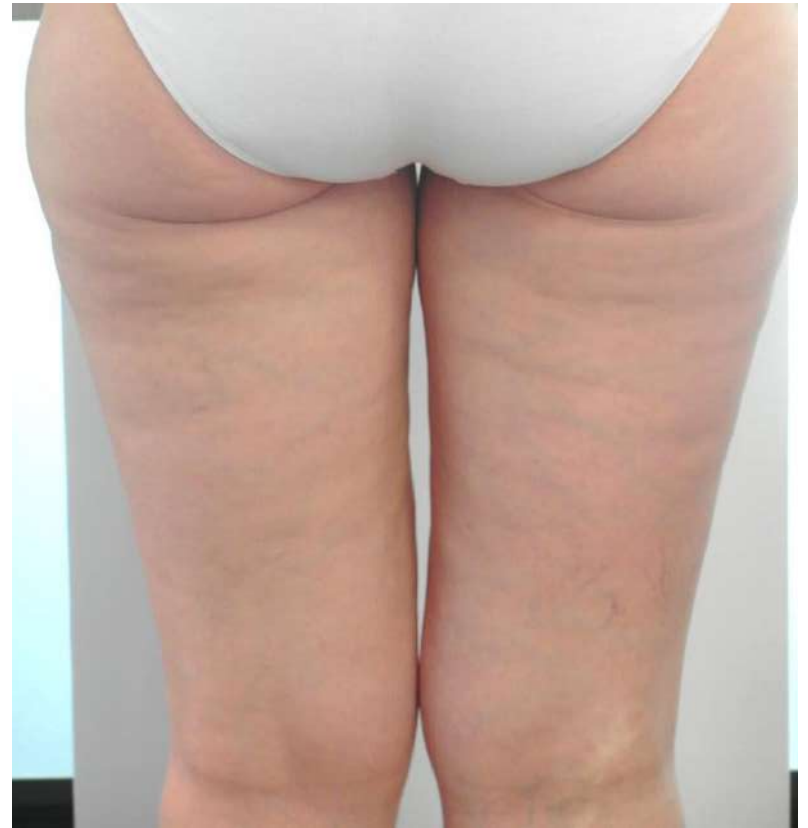Female

**Number of Treatments**

**3 V-FORM**



**Before**



**After**



# Cellulite

**Case Study – VF#027-B**

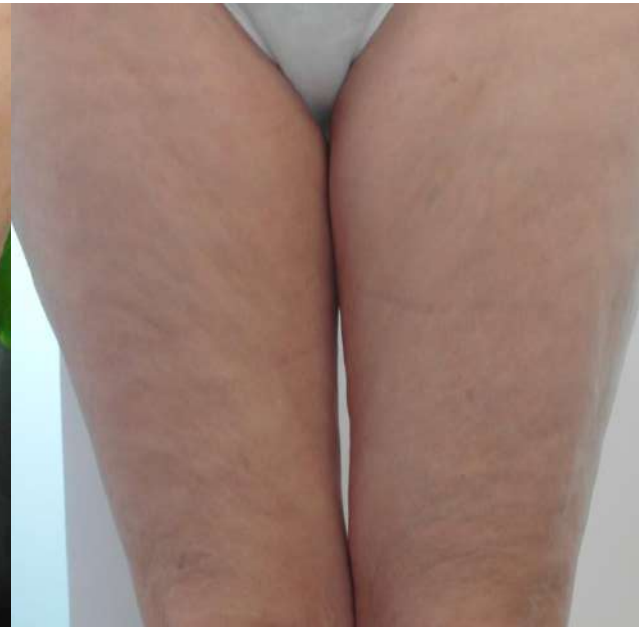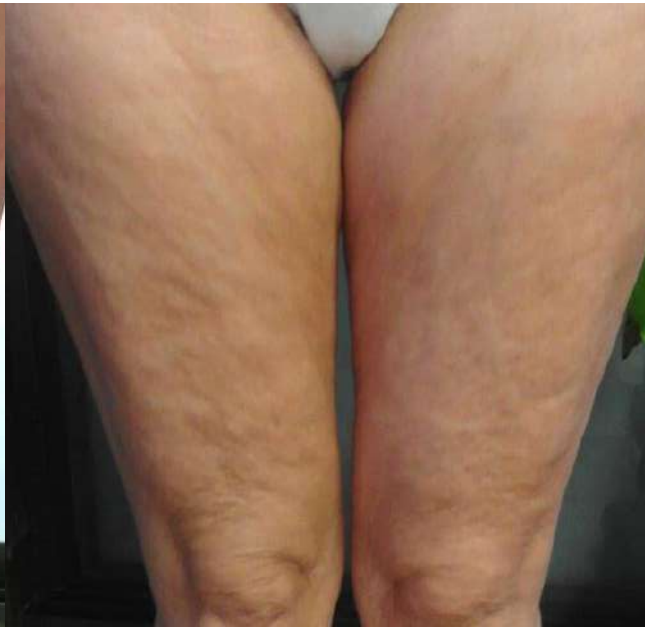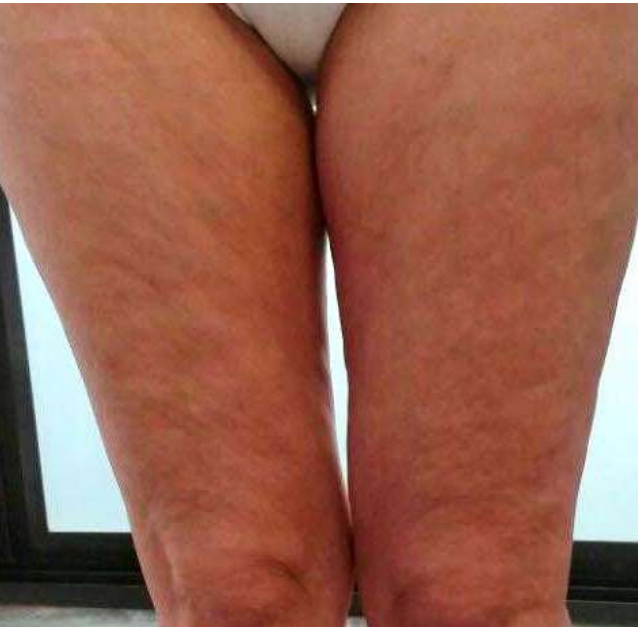**Ronit Sade, Israel**

Patient

Female

**Number of Treatments**

**3 V-FORM**



**Before**

**After 1 Treatment**

**After 3 Treatments**



# Cellulite

**Case Study – VF#027-C**

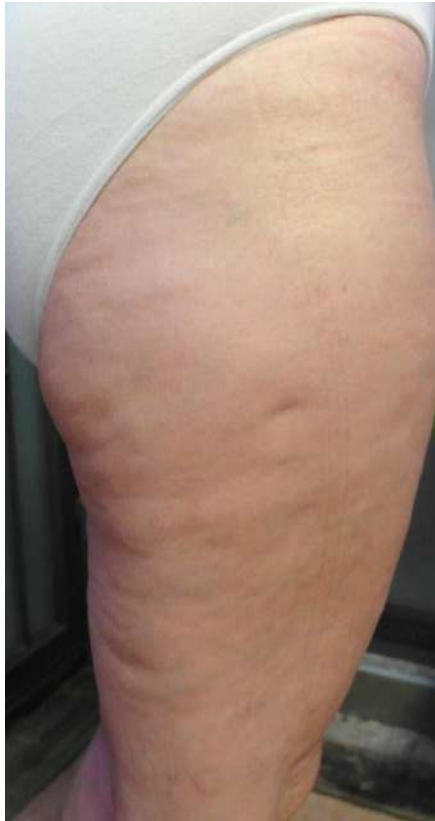**Ronit Sade, Israel**

Patient

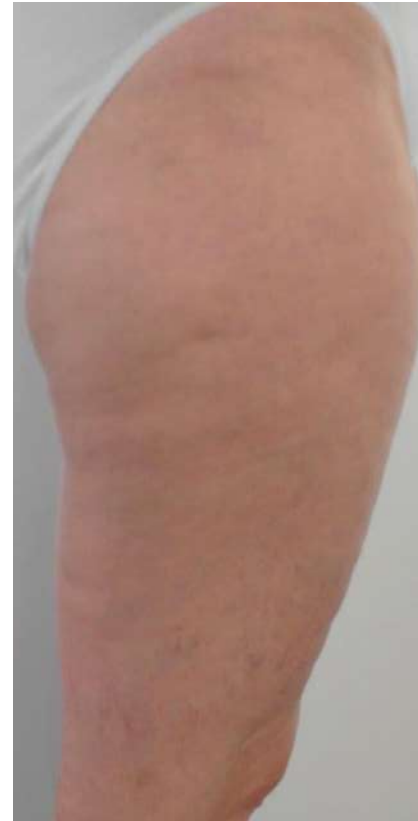Female

**Number of Treatments**

**3 V-FORM**



**Before**



**After**





# 2 cm Circumferential & Cellulite Reduction

**Case Study – VF#037-A**

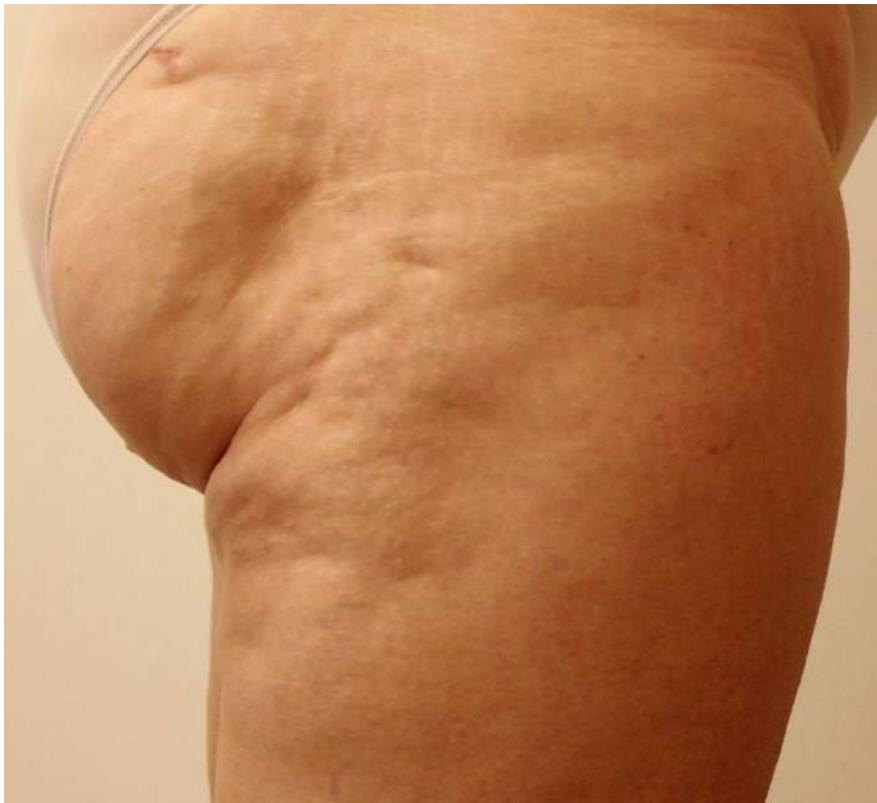**Dr. Cruzy Tagger, Viora Ltd.**

**Patient**

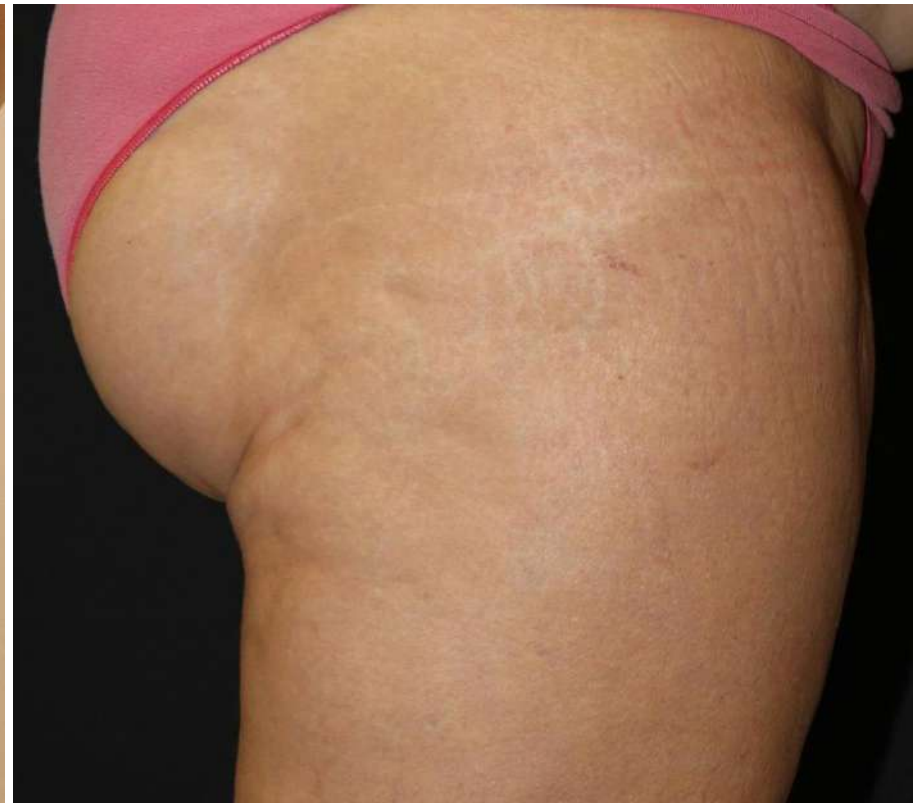Female, 52 years old (BMI 29)

**Number of Treatments**

**2 V-FORM**



**Before**



**2 weeks after 2 treatments**



# 1.5 cm Circumferential & Cellulite Reduction

**Case Study – VF#037-B**

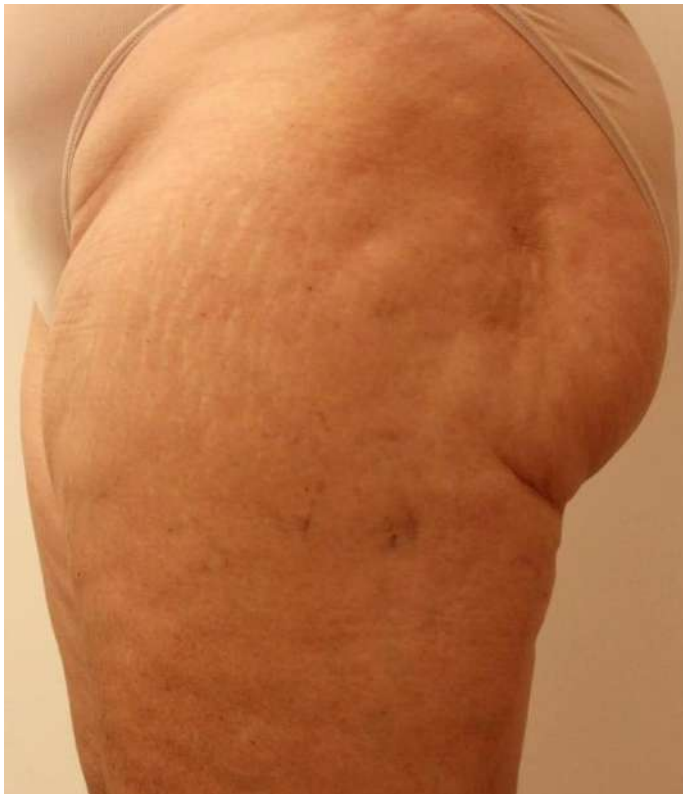**Dr. Cruzy Tagger, Viora Ltd.**

**Patient**

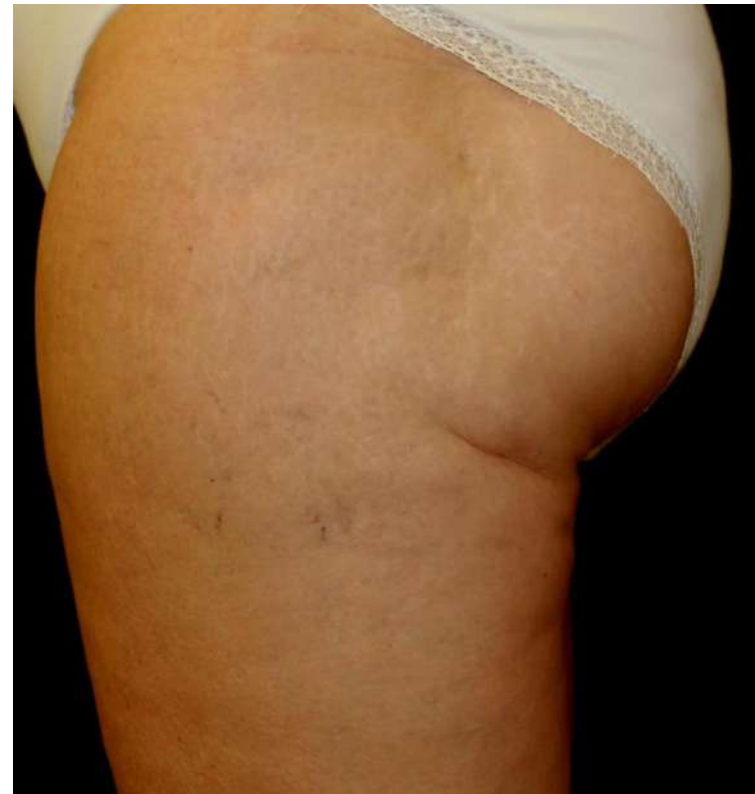Female, 52 years old (BMI 29)

**Number of Treatments**

**4 V-FORM**



**Before**



**2 weeks after 4 treatments**



# 2 cm Circumferential Reduction & Cellulite

**Case Study – VF#043**

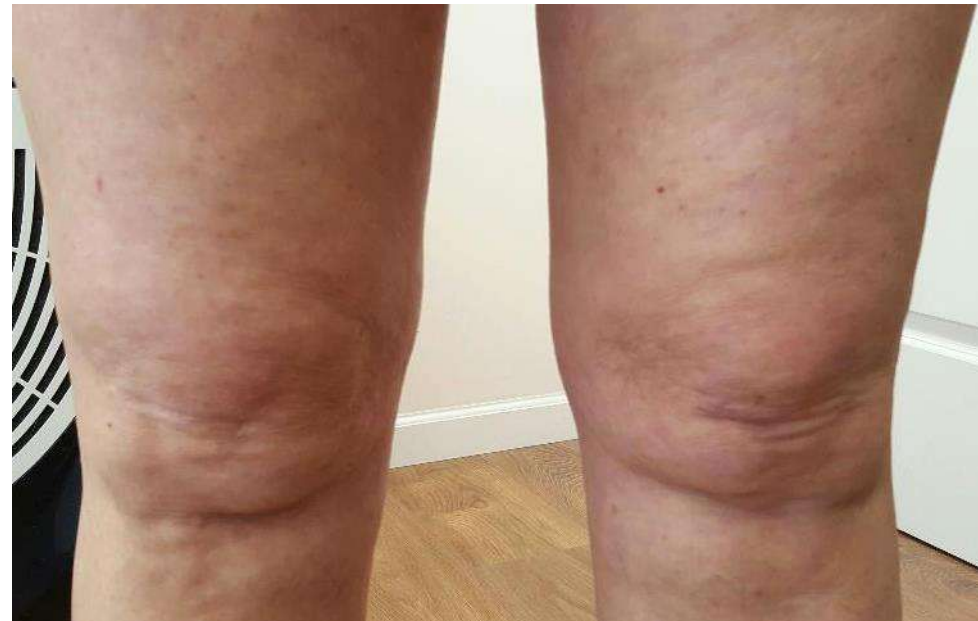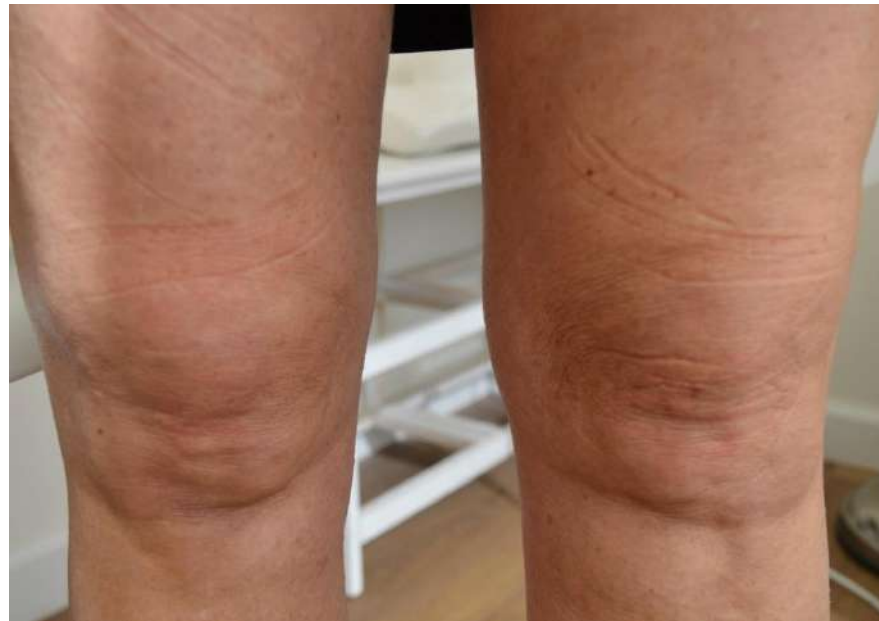**Dr. Lehavit Akerman, Herzeliya, Israel**

Patient

Female, 54 years old

**Number of Treatments**

**4 V-FORM**



**Before**

**After**



# 2.1 cm Circumferential Reduction & Cellulite

**Case Study – VF#044-A**

**Dr. Lehavit Akerman, Herzeliya, Israel**

**Patient**

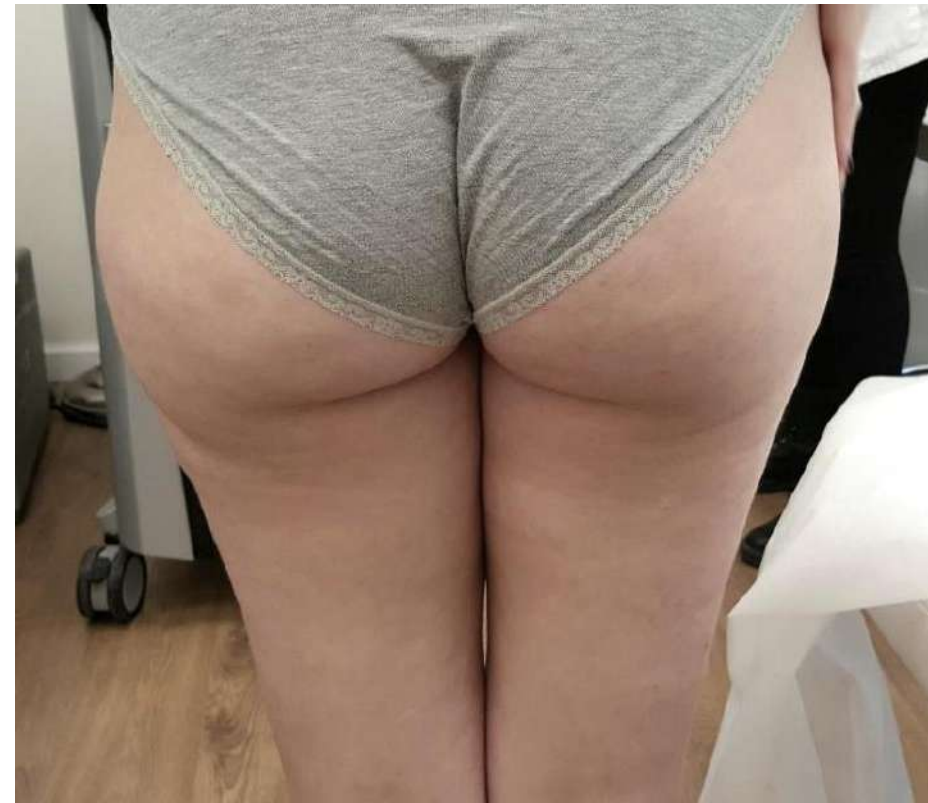Female, 20 years old

**Number of Treatments**

**4 V-FORM**



**Before**



**After**



# 2.1 cm Circumferential Reduction & Cellulite

**Case Study – VF#044-B**

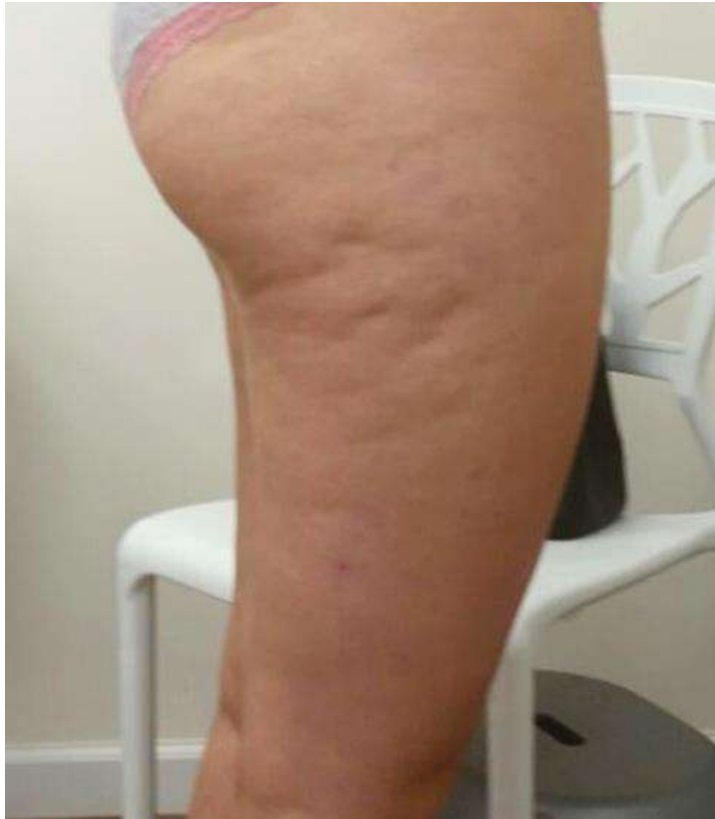**Dr. Lehavit Akerman, Herzeliya, Israel**

Patient

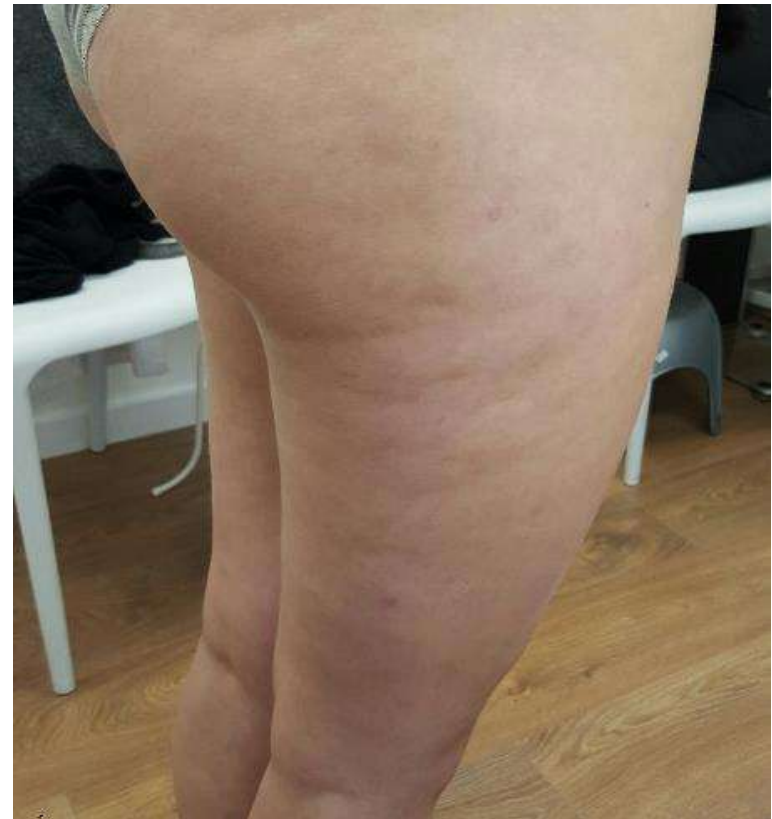Female, 20 years old

**Number of Treatments**

**4 V-FORM**



**Before**



**After**



# 2.6 cm Circumferential Reduction & Cellulite

**Case Study – VF#045**

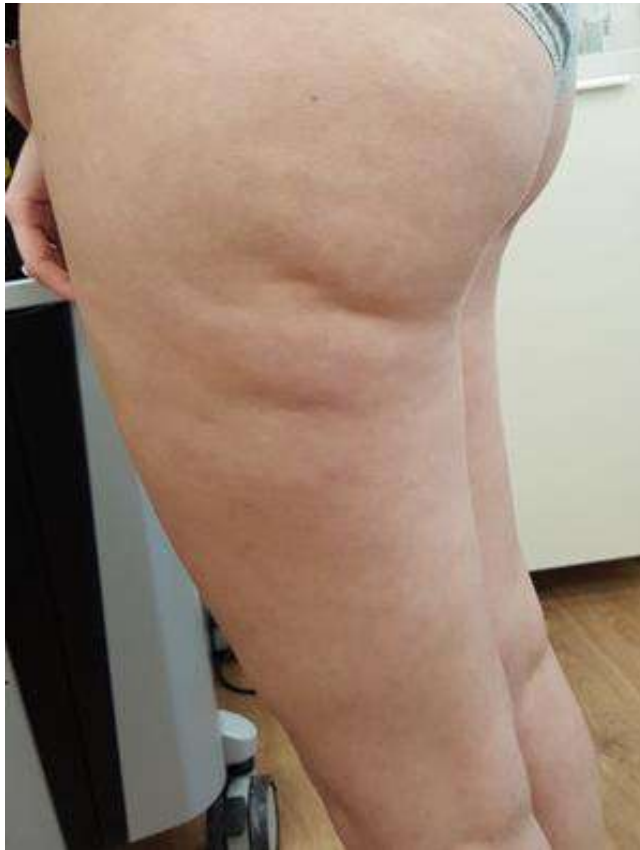**Dr. Lehavit Akerman, Herzeliya, Israel**

Patient

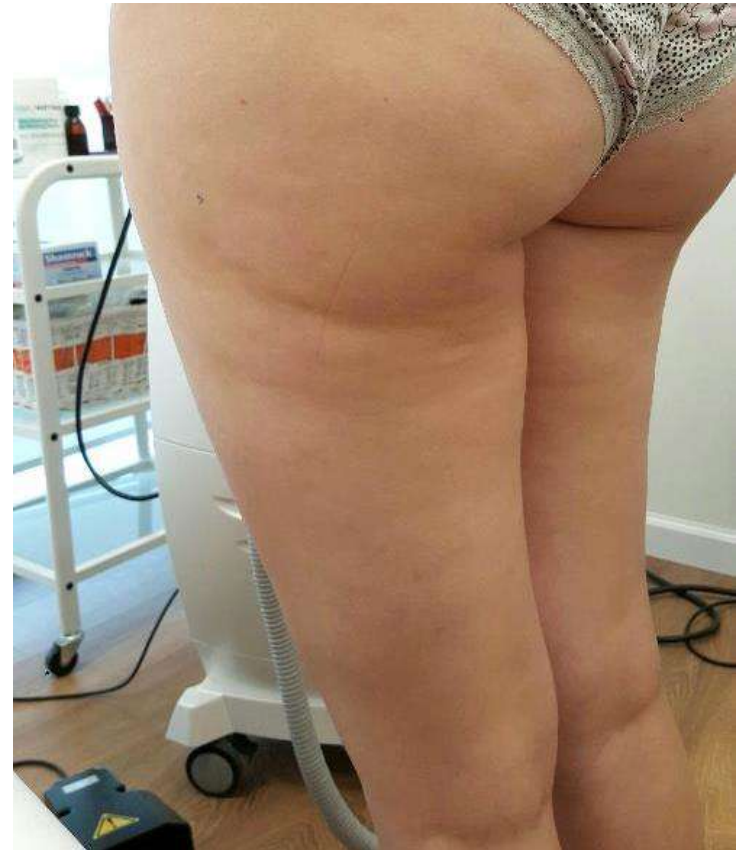Female, 43 years old

**Number of Treatments**

**5 V-FORM**



**Before**



**After**



# 2 cm Circumferential & Cellulite Reduction

**Case Study – VF#046**

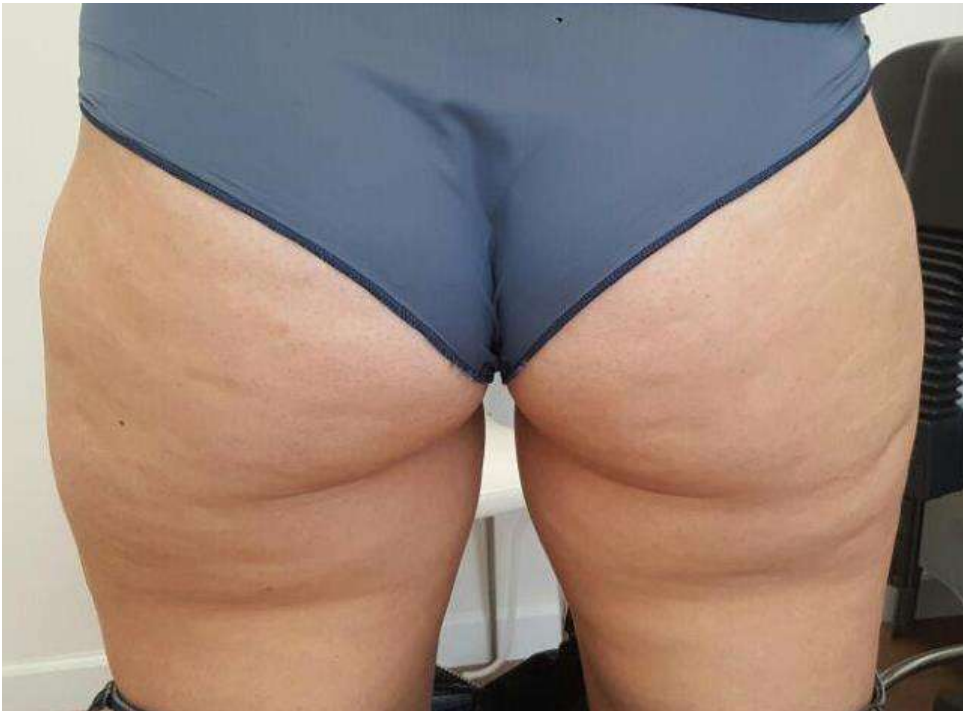**Dr. Lehavit Akerman, Herzeliya, Israel**

Patient

Female, 37 years old

**Number of Treatments**

**4 V-FORM**



**Before**

**After**



# 2.2 cm Thighs Circumferential Reduction

**Case Study – VF#057**

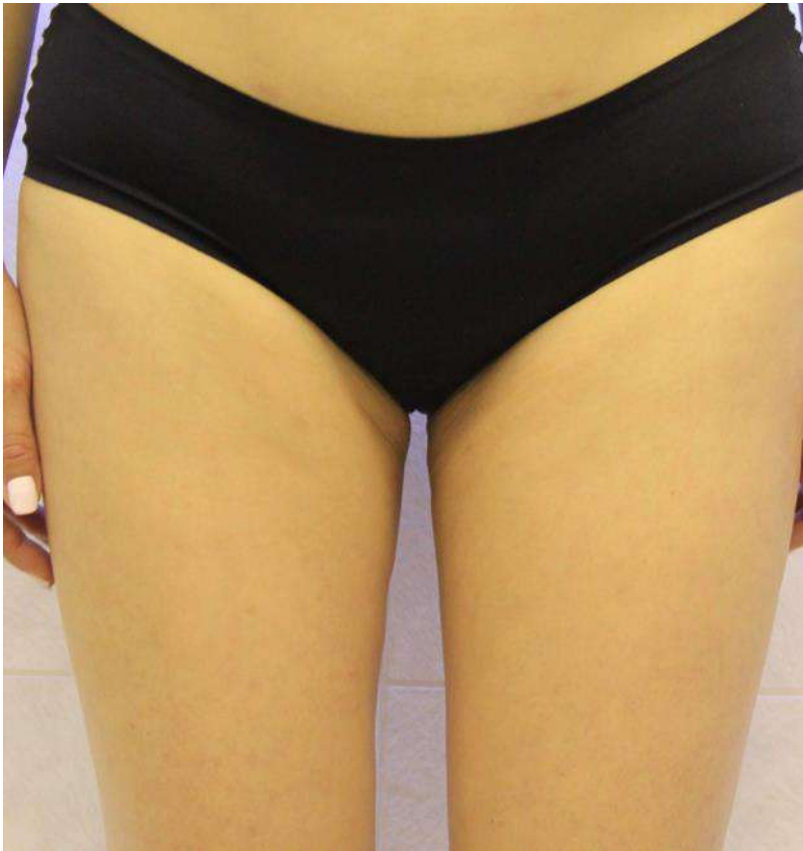**Dr. James K. M. Chan, Hong Kong**

**Patient**

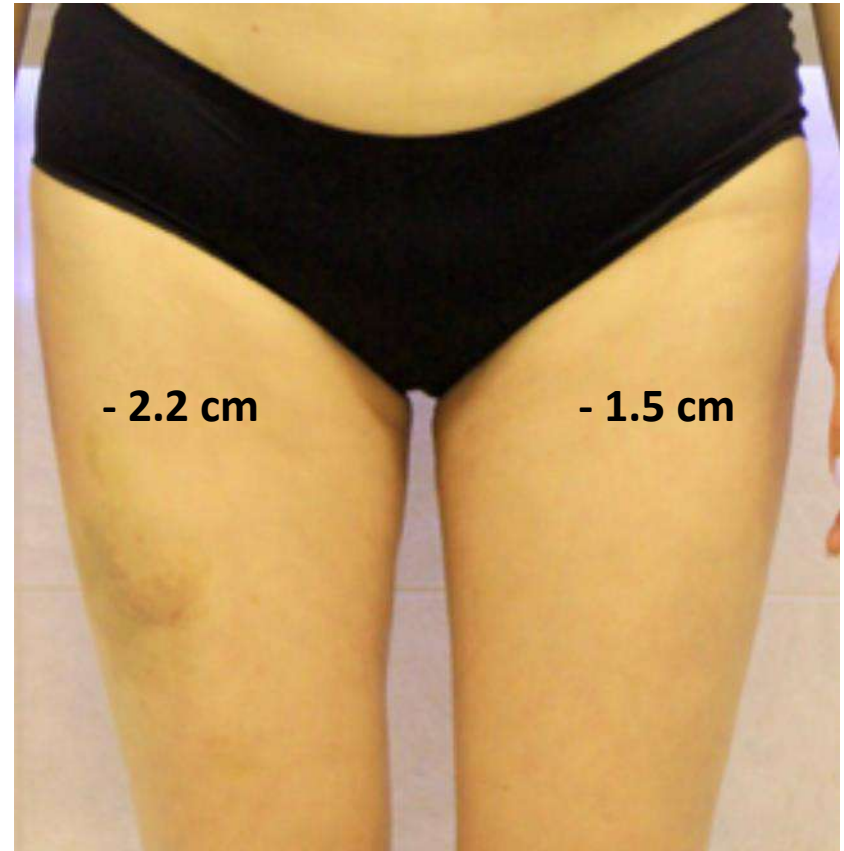
Female, 50 years old (Fitzpatrick IV, BMI 22)

**Number of Treatments**

**6 V-FORM**



**Before**



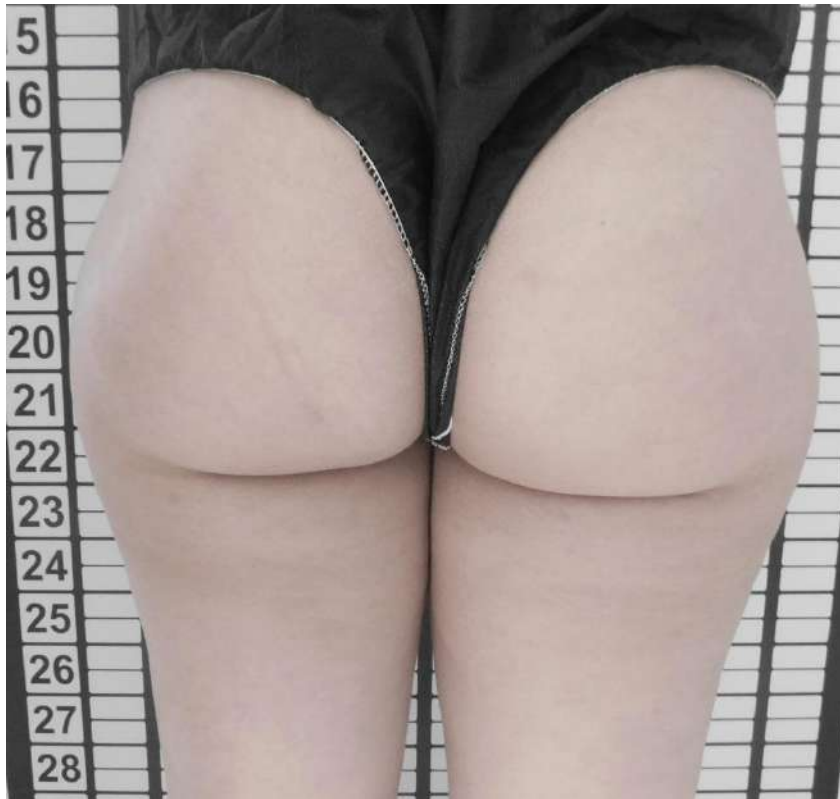**After**





# Buttocks Contouring and Lifting

<b>Case Study – VF#060</b>	<b>Dr Patricia Rittes, Sao Paulo, Brazil</b>
Patient	Female, 22 years old
Number of Treatments	<b>15 V-FORM (BC Medium)</b>



Before



After



# Thank You!

Questions? Comments?

